



## **Successful treatment of sclerosing encapsulating peritonitis in a cat using bioresorbable hyaluronate-carboxymethylcellulose membrane after surgical adhesiolysis and long-term prednisolone**

Authors: Yokoyama, Nozomu, Kinoshita, Ryohei, Ohta, Hiroshi, Okada, Kazuki, Shimbo, Genya, et al.

Source: Journal of Feline Medicine and Surgery Open Reports, 9(2)

Published By: SAGE Publishing

URL: <https://doi.org/10.1177/20551169231209917>

---

BioOne Complete ([complete.BioOne.org](https://complete.BioOne.org)) is a full-text database of 200 subscribed and open-access titles in the biological, ecological, and environmental sciences published by nonprofit societies, associations, museums, institutions, and presses.

Your use of this PDF, the BioOne Complete website, and all posted and associated content indicates your acceptance of BioOne's Terms of Use, available at [www.bioone.org/terms-of-use](https://www.bioone.org/terms-of-use).

Usage of BioOne Complete content is strictly limited to personal, educational, and non - commercial use. Commercial inquiries or rights and permissions requests should be directed to the individual publisher as copyright holder.

---

BioOne sees sustainable scholarly publishing as an inherently collaborative enterprise connecting authors, nonprofit publishers, academic institutions, research libraries, and research funders in the common goal of maximizing access to critical research.



# Successful treatment of sclerosing encapsulating peritonitis in a cat using bioresorbable hyaluronate-carboxymethylcellulose membrane after surgical adhesiolysis and long-term prednisolone

*Journal of Feline Medicine and Surgery Open Reports*  
1–7

© The Author(s) 2023

Article reuse guidelines:

sagepub.com/journals-permissions

DOI: 10.1177/20551169231209917

journals.sagepub.com/home/jfmsopenreports

This paper was handled and processed by the European Editorial Office (ISFM) for publication in *JFMS Open Reports*



Nozomu Yokoyama<sup>1</sup> , Ryohei Kinoshita<sup>2</sup>, Hiroshi Ohta<sup>3</sup>, Kazuki Okada<sup>4</sup>, Genya Shimbo<sup>2</sup>, Kazuyoshi Sasaoka<sup>2</sup> , Noriyuki Nagata<sup>2</sup>, Noboru Sasaki<sup>2</sup>, Keitaro Morishita<sup>2</sup>, Kensuke Nakamura<sup>1</sup>, Yumiko Kagawa<sup>4</sup> and Mitsuyoshi Takiguchi<sup>1</sup>

## Abstract

**Case summary** An 8-year-old neutered male domestic shorthair indoor cat was presented with an 8-week history of intermittent vomiting, anorexia and weight loss that had been unresponsive to supportive treatment. Abdominal ultrasound revealed plication of the small intestine and fluid accumulation proximal to the lesion, and a linear foreign body was suspected. An exploratory celiotomy showed cocoon-like encapsulation of the entire intestine. Surgical adhesiolysis and full-thickness biopsy were performed, and histopathologic examination revealed mild thickening of the visceral peritoneum with fibrin deposition, as well as mild neutrophil and lymphocyte infiltration. These findings were compatible with sclerosing encapsulating peritonitis (SEP). The cat recovered well postoperatively and was discharged the next day. Prednisolone was administered for 7 weeks to prevent recurrence of SEP. Five months after surgery, the cat was re-presented with anorexia and chronic vomiting. Based on the clinical examination findings, recurrent SEP was suspected. At the second surgery, surgical adhesiolysis was repeated and a bioresorbable hyaluronate-carboxymethylcellulose membrane was used to cover the serosal surface and thus prevent adhesion formation. Histopathologic findings of the peritoneal biopsy specimen confirmed SEP. Long-term prednisolone treatment (1 mg/kg for the first dose and 0.5 mg/kg every 48 h for maintenance) was administered postoperatively. The cat survived for more than 1239 days without recurrence.

**Relevance and novel information** To our knowledge, this is the first report of SEP in a cat with long-term survival. The use of a bioresorbable hyaluronate-carboxymethylcellulose membrane and long-term prednisolone treatment may have prevented short-term and long-term recurrence, respectively, in this case.

**Keywords:** Sclerosing encapsulating peritonitis; adhesive intestinal obstruction; bioresorbable hyaluronate-carboxymethylcellulose membrane; prednisolone

**Accepted:** 4 October 2023

<sup>1</sup>Laboratory of Veterinary Internal Medicine, Department of Veterinary Clinical Sciences, Graduate School of Veterinary Medicine, Hokkaido University, Sapporo, Japan

<sup>2</sup>Veterinary Teaching Hospital, Department of Veterinary Clinical Sciences, Graduate School of Veterinary Medicine, Hokkaido University, Sapporo, Japan

<sup>3</sup>Department of Companion Animal Clinical Sciences, School of Veterinary Medicine, Rakuno Gakuen University, Ebetsu, Japan

<sup>4</sup>North Lab, Sapporo, Japan

### Corresponding author:

Mitsuyoshi Takiguchi DVM, PhD, DAiCVIM (Internal Medicine), Laboratory of Veterinary Internal Medicine, Department of Veterinary Clinical Sciences, Graduate School of Veterinary Medicine, Hokkaido University, Kita 18, Nishi 9, Kita-ku, Sapporo, Hokkaido 060-0818, Japan  
Email: mtaki@vetmed.hokudai.ac.jp



Creative Commons Non Commercial CC BY-NC: This article is distributed under the terms of the Creative Commons

Attribution-NonCommercial 4.0 License (<https://creativecommons.org/licenses/by-nc/4.0/>) which permits non-commercial use, reproduction and distribution of the work without further permission provided the original work is attributed as specified on the SAGE and Open Access pages (<https://us.sagepub.com/en-us/nam/open-access-at-sage>).

Downloaded From: <https://bioone.org/journals/Journal-of-Feline-Medicine-and-Surgery-Open-Reports> on 08 Jan 2025

Terms of Use: <https://bioone.org/terms-of-use>

## Introduction

Sclerosing encapsulating peritonitis (SEP), also called encapsulating peritoneal sclerosis in human medicine, is a chronic form of peritonitis characterised by the irreversible formation of thick sheets of fibrous tissue on the mesothelial lining of abdominal organs.<sup>1</sup> In veterinary medicine, the underlying cause of SEP is multifactorial. Contributing factors include foreign body ingestion, fibreglass ingestion, bacterial peritonitis, pancreatitis, leishmaniasis and neoplasia (eg, hepatocellular carcinoma, pancreatic ductal adenocarcinoma); however, many cases are idiopathic.<sup>1–13</sup> Reported clinical signs are non-specific and include anorexia, intermittent vomiting, lethargy, peritoneal effusion, anorexia, diarrhoea and abdominal distension assumed to be caused by peritoneal inflammation and adhesive intestinal obstruction.<sup>1–13</sup> Imaging findings of SEP in dogs and cats include plicated and/or corrugated small bowel loops with echogenic localised peritoneal effusion on abdominal ultrasound and fat stranding on CT.<sup>8</sup> SEP is definitively diagnosed by the characteristic gross thickening of the peritoneum that encloses some or all the small intestine in a cocoon of opaque tissue intraoperatively and by the histopathologic findings of fibroconnective tissue and inflammatory infiltrates.<sup>1–13</sup> SEP is extremely rare in feline medicine; only seven cases have been reported.<sup>1,4,8,9</sup> Although treatment protocols for SEP in cats have not yet been established, surgical adhesiolysis alone to relieve an intestinal obstruction or in combination with medical treatment to prevent recurrence have been attempted. However, the prognosis of SEP is poor; six of the seven previously reported cats died or were euthanased within 2 months postoperatively because of complications or lack of clinical improvement, and the remaining cat survived for 11 months.<sup>1,4,8,9</sup> We herein report a cat with SEP in which long-term survival was achieved through surgical adhesiolysis and long-term prednisolone therapy.

## Case description

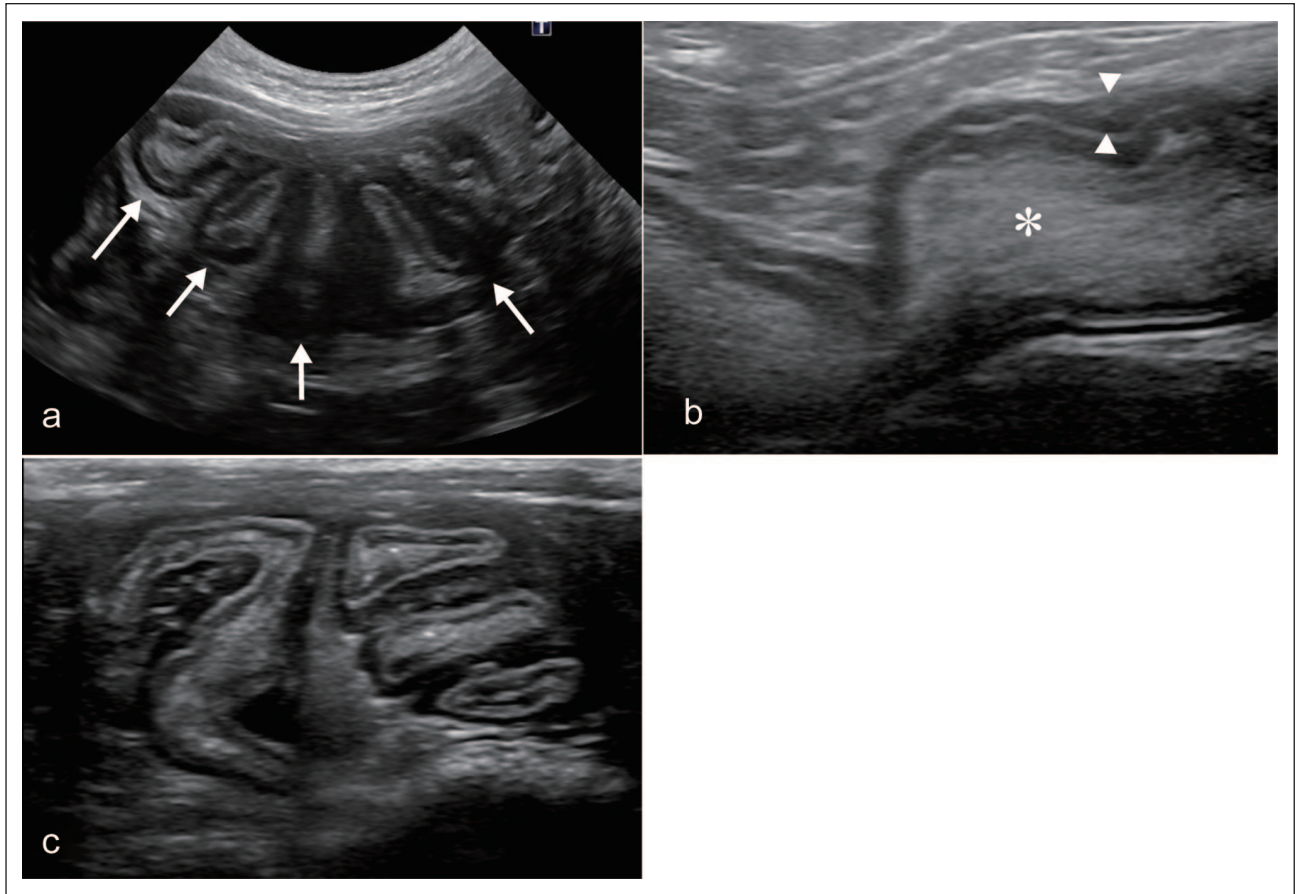
An 8-year-old neutered male domestic shorthair cat was referred to the Hokkaido University Veterinary Teaching Hospital for further investigation of an 8-week history of intermittent vomiting, anorexia and weight loss. At the time of presentation to our referral facility, the cat had received treatment with famotidine and subcutaneous fluid administration by the referring general practitioner. However, the vomiting had continued despite this treatment. The cat was indoors only and had not received vaccination or ectoparasite/endoparasite prophylaxis. Its feline immunodeficiency virus/feline leukaemia virus status was negative.

Upon physical examination at the first presentation (day 1), the cat weighed 4.50 kg with a body condition score of 5/9 and was mildly dehydrated. Blood

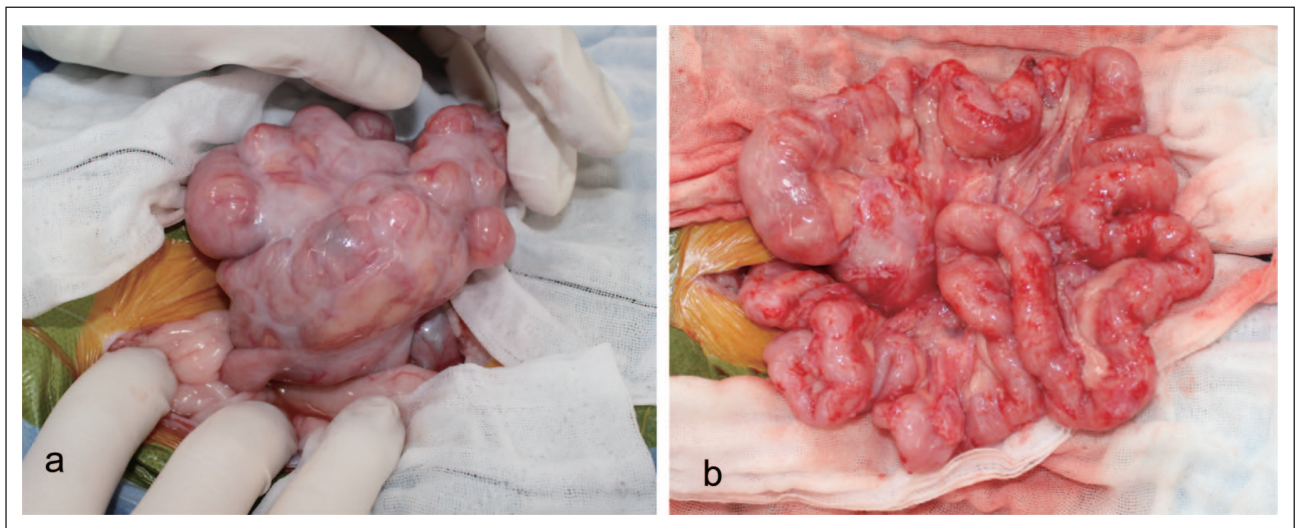
examination revealed mild non-regenerative anaemia (haematocrit 29.7%; reference interval [RI] 30.3–52.3). The biochemistry profile demonstrated mildly elevated creatinine (2.2 mg/dl; RI 0.9–2.1) and mildly decreased phosphate (2.2 mg/dl; RI 2.6–6.0). Abdominal radiographs revealed segmental intestinal dilation (23 mm in diameter) and a fluid- and gas-distended stomach, suggesting mechanical obstruction. Abdominal ultrasound revealed diffuse plication of the small intestine and fluid accumulation in the duodenum, but no hyperechoic linear structure was visualised at the centre of the intestinal lumen (Figure 1). Although a foreign body was not visible, the cat was considered to have complete small intestinal obstruction with a linear foreign body based on these imaging findings. To further investigate the ultrasonographic abnormalities, an exploratory celiotomy was performed.

Intraoperatively, several small intestinal loops were clustered and adhered to the serosal surface (Figure 2). The visceral peritoneum had a whitish and thickened appearance and covered the small intestine, making it poorly discernible. The cat had a mechanical intestinal obstruction between the ascending duodenum and jejunum, attributed to adhesion formation of unknown cause. Surgical adhesiolysis was performed with Metzenbaum scissors, and the intestinal obstruction was released. A linear foreign body was not identifiable within the lesion. After the adhesions were removed, a full-thickness jejunal biopsy was performed to determine the cause of the adhesions. Histological examination of the tissue showed slight thickening of the small intestinal visceral peritoneum characterised by fibrin deposition and mild neutrophil and lymphocyte infiltration. Based on these pathological and intraoperative findings, type 1 SEP (enclosing only the small intestine) was suspected. The cat recovered well postoperatively and was discharged the next day. Oral prednisolone was administered at 1 mg/kg q24h for 2 weeks to prevent recurrence of SEP, tapered by a 25% dose reduction every 1–2 weeks, and discontinued on day 52. The owner was instructed to regularly take the cat to the primary care hospital to check for recurrence of the clinical signs.

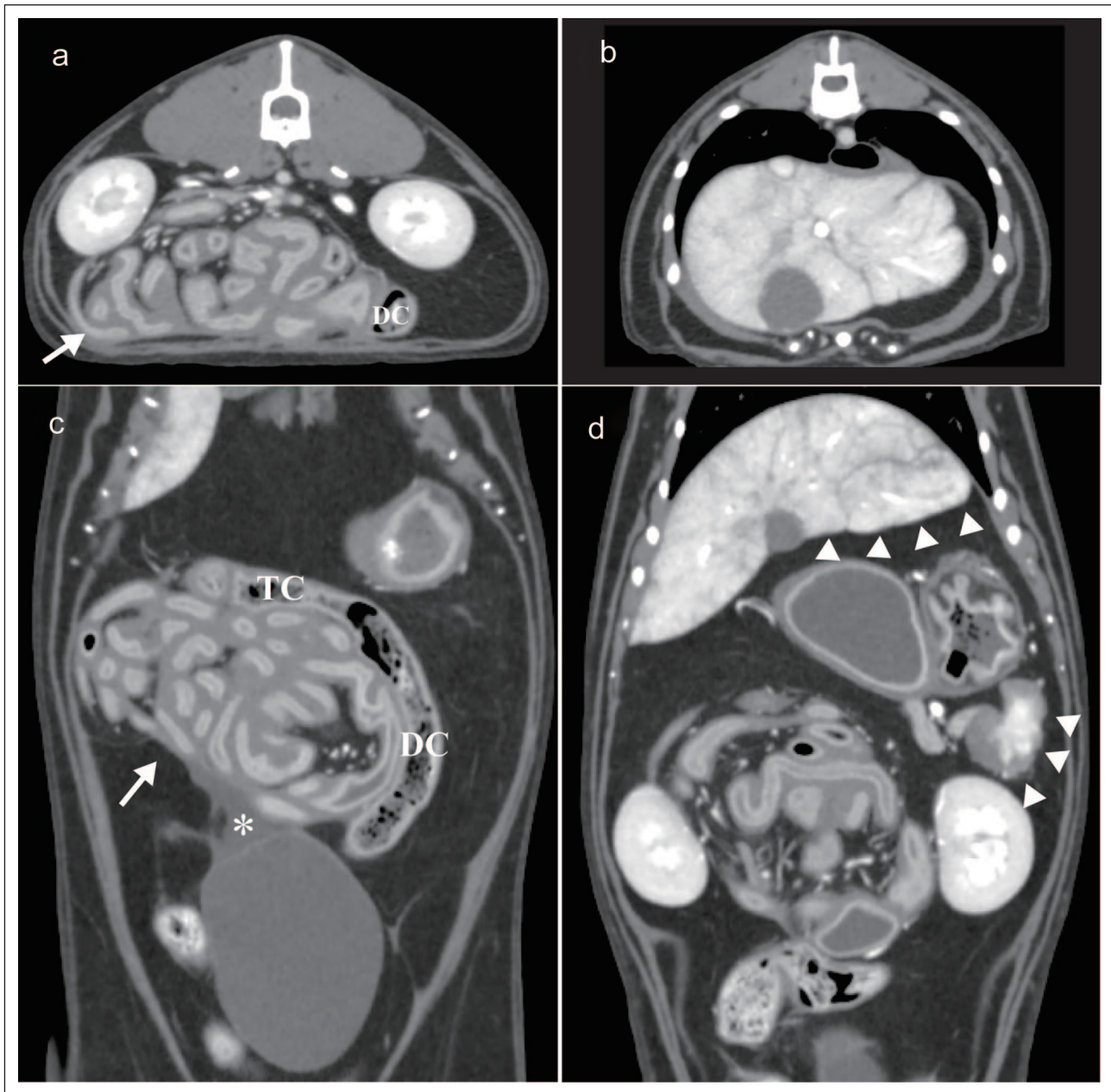
On day 165, the cat was re-presented to our hospital with a 1-month history of chronic vomiting and anorexia. Haematology and biochemistry revealed mild non-regenerative anaemia (haematocrit 27.3%; RI 30.3–52.3) and mildly decreased phosphate (2.3 mg/dl; RI 2.6–6.0), with no other abnormalities. Abdominal radiographs showed gastric distention with fluid and gas, as well as dilated, fluid-filled loops of small duodenum. Abdominal ultrasound revealed a fluid-dilated duodenum and a plicated small intestine. Abdominal CT (80-row Aquilion Prime; Canon Medical Systems) with triple-phase contrast and 0.5 mm slice thickness showed gathered intestinal loops, loculated abdominal fluid, and



**Figure 1** Ultrasonographic images of plication of the small intestine: (a) the white arrows indicate the plicated loop of the small intestine; (b) markedly distended small intestine proximal to the plicated loop. The white asterisk indicates fluid accumulation in the lumen, and the arrowheads indicate thickening of the muscular layer and (c) clumped bowel loops distal to the plicated loop



**Figure 2** Intraoperative photograph at first exploratory celiotomy (a) before and (b) immediately after surgical adhesiolysis: (a) a dense (cocoon-like) membrane encased the intestine and (b) haemorrhage from the serosa of the intestinal tract was observed after surgical adhesiolysis

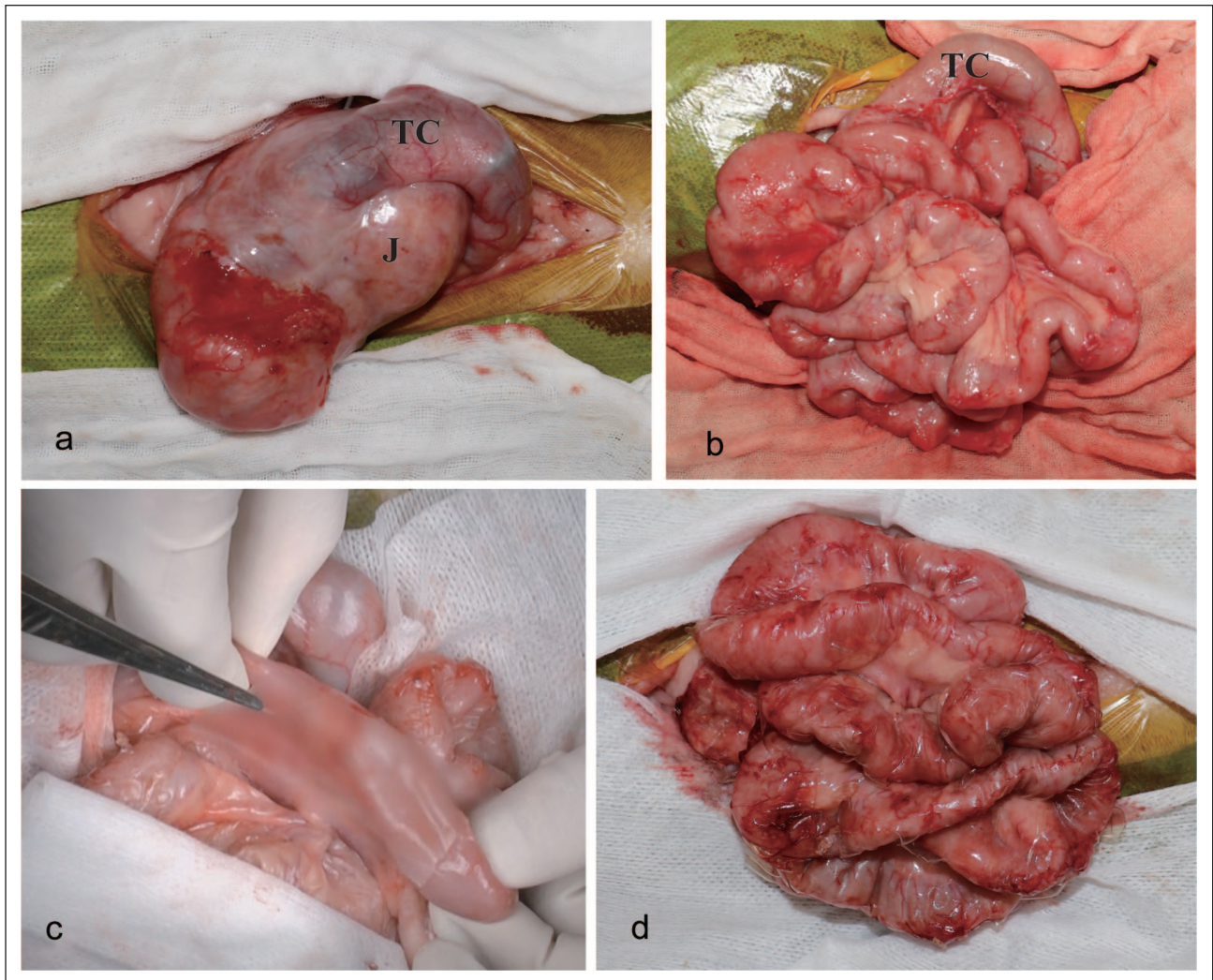


**Figure 3** Post-contrast (a,b) transverse and (c,d) dorsal CT reconstruction (0.5mm slice thickness) in the abdominal portal venous phase in the soft tissue window at the second presentation. (a,c) Intestinal loops (white arrow) were gathered with the TC and DC. The asterisk shows loculated abdominal fluid. (b,d) The white arrowheads indicate generalised blunting of the liver and spleen. DC = descending colon; TC = transverse colon

generalised blunting of the liver and spleen (Figure 3). Based on the clinical course and imaging findings, recurrent adhesive intestinal obstruction secondary to SEP was strongly suspected, and surgery was planned.

Intraoperative examination during the second surgery revealed cocoon-like encapsulation of the entire small intestine and adherence of the transverse colon to the lesion, which was more severe than during the first surgery (Figure 4). Surgical adhesiolysis was performed

using the same approach as in the first surgery. In addition, a bioresorbable hyaluronate-carboxymethylcellulose (HA-CMC) membrane (Seprafilm; Sanofi) was applied to completely cover the intestinal serosa and thus prevent adhesion formation. Histopathologic examination of peritoneal biopsy specimens obtained intraoperatively revealed densely packed collagen fibres with differentiated fibroblast cells and minimal lymphocyte infiltration (Figure 5). Finally, SEP was diagnosed.



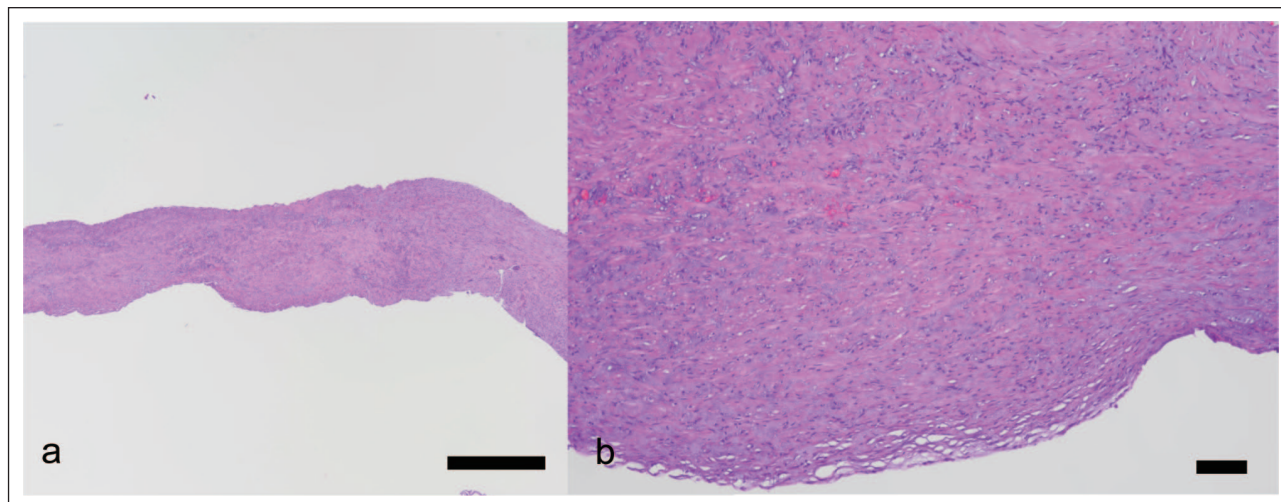
**Figure 4** Intraoperative images at second celiotomy: (a) markedly thick fibrous membrane encapsulating the J and TC; (b) photograph immediately after surgical adhesiolysis for the J and TC; (c) photograph depicting application of a half-sheet of hyaluronate-carboxymethylcellulose membrane to the site of surgical adhesiolysis in the J; and (d) photograph of the J and TC covered entirely with the hyaluronate-carboxymethylcellulose membrane. J = jejunum; TC = transverse colon

Postoperatively, the cat recovered well and was prescribed long-term oral prednisolone (restarting dose of 1 mg/kg q24h for 3 months) to prevent recurrence of SEP. Within the first year after the second surgery, the prednisolone dosage was tapered to 0.5 mg/kg q24h and then maintained at 0.5 mg/kg q24h in the long term. The cat was eating well and had gained approximately 1.6 kg of weight by day 816. On day 1239, at the time of the follow-up evaluation, the cat was eating, drinking, urinating and defecating normally, and no recurrence was detected.

## Discussion

SEP is a rare disease characterised by pro-fibrotic solid inflammation leading to activation, proliferation and

differentiation of fibroblasts into myofibroblasts with deposition of excessive extracellular matrix in the peritoneum.<sup>1-13</sup> SEP has an extremely poor prognosis in cats despite aggressive surgical and medical treatment, and no report has described a cat with SEP in remission.<sup>1,4,8,9</sup> Of the seven cats in which this condition has been reported to date, one was euthanased at surgery because of the inability to dissect the adhesion,<sup>9</sup> two died or were euthanased within 7 days because of complications or lack of clinical improvement postoperatively,<sup>8</sup> three survived for 3-57 days postoperatively<sup>4</sup> and the remaining cat was alive 11 months after diagnosis, but no further follow-up was reported.<sup>1</sup> This is the first report of SEP in a cat with long-term survival of more than 3 years without recurrence after surgical adhesiolysis.



**Figure 5** Histopathological image of peritoneal biopsy specimens: (a) low-power image of the peritoneum (H&E,  $\times 20$  magnification, bar =  $1000\ \mu\text{m}$ ) and (b) higher-magnification image of (a). Densely packed collagen fibres with differentiated fibroblast cells were observed (H&E,  $\times 100$  magnification, bar =  $100\ \mu\text{m}$ ). H&E = haematoxylin and eosin

The poor prognosis of SEP is thought to be due to the high risk of perioperative bleeding and the high recurrence rate of adhesive gastrointestinal obstruction.<sup>1–13</sup> Indeed, the cat in the present case had recurrent gastrointestinal obstruction secondary to SEP and postoperative adhesion due to haemorrhage. One reason for the long-term survival in the present case could be that the risk of perioperative bleeding was controlled through careful surgical dissection and use of an HA-CMC membrane intraoperatively to prevent recurrence. Notably, an HA-CMC membrane was not used in the first surgery but was used in the second surgery, which resulted in no recurrence. HA-CMC acts locally as an adhesion barrier and forms physicochemical barriers to prevent adhesion between adjacent tissue surfaces in both humans and horses.<sup>14,15</sup> Many clinical studies in humans have demonstrated the effect of HA-CMC for significantly decreasing the incidence and severity of adhesion formation after surgery.<sup>15</sup> The HA-CMC membrane remains at the wound site 3 weeks after surgery but disappears at 6 weeks.<sup>16</sup> Therefore, the HA-CMC membrane was considered effective in preventing short-term adhesion of SEP in the present case.

The cat in the present case was treated with long-term prednisolone as an additional safeguard against recurrence. Prednisolone therapy for SEP is thought to suppress inflammation, thus preventing fibrin deposition and ascites.<sup>17</sup> In human medicine, prednisolone is the first-line treatment option in managing SEP.<sup>18,19</sup> In veterinary medicine, the use of prednisolone and tamoxifen have been reported for prevention of canine SEP.<sup>6,10</sup> In the present case, short-term prednisolone treatment after the first surgery resulted in recurrence of SEP. After

long-term prednisolone treatment after the second surgery, however, no recurrence of clinical signs was detected on day 1239. These findings suggest that long-term treatment with prednisolone effectively prevents recurrence of SEP in the long term, whereas an HA-CMC membrane prevents adhesion in the short term. However, the appropriate duration and dosing of prednisolone treatment for SEP are not established in veterinary medicine. Most publications in human medicine support a prednisolone dosage of  $0.5\text{--}1.0\ \text{mg/kg/day}$  during the first month, with subsequent tapering throughout the year.<sup>19,20</sup> Based on previous publications and the findings in the present case, treatment with prednisolone for prevention of relapse should not be limited to the short term but should be continued for at least 1 year.

Generally, cases of SEP in veterinary medicine present with massive ascites;<sup>1–12</sup> however, the cat in the present case did not present with massive ascites. Although the mechanism is not entirely clear, the ascitic effusions in SEP are thought to be due to chronic inflammation or portal hypertension.<sup>1</sup> Although the prevalence of ascites in human medicine is unknown, some cases of SEP with mild ascites have been reported; this is thought to be due to early-stage SEP.<sup>21</sup> SEP is categorised into three types in humans: type 1 only encloses the small intestine; type 2 completely covers the intestine; and type 3 encases the whole intestine and other intra-abdominal organs.<sup>22</sup> The cat in the present case had type 1 SEP, which is considered relatively mild. Considering these previous findings, the cat in the present case may have had milder peritonitis than in past cases in the veterinary literature. This could be one of the reasons for the cat's long-term survival.

## Conclusions

This is the first case report of SEP in a cat with long-term survival. The use of an HA-CMC membrane and long-term prednisolone treatment helped to prevent recurrence, contributing to the cat's long-term survival.

**Acknowledgements** We thank Angela Morben DVM, ELS, from Edanz (<https://jp.edanz.com/ac>), for editing a draft of this manuscript.

**Conflict of interest** The authors declared no potential conflicts of interest with respect to the research, authorship, and/or publication of this article.

**Funding** The authors received no financial support for the research, authorship, and/or publication of this article.

**Ethical approval** The work described in this manuscript involved the use of non-experimental (owned or unowned) animals. Established internationally recognised high standards ('best practice') of veterinary clinical care for the individual patient were always followed and/or this work involved the use of cadavers. Ethical approval from a committee was therefore not specifically required for publication in *JFMS Open Reports*. Although not required, where ethical approval was still obtained it is stated in the manuscript.

**Informed consent** Informed consent (verbal or written) was obtained from the owner or legal custodian of all animal(s) described in this work (experimental or non-experimental animals, including cadavers) for all procedure(s) undertaken (prospective or retrospective studies). No animals or people are identifiable within this publication, and therefore additional informed consent for publication was not required.

**ORCID iD** Nozomu Yokoyama  <https://orcid.org/0000-0003-2077-0523>

Kazuyoshi Sasaoka  <https://orcid.org/0000-0002-2990-7808>

## References

- Hardie EM, Rottman JB and Levy JK. **Sclerosing encapsulating peritonitis in four dogs and a cat.** *Vet Surg* 1994; 23: 107–114.
- Barnes K. **What is your diagnosis? Sclerosing encapsulating peritonitis.** *J Am Vet Med Assoc* 2015; 247: 43–45.
- Izawa T, Murai F, Akiyoshi H, et al. **Encapsulating peritoneal sclerosis associated with abnormal liver development in a young dog.** *J Vet Med Sci* 2011; 73: 697–700.
- Setoguchi A, Kadosawa T, Nishimura R, et al. **Sclerosing encapsulating peritonitis in one dog and three cats.** *Jpn J Vet Anesth Surg* 1996; 27: 79–89.
- Adamama-Moraitou KK, Prassinou NN, Patsikas MN, et al. **Sclerosing encapsulating peritonitis in a dog with leishmaniasis.** *J Small Anim Pract* 2004; 45: 117–121.
- Etchepareborde S, Heimann M, Cohen-Solal A, et al. **Use of tamoxifen in a German Shepherd dog with sclerosing encapsulating peritonitis.** *J Small Anim Pract* 2010; 51: 649–653.
- Boothe HW, Lay JC and Moreland KJ. **Sclerosing encapsulating peritonitis in three dogs.** *J Am Vet Med Assoc* 1991; 198: 267–270.
- Gremillet BCH, Porsmoguer C, Bolen G, et al. **Imaging findings in dogs and cats with presumptive sclerosing encapsulating peritonitis.** *Front Vet Sci* 2022; 9. DOI: 10.3389/fvets.2022.891492.
- Sonck L, Chiers K, Ducatelle R, et al. **Encapsulating peritoneal sclerosis in a young cat.** *Vet Rec Case Rep* 2018; 6. DOI: 10.1136/vetreccr-2017-000541.
- Isaac I, Carrera I, Martí J, et al. **Resolution of sclerosing encapsulating peritonitis in a young dog.** *Vet Rec Case Rep* 2020; 8. DOI: 10.1136/vetreccr-2019-001022.
- Carroll KA, Wallace ML, Hill TL, et al. **Pyloric outflow obstruction secondary to sclerosing encapsulating peritonitis in a dog.** *Aust Vet J* 2020; 98: 11–16.
- Veiga-Parga T, Hecht S and Craig L. **Imaging diagnosis-sclerosing encapsulating peritonitis in a dog.** *Vet Radiol Ultrasound* 2015; 56: E65–E69.
- Tsukada Y, Park YT, Mitsui I, et al. **Sclerosing encapsulating peritonitis in a dog with pancreatic ductal adenocarcinoma.** *BMC Vet Res* 2022; 18: 383. DOI: 10.1186/s12917-022-03485-0.
- Mueller PO, Hay WP, Harmon B, et al. **Evaluation of a bioresorbable hyaluronate-carboxymethylcellulose membrane for prevention of experimentally induced abdominal adhesions in horses.** *Vet Surg* 2000; 29: 48–53.
- Guo Y, Zhu Q, Chen S, et al. **Effect of sodium hyaluronate-arboxycellulose membrane (Septrafilm) on postoperative small bowel obstruction: a meta-analysis.** *Surgery* 2021; 169: 1333–1339.
- Bunton RW, Xabregas AA and Miller AP. **Pericardial closure after cardiac operations. An animal study to assess currently available materials with particular reference to their suitability for use after coronary artery bypass grafting.** *J Thorac Cardiovasc Surg* 1990; 100: 99–107.
- Bozkurt D, Sipahi S, Cetin P, et al. **Does immunosuppressive treatment ameliorate morphology changes in encapsulating peritoneal sclerosis?** *Perit Dial Int* 2009; 29 Suppl 2: S206–S210.
- Jagirdar RM, Bozikas A, Zarogiannis SG, et al. **Encapsulating peritoneal sclerosis: pathophysiology and current treatment options.** *Int J Mol Sci* 2019; 20. DOI: 10.3390/ijms20225765.
- Habib SM, Betjes MGH, Fieren MWJA, et al. **Management of encapsulating peritoneal sclerosis: a guideline on optimal and uniform treatment.** *Neth J Med* 2011; 69: 500–507.
- Danford CJ, Lin SC, Smith MP, et al. **Encapsulating peritoneal sclerosis.** *World J Gastroenterol* 2018; 24: 3101–3111.
- Nakamoto H. **Encapsulating peritoneal sclerosis – a clinician's approach to diagnosis and medical treatment.** *Perit Dial Int* 2005; 25 Suppl 4: S30–S38.
- Tannoury JN and Abboud BN. **Idiopathic sclerosing encapsulating peritonitis: abdominal cocoon.** *World J Gastroenterol* 2012; 18: 1999–2004.