



## **Successful medical management of a vaginal wall tear in feline dystocia**

Authors: Meyer, Shaylan, and Berg, Alexia

Source: Journal of Feline Medicine and Surgery Open Reports, 10(1)

Published By: SAGE Publishing

URL: <https://doi.org/10.1177/20551169241243016>

---

BioOne Complete ([complete.BioOne.org](https://complete.BioOne.org)) is a full-text database of 200 subscribed and open-access titles in the biological, ecological, and environmental sciences published by nonprofit societies, associations, museums, institutions, and presses.

Your use of this PDF, the BioOne Complete website, and all posted and associated content indicates your acceptance of BioOne's Terms of Use, available at [www.bioone.org/terms-of-use](https://www.bioone.org/terms-of-use).

Usage of BioOne Complete content is strictly limited to personal, educational, and non - commercial use. Commercial inquiries or rights and permissions requests should be directed to the individual publisher as copyright holder.

---

BioOne sees sustainable scholarly publishing as an inherently collaborative enterprise connecting authors, nonprofit publishers, academic institutions, research libraries, and research funders in the common goal of maximizing access to critical research.



# Successful medical management of a vaginal wall tear in feline dystocia

Shaylan Meyer and Alexia Berg

*Journal of Feline Medicine and Surgery Open Reports*  
1–5

© The Author(s) 2024

Article reuse guidelines:

sagepub.com/journals-permissions

DOI: 10.1177/20551169241243016

journals.sagepub.com/home/jfmsopenreports

This paper was handled and processed by the American Editorial Office (AAFP) for publication in *JFMS Open Reports*



## Abstract

**Case summary** A 2-year-old domestic shorthair queen sustained a tear in the vaginal wall through which the queen herniated a fetus during parturition. An exploratory laparotomy was performed, the patient had an ovariohysterectomy and the fetus was removed vaginally. The tear was managed medically with antibiotics, analgesics and careful monitoring. Assessment of the injury site 2 weeks later confirmed successful healing without the need for surgical intervention in the vaginal wall.

**Relevance and novel information** This is the first report in veterinary medicine describing the successful medical management of a dystocia-related vaginal wall tear in a feline patient without surgical repair.

**Keywords:** Dystocia; vaginal tear; medical management; evisceration

**Accepted:** 14 March 2024

## Introduction

Dystocia is described as a complication that can arise in any veterinary patient at parturition due to maternal or fetal factors. In feline patients, dystocia is an uncommon occurrence, with a reported incidence of 3–5% of total births.<sup>1</sup> While the incidence is relatively low across entire populations of domesticated cats, purebred cats have higher rates of dystocia.<sup>1,2</sup> The most common types of dystocia are related to uterine inertia and fetal malposition.<sup>1</sup> Uterine inertia, defined as absent or weak uterine contractions, comprise over two-thirds of reported feline dystocia cases.<sup>1,3</sup>

Vaginal wall tears are a recognized sequela to dystocia. They occur during parturition due to trauma sustained by the fetus passing through the birth canal. Reported complications of vaginal tears during parturition include uterine, bladder or intestinal evisceration through the tear. Vaginal wall tears are more commonly encountered in equine patients and these are the most described in the veterinary literature.<sup>4,5</sup> Mares have a reported incidence of 4–19% of dystocia, dependent on breed surveyed.<sup>6–8</sup> Fetal malposition is the most common cause, accounting for 64–87% of dystocia cases.<sup>6,8</sup> Vaginal tearing often accompanies these dystocia cases, though the exact incidence is not reported.<sup>8</sup> Treatment strategies for vaginal wall tears in mares include surgical or medical management. Tears significant enough to

cause evisceration are managed surgically with repair occurring transvaginally. Tears without entrapment of viscera can be managed medically through second intention healing.<sup>4,9</sup> Vaginal wall tearing secondary to dystocia in small animal patients is rarely reported, with publications describing surgical management strategies.<sup>10–13</sup> The aim of this report was to describe for the first time the presentation, medical management and outcome for a queen with a dystocia-related vaginal wall tear.

## Case description

A 2-year-old female domestic shorthair cat weighing 3.7kg presented to a veterinary teaching hospital in Massachusetts for pain while defecating 2 weeks after parturition of two stillborn kittens. The queen's pregnancy history included one previous litter before being adopted by the current owner, though specific details

Cummings School of Veterinary Medicine at Tufts University, North Grafton, MA, USA

### Corresponding author:

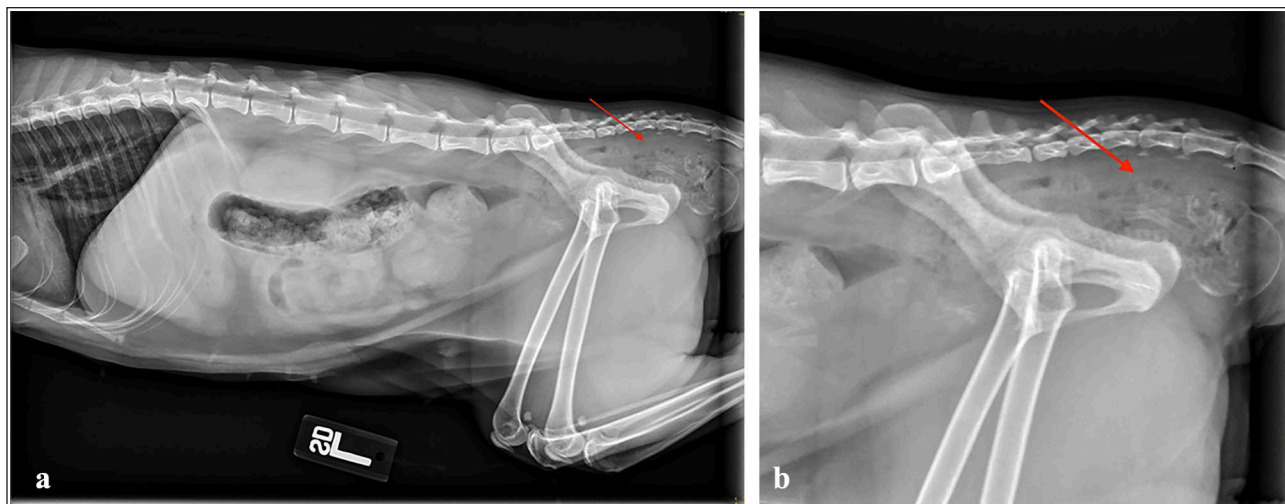
Shaylan Meyer DVM, Cummings School of Veterinary Medicine at Tufts University, 200 Westboro Road, North Grafton, MA 01536, USA

Email: shaylan.meyer@tufts.edu



Creative Commons Non Commercial CC BY-NC: This article is distributed under the terms of the Creative Commons

Attribution-NonCommercial 4.0 License (<https://creativecommons.org/licenses/by-nc/4.0/>) which permits non-commercial use, reproduction and distribution of the work without further permission provided the original work is attributed as specified on the SAGE and Open Access pages (<https://us.sagepub.com/en-us/nam/open-access-at-sage>).



**Figure 1** (a,b) Right lateral abdominal radiographs with a focus on the pelvis. Red arrows indicate the fetus retained in the pelvic canal

were unknown. The queen was hiding and inappetent before presentation. No other signs of continued labor were reported. Vital signs at intake included a fever (103.8°F), sinus tachycardia (220 beats per minute) and a mildly elevated respiratory rate (32 breaths per minute) with normal effort. The queen had a body condition score of 4/9 and was estimated to be dehydrated based on tacky mucous membranes and lab parameters. A prominent swelling of the perineum ventral to the anus, a swollen vulva and white vulvar discharge were noted on physical examination. Digital vaginal examination was limited due to patient reactivity and subsequent temperament; however, no fetus was identified in the palpable canal. Rectal examination, while also limited, did not identify any abnormalities.

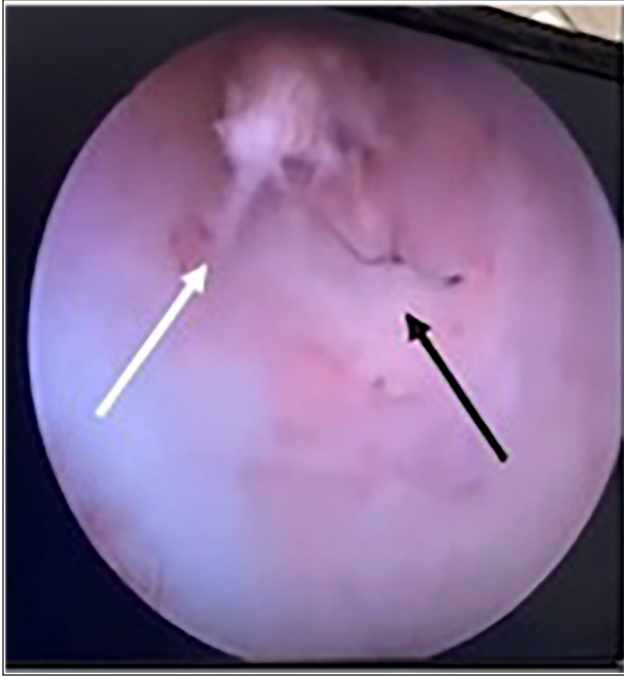Laboratory findings showed normal electrolytes and renal values. The queen was mildly anemic with a packed cell volume of 30% and hyperproteinemic with total solids of 7.0 g/dl. Survey abdominal radiographs identified a retained fetus at the level of the pelvic canal (Figure 1). Point-of-care abdominal ultrasound was negative for free fluid in all quadrants. Complete blood count showed leukopenia (3.89 K/ul [reference interval (RI) 4.5–15.7]) with toxic change and confirmed normocytic, hypochromic, non-regenerative anemia.

The patient was admitted to the hospital and started on intravenous lactated Ringer's solution at 90 ml/kg/day, ampicillin/sulbactam at 30 mg/kg IV q8h and methadone 0.1 mg/kg IV q6h. The queen was induced with propofol 3 mg/kg IV and anesthetized with isoflurane gas for exploratory laparotomy 12h after admission. Intraoperative findings included a diffusely fluid-filled uterus consistent with a post-partum state. The fetus was not palpable toward the pelvis from the

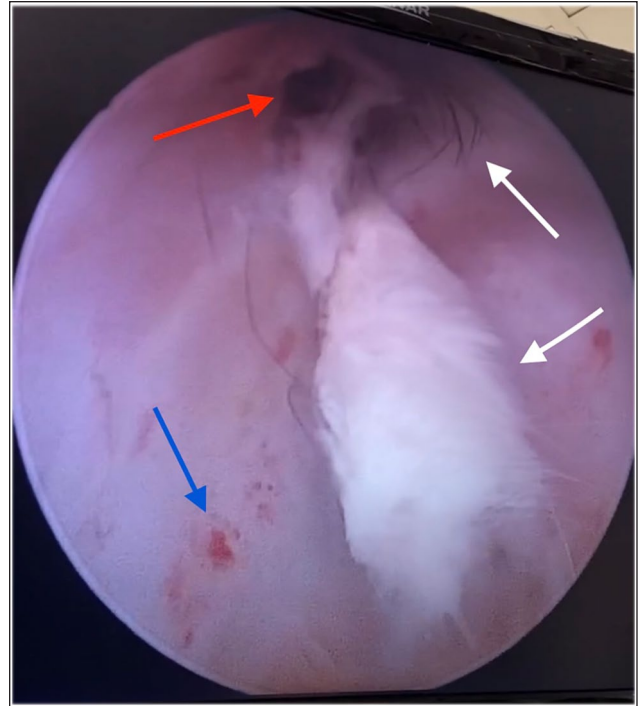
abdomen. Ovariohysterectomy was performed routinely at the owner's request. A digital vaginal examination was repeated while the cat was under general anesthesia. A full-thickness rent of approximately 1.5 cm was identified in the dorsal wall of the vagina. Digital exploration through the rent identified the retained fetus in the perineal space. A necrotic fetus was removed transvaginally in its entirety through the rent via direct visualization aided by a speculum and use of a Carmalt hemostat. The area was copiously lavaged. A thorough digital examination of the rectum did not reveal any compromise in the mucosa. The patient recovered uneventfully from anesthesia and was maintained on the same medical treatments overnight, with the addition of enrofloxacin 5 mg/kg IV q24h and robenacoxib 2 mg/kg SC q24h for three doses in total.

On day 3 of hospitalization, vaginoscopy was performed to evaluate the extent of the mucosal injury and gross viability of the damaged tissue. The queen was placed in dorsal recumbency and aseptically prepped. The cervix was closed and intact (Figure 2). The urethral orifice was normal, ventral and distal to the rent. Visualization of the canal revealed tufts of fur (Figures 2–4), bruising (Figures 3 and 4) and a tear of approximately 1.5 cm in the dorsal aspect of the mid-level of the vagina (Figures 3 and 4). The tissue, although inflamed, was grossly viable, with no evidence of necrosis or purulent discharge. The tear was once more copiously lavaged with sterile saline to remove as much hair and debris as possible. The patient recovered uneventfully.

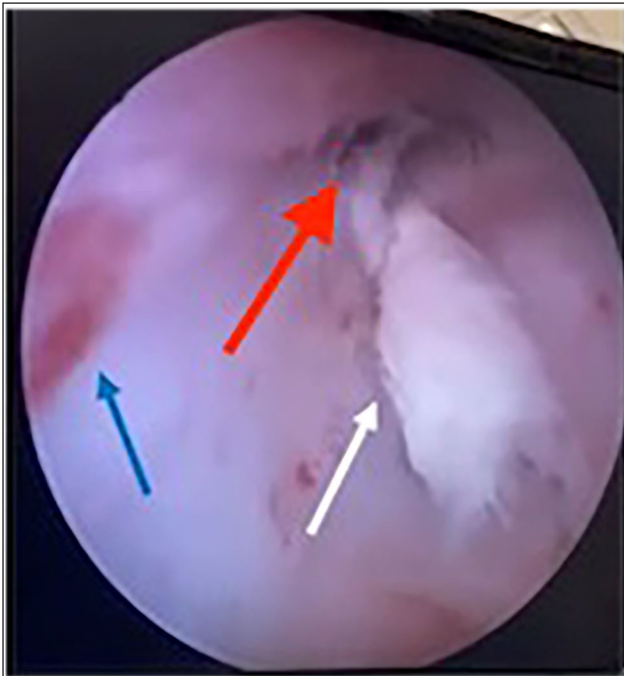
Medical management via second intention healing of the wound was elected with a planned recheck in 2–4 weeks. Urination habits were outwardly normal, and the queen did not attempt to defecate while still in



**Figure 2** Vaginoscopy: the black arrow indicates a closed cervix; the white arrow indicates pre-lavage tufts of fur



**Figure 4** Vaginoscopy: the white arrows indicate pre-lavage tufts of fur; the blue arrow indicates bruising on the lateral vaginal wall; the red arrow indicates the tear with tufts of fur inside



**Figure 3** Vaginoscopy: the white arrow indicates pre-lavage tufts of fur; the blue arrow indicates bruising on the lateral vaginal wall; the red arrow indicates the tear with tufts of fur inside

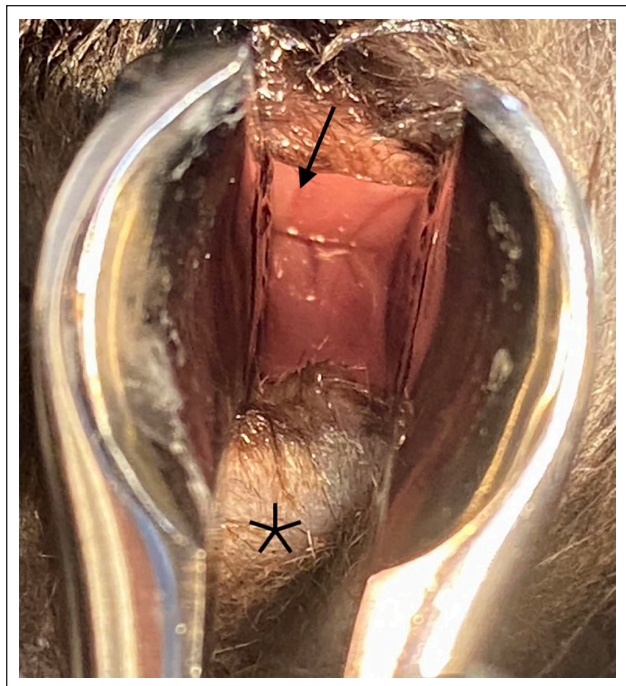
hospital. Discharge occurred on day 4 of hospitalization with amoxicillin/clavulanic acid 13.75mg/kg PO q12h,

enrofloxacin 5 mg/kg PO q24h and gabapentin 10 mg/kg PO q12h for 14 days.

Two weeks later, the patient presented for a scheduled recheck examination. The owner reported the queen was eating, drinking and acting normally at home. The physical examination was unremarkable, including normal external perineal tissue and healed surgical incision. The patient was sedated with dexmedetomidine 5 µg/kg IM and butorphanol 0.3mg/kg IV to facilitate the examination. On both digital palpation and visual assessment with the aid of a speculum, the tear was completely healed. The mucosa was pink with no bruising and there was no evidence of stricture (Figure 5). The queen recovered from sedation and was discharged. The owner was called 4 weeks later to check in and reported the cat was doing well at home with an excellent appetite, appropriate energy levels, normal urination and normal stool production.

## Discussion

There is a paucity of information about small animal vaginal wall pathology during dystocia. The available veterinary literature centers on large animal patients. Vaginal wall tears (or vestibule tears) in equine patients generally occur during the second stage of labor. They can be associated with forced traction or poor relaxation of the perineum/vulva. There are three main types of



**Figure 5** Vaginal examination: the black arrow indicates the healed mucosa; the black asterisk indicates the ventral aspect of the vestibule

tearing; first-degree tears are superficial lacerations of the vaginal wall; second-degree tears are lacerations of the vaginal wall with extension through to the perineal space; and third-degree tears are lacerations that extend through to the colon.<sup>14,15</sup> Complications associated with vaginal tears include evisceration, fistula formation, inability to breed in the future, sepsis and death.<sup>10</sup> Though grading systems for tears exist in large animal medicine, there is no reported official grading system in small animal medicine.<sup>5</sup>

Treatment is dependent on the degree of tear and the status of the abdominal viscera. First-degree tears can be largely managed medically with antibiotics, anti-inflammatories and second intention healing. Second- and third-degree tears are treated with antibiotics and anti-inflammatories for several weeks until recheck to re-evaluate the need for surgical repair. The goal of this is to optimize safe closure of the defects as they can be contaminated.<sup>9</sup> Repair is performed transvaginally as well as transrectally for third-degree injuries.<sup>5,14,15</sup> Mares sustaining any degree of tear have an excellent chance of survival.<sup>9,14,16</sup>

Vaginal tearing secondary to parturition in small animals is rarely reported and, as such, there is a lack of published treatment strategies and outcomes to guide practitioners. In dogs, four published case reports exist with a variety of comorbidities. All patients underwent

some form of surgical intervention, were medium to large breed dogs and experienced some level of evisceration. A 3-year-old Rottweiler had her bladder accidentally removed as part of a mass of necrotic tissue protruding from the vulva from a vaginal tear. This was discovered intraoperatively during a cesarean section and she was euthanized under anesthesia after removal of all puppies.<sup>11</sup> A 1.5-year-old German Shepherd dog mix with evisceration of the intestines, bladder and uterine horns through a vaginal tear underwent exploratory laparotomy to safely reduce the abdominal viscera and perform a partial vaginectomy. She died from septic shock in the postoperative period.<sup>10</sup> A case of an adult mixed-breed dog with bladder evisceration through a vaginal tear died from septic shock while under anesthesia for exploratory laparotomy.<sup>13</sup> A 4-year-old hound dog mix with intestinal evisceration through a vaginal tear survived to discharge after exploratory laparotomy to reduce the intestines and transvaginal repair of the tear.<sup>12</sup> The published literature in cats is even more sparse, with only two cases reported. In both cases, the cats experienced uterine evisceration through vaginal tearing with no colonic involvement, underwent exploratory laparotomy to repair the tear and survived to discharge.<sup>17,18</sup>

While grading systems for vaginal wall tears are not officially defined in small animal medicine, the degree of injury in our patient was most consistent with a second-degree tear in a large animal patient. Treatment strategies for this level of injury are mixed, with surgical and medical management being options dependent on factors such as organ evisceration or contamination of the site.<sup>19</sup> With no colonic involvement, no evisceration and no peritoneal compromise on exploratory laparotomy, medical management for the vaginal tear was elected as the first-line treatment in this patient. As in large animal medicine, anti-inflammatories and antibiotics were prescribed and the patient was monitored closely for any signs of complication, including foul smelling vaginal discharge, stranguria, tenesmus or malaise. Starting with medical management also gave the benefit of time to allow for tissue swelling to resolve, for drainage to continue from the perineal space and for declaration of tissue viability in the event surgery was needed later. We suspect vaginal tearing is reported less in cats due to conformation and fetal size. Questions regarding exact pathophysiology and incidence remain unclear.

## Conclusions

This is the first report of a parturition-related full-thickness vaginal wall tear in a queen in which medical management was the first elected treatment strategy. Given the successful outcome in this patient, it is

reasonable to attempt medical management in feline patients with no evidence of organ evisceration, no colonic compromise and suspicion for infection or vaginal tissue compromise. More data are needed to determine treatment outcomes of parturition-related vaginal injuries in cats.

**Conflict of interest** The authors declared no potential conflicts of interest with respect to the research, authorship, and/or publication of this article.

**Funding** The authors received no financial support for the research, authorship, and/or publication of this article.

**Ethical approval** The work described in this manuscript involved the use of non-experimental (owned or unowned) animals. Established internationally recognized high standards ('best practice') of veterinary clinical care for the individual patient were always followed and/or this work involved the use of cadavers. Ethical approval from a committee was therefore not specifically required for publication in *JFMS Open Reports*. Although not required, where ethical approval was still obtained, it is stated in the manuscript.

**Informed consent** Informed consent (verbal or written) was obtained from the owner or legal custodian of all animal(s) described in this work (experimental or non-experimental animals, including cadavers) for all procedure(s) undertaken (prospective or retrospective studies). No animals or people are identifiable within this publication, and therefore additional informed consent for publication was not required.

## References

- Holst BS. **Feline breeding and pregnancy management: what is normal and when to intervene.** *J Feline Med Surg* 2022; 24: 221–231.
- Gunn-Moore D and Thrusfield M. **Feline dystocia: prevalence, and association with cranial conformation and breed.** *Vet Rec* 1995; 136: 350–353.
- Talat Naoman U. **Causes and treatment of feline dystocia.** *J Appl Vet Sci* 2021; 6: 28–231.
- Elkasapy A and Ibrahim I. **Contribution to reconstruction of third degree rectovestibular lacerations in mares.** *Open Vet J* 2015; 5: 23–26.
- Belknap JK and Nickels FA. **A one-stage repair of third-degree perineal lacerations and rectovestibular fistulae in 17 mares.** *Vet Surg* 1992; 21: 378–381.
- Parkinson TJ, Vermunt JJ and Noakes DE. **Prevalence, causes and consequences of dystocia.** In: Noakes DE, Parkinson TJ and England GCW (eds). *Veterinary reproduction and obstetrics*. 10th ed. Edinburgh: Elsevier, 2019, pp 214–233.
- Vandeplassche M. **Sir Frederick Smith Memorial lecture: obstetrician's view of the physiology of equine parturition and dystocia.** *Equine Vet J* 1980; 12: 45–49.
- Ginther OJ and Williams D. **On-the-farm incidence and nature of equine dystocias.** *J Equine Vet Sci* 1996; 16: 159–164.
- Orsini JA and Diver TJ. **Reproductive system.** In: Orsini JA and Divers TJ (eds). *Equine emergencies: treatment and procedures*. 4th ed. Edinburgh: Elsevier Saunders, 2014, pp 418–449.
- Prassinis N, Adamama-Moraitou K, Ververidis H, et al. **Vaginal rupture and evisceration in a dog.** *Acta Vet Hung* 2010; 58: 309–315.
- Mandell DC, Neath P and Drobatz KJ. **Urinary bladder herniation through a vaginal tear in a rottweiler with dystocia.** *J Vet Emerg Crit Care* 2000; 10: 173–175.
- Erdoğan G, Uçar EH, Kibar B, et al. **A rare complication of the postpartum period in a dog: vaginal evisceration.** *Kafkas Univ Vet Fak Derg* 2015; 22: 315–318.
- Coutinho BP, Labat É, Coutinho Junior AS, et al. **Retroflexion and evisceration of the urinary bladder due to rupture of the genital organs in the bitch.** *Ciênc Rural* 2013; 43: 318–321.
- Ghamsari SM, Malekshahi Nejad MM and Moradi O. **Evaluation of modified surgical technique in repair of third-grade perineal lacerations in mare.** *Iran J Vet Surg* 2008; 3: 71–75.
- Parkinson TJ and Noakes DE. **Injuries and diseases consequent upon parturition.** In: Noakes DE, Parkinson TJ and England GCW (eds). *Veterinary reproduction and obstetrics*. 10th edn. Edinburgh: Elsevier, 2019, pp 333–348.
- Wilson DA and Sherlock C. **Perineal injury.** In: Wilson DA (ed). *Clinical veterinary advisor: the horse*. St Louis, MO: Elsevier/Saunders, 2011, pp 437–438.
- Freire M and Diaw M. **Transvaginal uterine evisceration during labor in a Bengal queen.** *JFMS Open Rep* 2019; 5. DOI: 10.1177/2055116919872301.
- Bigliardi E, Di Ianni F, Parmigiani E, et al. **Complete uterine prolapse without uterine mucosal eversion in a queen.** *J Small Anim Pract* 2014; 55: 235–237.
- Gomez JH and Rodgerson DH. **How to repair cranial vaginal and caudal uterine tears in mares.** *AAEP Proc* 2008; 54: 295–297.