



SURVEY OF NEOPLASIA IN RED KANGAROOS (MACROPUS RUFUS), 1992–2002, IN A ZOOLOGICAL COLLECTION

Authors: Suedmeyer, WmKirk, and Johnson, Gayle

Source: Journal of Zoo and Wildlife Medicine, 38(2) : 231-239

Published By: American Association of Zoo Veterinarians

URL: [https://doi.org/10.1638/1042-7260\(2007\)038\[0231:SONIRK\]2.0.CO;2](https://doi.org/10.1638/1042-7260(2007)038[0231:SONIRK]2.0.CO;2)

BioOne Complete (complete.BioOne.org) is a full-text database of 200 subscribed and open-access titles in the biological, ecological, and environmental sciences published by nonprofit societies, associations, museums, institutions, and presses.

Your use of this PDF, the BioOne Complete website, and all posted and associated content indicates your acceptance of BioOne's Terms of Use, available at www.bioone.org/terms-of-use.

Usage of BioOne Complete content is strictly limited to personal, educational, and non - commercial use. Commercial inquiries or rights and permissions requests should be directed to the individual publisher as copyright holder.

BioOne sees sustainable scholarly publishing as an inherently collaborative enterprise connecting authors, nonprofit publishers, academic institutions, research libraries, and research funders in the common goal of maximizing access to critical research.

SURVEY OF NEOPLASIA IN RED KANGAROOS (*MACROPUS RUFUS*), 1992–2002, IN A ZOOLOGICAL COLLECTION

Wm. Kirk Suedmeyer D.V.M., Dipl. A.C.Z.M. and Gayle Johnson, D.V.M., Ph.D., Dipl. A.C.V.P.

Abstract: An increase in the proportion of cases with neoplasia observed in a collection of captive red kangaroos (*Macropus rufus*) when compared with historical records and the paucity of reported neoplasms in kangaroos in the literature prompted a 10-yr review of all red kangaroo necropsies. Individual necropsy, medical, and inventory records for all kangaroos at the Kansas City Zoo were reviewed for the period 1 January 1992 to 31 December 2002. Two squamous cell carcinomas of the oral cavity, two mammary gland adenocarcinomas, a multicentric T-cell lymphosarcoma, and one submucosal pyloric lipoma were diagnosed in six of 28 kangaroo deaths. Three neoplasms were diagnosed antemortem. Four of the six neoplasms were considered malignant, and all four had metastasized. The mean age at death was 11 yr. All six animals with neoplasms were female; however, the exhibit population was composed solely of females. Only 11 cases of neoplasia in red kangaroos have been reported in the literature. On the basis of these cases and a review of the literature, the most commonly observed neoplasms in red kangaroos are mammary gland adenocarcinomas and oral squamous cell carcinomas. Common denominators were not identified in these cases, although chronic gingivitis could have been a contributing factor in the development of the oral squamous cell carcinomas.

Key words: *Macropus rufus*, mammary gland adenocarcinoma, neoplasia, red kangaroo, squamous cell carcinoma.

INTRODUCTION

Neoplastic disease in the order Marsupialia has been rarely reported except in two families: Phascolaridae and Petauridae.⁴ Craniofacial tumors and lymphoid neoplasia are commonly documented in koalas (*Phascolarctos cinereus*)⁴ and can be associated with a retrovirus.⁴ Recently, frequent cases of devil facial tumor disease, an undifferentiated soft tissue neoplasm, have been recognized in Tasmanian devils, Dasyuridae.¹² Splenic and lymphoid neoplasia in sugar gliders (*Petaurus breviceps*) and greater gliders (*Petaurus norfolcensis*) in the family Petauridae are commonly observed.⁴ Reports of neoplasia in Macropodidae are documented occasionally^{1–11,13–24} but rarely reported in red kangaroos (*Macropus rufus*).^{4,8,11,13,18,19,24} A review of neoplastic disease in a collection of captive red kangaroos was conducted after an increase in the number of deaths with neoplasia relative to the total number of red kangaroo deaths was identified at the Kansas City Zoo when compared with historical records.

This report characterizes the neoplasms observed in the collection over a 10-yr period and summarizes the reported neoplasms in red kangaroos and other macropods.

Red kangaroos are large macropods, with a head and body length of 1.15 m in males and 1.0 m in females. In males, the tail averages 88 cm long and 82 cm in females.²³ The average weight of the male is 66 kg, and the female averages 26.5 kg.²³ In general, red kangaroos live 12–18 yr in captivity. In the wild, they are found in the low woodlands, plains country, and arid zones of Australia. It is the only kangaroo species that is characteristic of, and well suited to, the arid zones. Its population is abundant in some areas; hence, it can be considered an agricultural pest in such regions.²³

MATERIALS AND METHODS

Individual red kangaroo necropsy and clinicopathologic records including antemortem biopsies were reviewed from 1 January 1992 through 31 December 2002. The percentage of deceased in animals affected by neoplasia was determined. All 28 kangaroos that died or were euthanatized during the study period were necropsied. Sets of tissue, including the lesions, were fixed in 10% buffered formalin for an average of 72 hr, embedded in paraffin, sectioned at 5 μ m, and stained with hematoxylin and eosin. Immunohistochemical stains to detect expression of CD3 and B1a antigens were per-

From the Kansas City Zoo, 6800 Zoo Drive, Kansas City, Missouri 64132, USA (Suedmeyer); and the Veterinary Medical Diagnostic Laboratory, University of Missouri–Columbia, College of Veterinary Medicine, 1600 East Rollins, Columbia, Missouri 65211, USA (Johnson). Correspondence should be directed to Dr. Suedmeyer (kirk.suedmeyer@fotzkc.org).

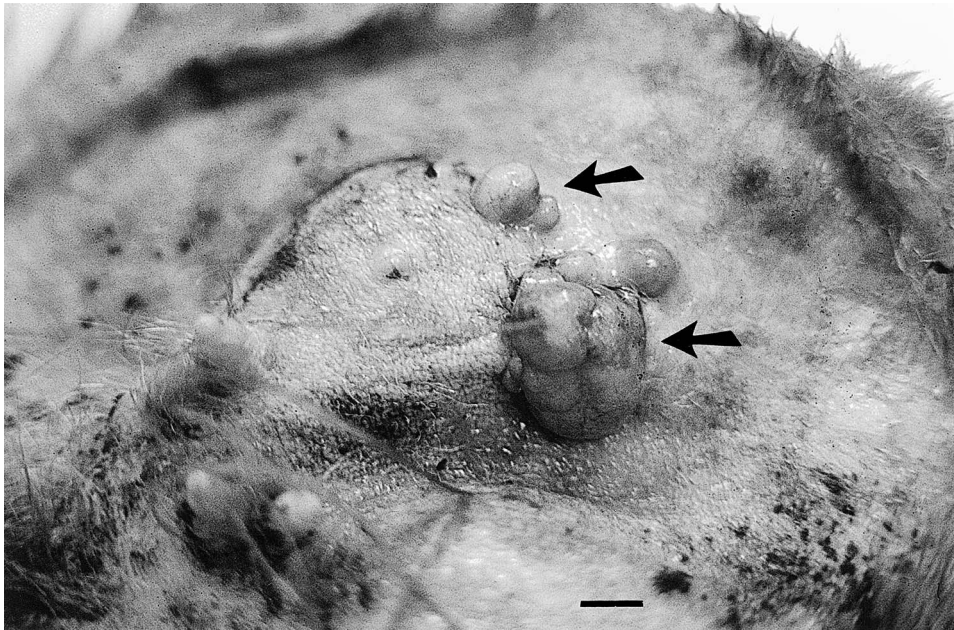


Figure 1. Red kangaroo, case 1. Nodular proliferations are associated with the mammary glands (arrows), mammary gland adenocarcinoma. The teats are in the lower left field. Bar = 5 mm.

formed on sections of the lymphosarcoma (case 5) with the peroxidase–anti-peroxidase technique. Further assessment for a viral etiology was not pursued with this case.

On average, 24 female kangaroos resided at the Kansas City Zoo annually from 1992 to 2002. One male red kangaroo was brought into the collection temporarily for breeding from 1993 to 1995, and other males in 1996 and 2001. The kangaroos were maintained on free choice brome hay, a commercial pelleted diet (Mazuri ADF, PMI Feeds, St. Louis, Missouri 63166-6812, USA), small amounts of fresh produce, and fresh water on a daily basis. A new kangaroo exhibit and holding area was completed in 1993 over a landfill site.

RESULTS

Case 1, Case 2

Two 14-yr-old multiparous female kangaroos presented with lymphadenopathy. One female (case 1) had paresis of the rear limbs and lethargy. The second kangaroo (case 2) was evaluated for a periapical abscess of the first molar tooth of the left mandibular arcade. Both animals were euthanized on finding mammary gland masses with radiographic evidence of pulmonary metastases. Necropsy examination demonstrated multiple raised, nodular masses of 5–15 by 5–15 by 4–10 mm associated with the mammary glands in both animals

(Fig. 1), generalized lymphadenopathy, and numerous, well-circumscribed nodules within the pulmonary tissues. Many of the nodules in the lungs and mammary glands had necrotic centers.

Histopathologic evaluation of the mammary gland masses from case 1 identified interconnected nests, ribbons, and acini of epithelial cells separated by bands of mature connective tissue consistent with a diagnosis of mammary adenocarcinoma (Fig. 2). The cells were columnar to polyhedral with vesicular nuclei. Up to three mitotic figures were present in each high-power field. The pulmonary masses were histologically identical to the mammary gland tumors. Sections of spinal cord demonstrated dilatation of ventral axon sheaths, but neoplasia was not noted. No other tissues were affected by the neoplastic process, and they did not demonstrate any pathologic changes of clinical significance.

Histopathologic examination of the mammary gland tumors of case 2 demonstrated nests and tubules of neoplastic polyhedral epithelial cells, with 2–5 mitoses per high-power/ $\times 400$ field, consistent with a diagnosis of mammary adenocarcinoma. Some pulmonary metastases had necrotic to mineralized centers. The pulmonary metastases had up to eight mitotic figures per high-powered field. No other significant lesions were noted in the remaining tissues.

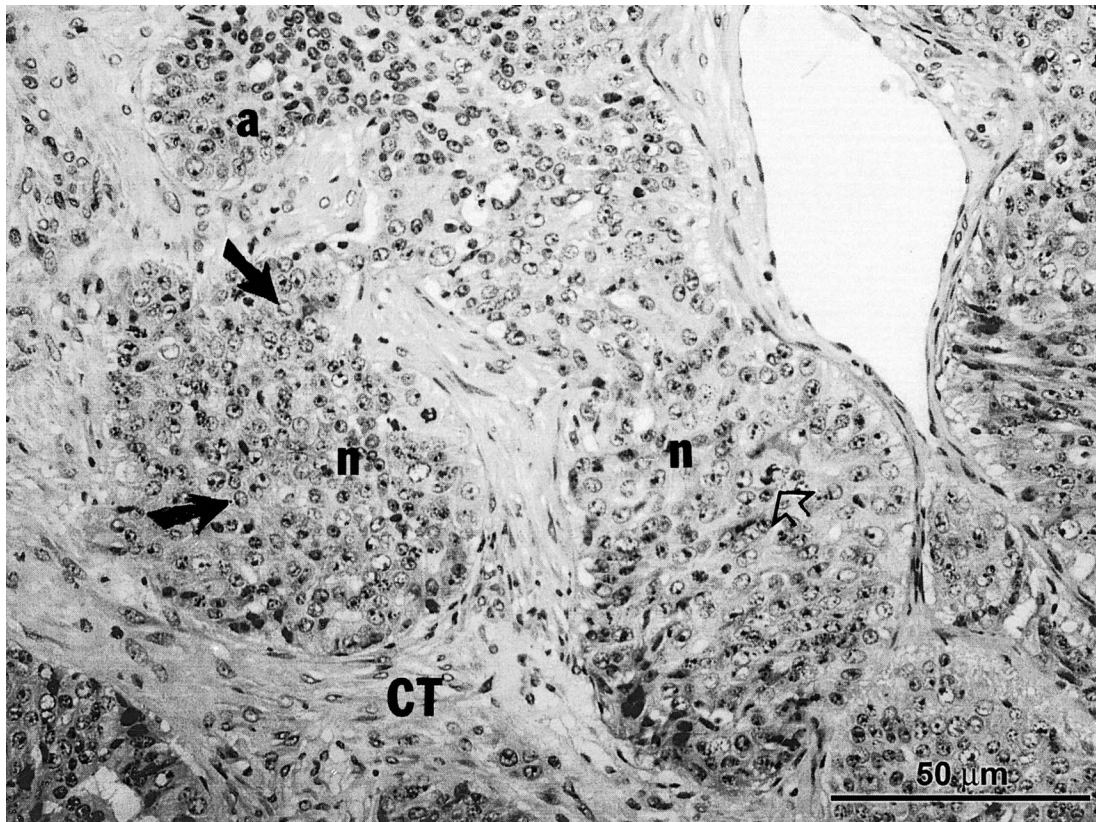


Figure 2. Red kangaroo. Photomicrograph of a mammary gland adenocarcinoma. Note the nests (n) of neoplastic epithelial cells with interconnections (arrows) separated by bands of mature connective tissue (ct) and a mitotic figure (open arrow). H&E, bar = 50 μ m.

Case 3, Case 4

Two kangaroos (case 3, case 4) were evaluated for periapical abscesses of tooth roots. An 11-yr-old female (case 3) had a periapical abscess and an associated gingival mass at the first molar tooth of the right maxillary arcade. Initial gingival biopsies under general anesthesia demonstrated gingivitis and gingival hyperplasia. Rapid invasion of the right maxilla by the mass with loss of all the maxillary teeth ensued. The kangaroo was euthanized 2 mo later. Necropsy revealed extensive destruction of the ventral right maxillary and palatine bones extending to the zygomatic arch. Large amounts of caseous debris were noted in the center of the lesion. Ipsilateral mandibular lymphadenopathy and a 3-mm-diameter corneal opacity were observed. Histopathologic evaluation of the maxillary gingival tissues demonstrated variably sized multiple large and small cornified areas of neoplastic invasion supported by fibrovascular stroma. These areas contained whorls of lamellate keratin (keratin

pearls), 8–20 cells thick, composed of cells from the stratum spinosum (Fig. 3). Polygonal cells with vesicular nuclei, exhibiting anisocytosis and anisokaryosis infiltrated between the larger areas of cornification. The histologic architecture was consistent with a diagnosis of oral squamous cell carcinoma. The remaining tissues were considered normal.

Case 4, a 10-yr-old female, was evaluated for a left mandibular periapical abscess of the first molar tooth. A gingival mass (1 by 2 by 2 cm) associated with the lingual aspect of the tooth was biopsied under general anesthesia. Histopathologic examination identified gingival infiltration with islands of polygonal epithelial cells with round vesicular nuclei, large prominent nucleoli, and moderate to abundant, pink, glassy cytoplasm with intercellular bridges, highly suggestive of squamous cell carcinoma. Dyskeratosis was present, but no mitotic figures were observed. There was enlargement of the ipsilateral mandibular lymph node. The kangaroo

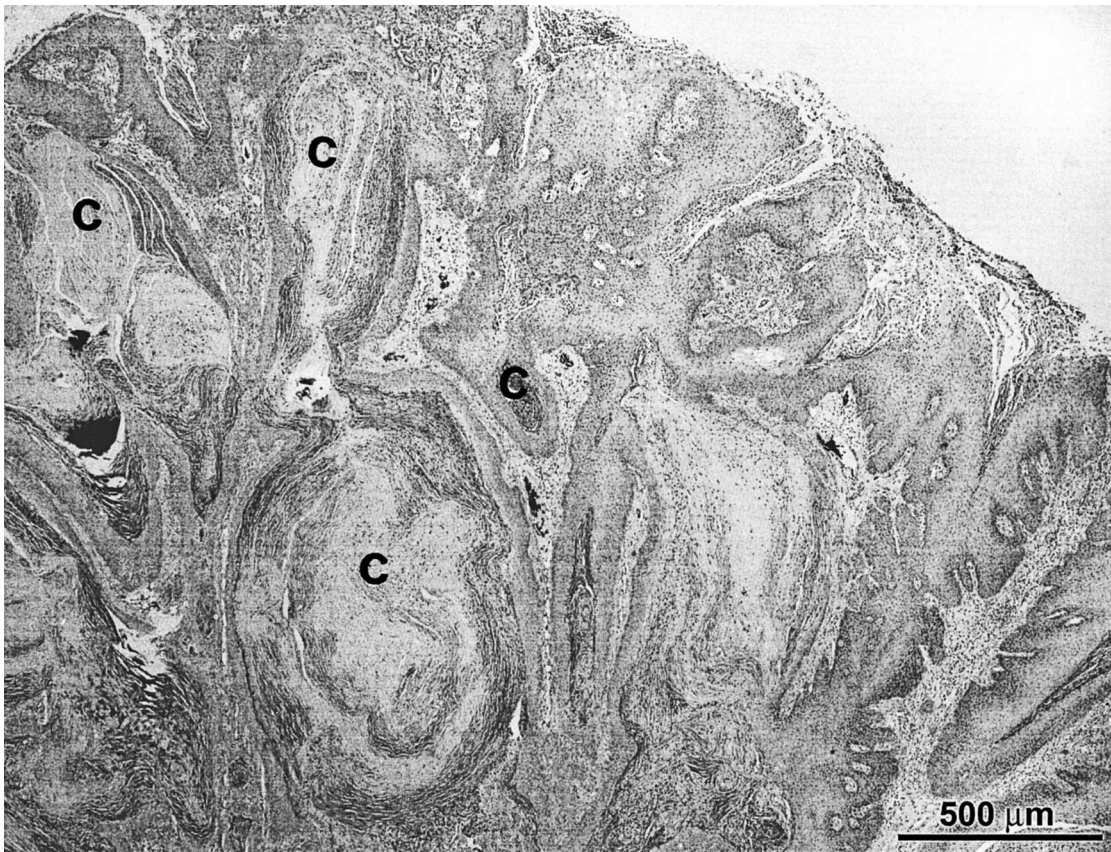


Figure 3. Red kangaroo. Photomicrograph of a gingival mass. Note the large and small areas of cornification (c) composed of lamellate keratin (pearls) typical of squamous cell carcinoma. H&E, bar = 500 μ m.

was euthanatized. Further histopathologic evaluation of the gingival mass at necropsy demonstrated nests and cords of squamous cells of varying size with rare individual cell keratinization and mitotic figures. The mandibular lymph node was replaced by an extensive mass composed of squamous cells similar to those seen in the gingival biopsy. No additional significant histologic abnormalities were apparent.

Case 5

A 5-yr-old female kangaroo (case 5) presented with facial edema in March 1993. The animal was treated once with corticosteroids (1 mg/kg i.m. Dexamethasone sodium phosphate, Vedco, St. Joseph, Missouri 64504, USA) and the edema resolved within 24 hr. Two months later, facial edema recurred, and it was treated similarly, but the kangaroo was found dead 2 days later. At necropsy, disseminated ecchymoses up to 2 cm in diameter were noted in the subcutis, skeletal, and cardiac

muscle, pancreas, intestines, and gall bladder. On histopathologic interpretation, scattered foci of lymphocytes were in the myocardium and lymphocytes infiltrated salivary gland and hepatic portal areas (Fig. 4). The lymph node architecture was disrupted by sheets of lymphoblasts and small lymphocytes without follicular formation or plasma cell differentiation. These cells were identified as T cells by immunohistochemical staining with anti-CD3 reagent (Monoclonal mouse anti-human CD3, DakoCytomation Colorado Inc., Fort Collins, Colorado 80525, USA), consistent with a final diagnosis of T-cell lymphosarcoma (Fig. 5). Significant lesions were not found in remaining organs.

Case 6

One 13-yr-old kangaroo (case 6) presented with gastric dilatation and volvulus and died soon after. Necropsy revealed gastric dilatation and 180° volvulus with a firm 10 cm rounded mass impinging on the pylorus. Histopathologic examination dem-

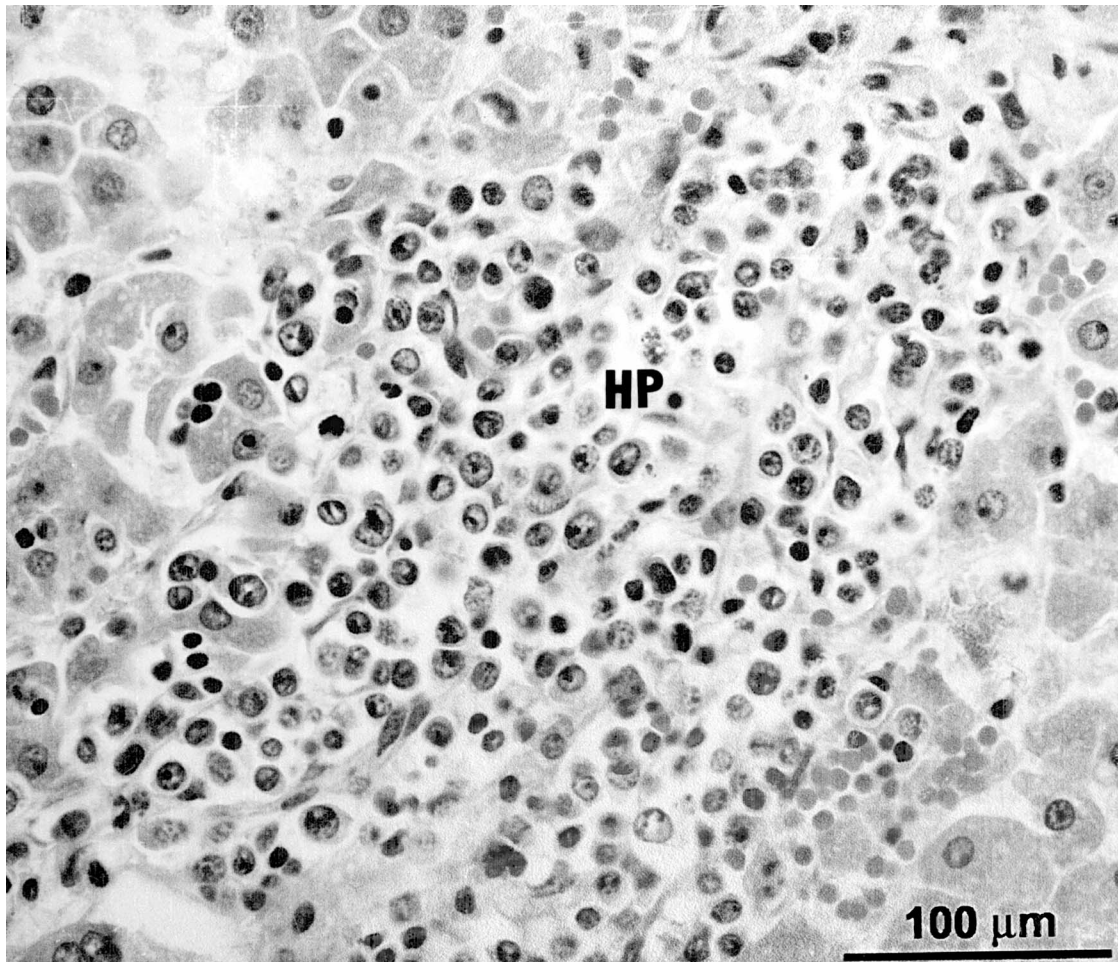


Figure 4. Red kangaroo. Photomicrograph of hepatic tissue with T-cell lymphosarcoma. Note the infiltration of the hepatic portal area (HP) by neoplastic lymphocytes. H&E, bar = 100 μ m.

onstrated prominent submucosal lymphoid aggregates overlying a large, well-defined submucosal mass composed of adipocytes, consistent with a lipoma (Fig. 6). Sections of stomach displayed extensive hemorrhage throughout the lamina propria, obscuring the mucosal architecture. Diffuse edema and hemorrhage were noted in the submucosa. The spleen demonstrated severe congestion, compatible with gastric dilatation and volvulus. Blockage of gastric outflow appeared to predispose the kangaroo to gastric dilatation and volvulus. The remaining tissues were within normal limits.

Records for kangaroos residing at the Kansas City Zoo before 1992 failed to find any documented cases of neoplasia dating to 1965. A total of 26 kangaroos died during 1965–1992, 23 of which were necropsied. The average age at the time of

necropsy for these kangaroos was 2 yr. There were eleven male, nine female and three individuals of unknown gender. Ninety-eight red kangaroos were on exhibit during that time, although many were subsequently sent to other facilities. Their ultimate disposition is unknown.

DISCUSSION

Causes for the relatively common occurrence of neoplasia in the study population of kangaroos during this time period are unknown, but neoplasia is generally more common in aged animals. Four of six neoplasms (two mammary gland adenocarcinomas, the T-cell lymphosarcoma and one squamous cell carcinoma) had metastasized and were considered malignant. The two kangaroos with mammary gland adenocarcinomas (cases 1 and 2)

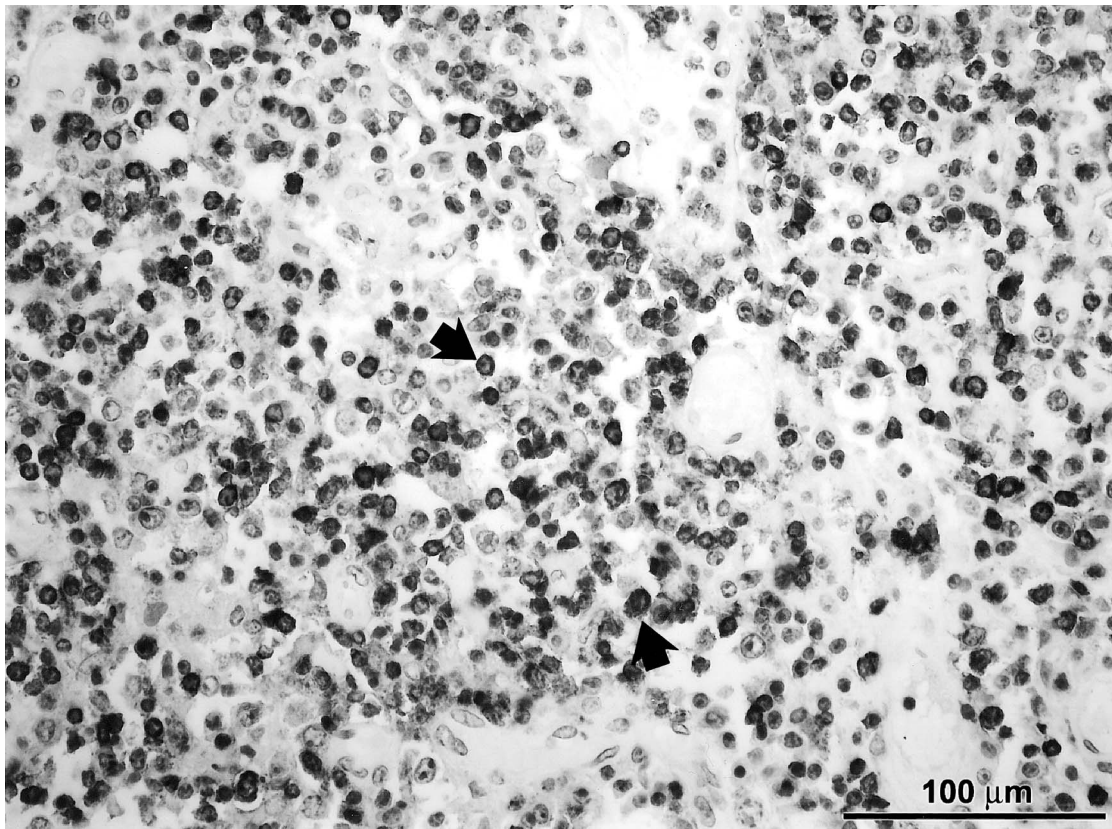


Figure 5. Red kangaroo. Photomicrograph of hepatic tissue stained to identify T lymphocytes (arrows). Anti-CD3 reagent, bar = 100 μm .

were unrelated. Neoplasia was not noted in the spinal cord of case 1, and no other pathologic process was identified that could explain the clinical signs observed. Biopsies of the gingivitis and gingival hyperplasia found in case 3 were probably not performed at adequate depths to show the carcinoma. Clinical signs of neoplasia were not noted until each animal was in a decompensated state or evaluated for other illnesses. Neoplasia in red kangaroos is reported uncommonly.^{4,8,11,18,19,24} Eleven additional neoplastic diseases in red kangaroos have been reported in the literature (Table 1). One mammary gland adenocarcinoma, an ovarian stromal tumor, and a basal cell epithelioma of the pouch were noted in three red kangaroos out of a total of 14 proliferative lesions in 444 necropsies of macropods.⁴

Overall, neoplasia appears to be infrequently reported in other species of Macropodidae as well (Table 2). In two reviews of neoplasia of 3,127 mammal necropsies, only two neoplasms were documented in 314 necropsies of Macropodidae: a

squamous cell carcinoma of the cervix in a parma wallaby (*Macropus parma*) and an adenocarcinoma of the oral cavity in a Bennett's wallaby (*Macropus rufogrisea*).^{6,9} On the basis of the results presented here and in previously reported cases, the most commonly observed neoplasms in red kangaroos are mammary gland adenocarcinomas, and squamous cell carcinomas, specifically of the oral cavity (Table 1). The oral squamous cell carcinomas in the cases presented here could have developed in relation to chronic dental disease. Causes for the other neoplasms are unknown, although construction of new facilities over an old landfill might have played a role in development through exposure to environmental carcinogens. Investigation into other causes, such as retroviruses, warrants further consideration.

Neoplasia in red kangaroos is probably more common than previously reported. The apparent increasing occurrence of neoplasia in this study is difficult to assess because of the relatively small population. Older, apparently healthy kangaroos

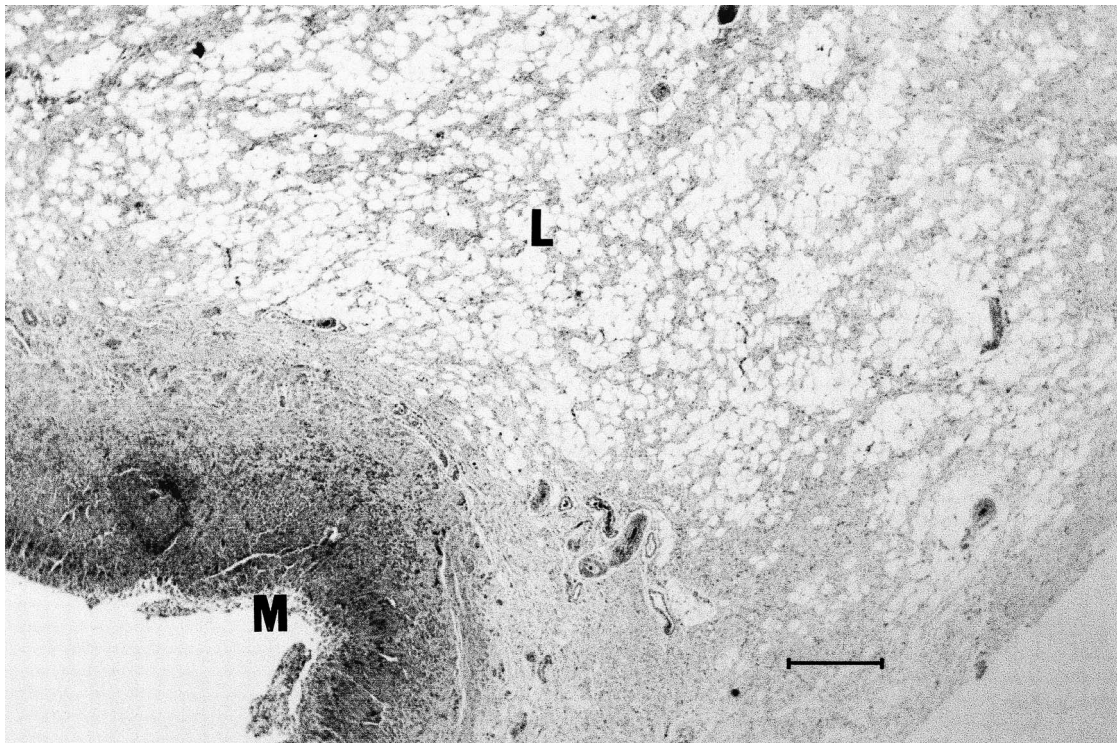


Figure 6. Red kangaroo. Photomicrograph of the pylorus demonstrating a large, discrete submucosal lipoma (L). The mucosa (M) is within normal limits. H&E, bar = 2 mm.

Table 1. Summary of reported neoplasms in red kangaroos (*Macropus rufus*).

| Sex | Age (yr) | Neoplasm | Site(s) |
|------------|----------|-------------------------|--|
| F (case 1) | 14 | adenocarcinoma | mammary gland, pulmonary tissues |
| F (case 2) | 14 | adenocarcinoma | mammary gland, pulmonary tissues |
| F | 20 | adenocarcinoma | mammary gland ⁴ |
| — | — | adenocarcinoma | pulmonary tissues ¹³ |
| M | — | adenocarcinoma | stomach, spleen, liver, kidney ¹⁹ |
| M | — | adenocarcinoma | stomach, spleen, pulmonary tissues ¹⁹ |
| F (case 3) | 10 | squamous cell carcinoma | oral cavity |
| F (case 4) | 11 | squamous cell carcinoma | oral cavity, submandibular lymph node |
| F | 7 | squamous cell carcinoma | oral cavity ¹¹ |
| — | — | squamous cell carcinoma | stomach ¹³ |
| F (case 5) | 5 | T-cell lymphosarcoma | multicentric |
| F (case 6) | 13 | lipoma | pyloric submucosa |
| — | — | papilloma | skin ¹⁸ |
| M | — | seminoma | testicle ²⁴ |
| — | — | basal cell epithelioma | pouch ⁴ |
| — | — | stromal tumor | ovary ⁴ |
| F | 5 | oligodendrocytoma | brain ⁸ |

Table 2. Summary of reported neoplasms in Macropodidae.

| Common name | Scientific name | Sex | Age (yr) | Neoplasm |
|--------------------------|---------------------------------|-----|----------|--|
| Rufous bettong | <i>Aepyprymnus rufescens</i> | F | — | splenic and hepatic vasoformative proliferation ² |
| Agile wallaby | <i>Macropus agilis</i> | F | — | duodenal carcinoma ⁴ |
| | | M | <1 | lymphoproliferation in lymph node ⁴ |
| Bennett's wallaby | <i>Macropus rufogriseus</i> | — | — | focal hepatobiliary proliferation ³ |
| | | — | — | squamous cell carcinoma-base of pinna ⁴ |
| | | — | — | undifferentiated lymphoid neoplasia of liver ³ |
| | | — | — | bile duct proliferation ³ |
| | | F | — | oral adenocarcinoma ⁶ |
| Tammar wallaby | <i>Macropus eugenii</i> | F | 3 | oral melanoma ⁷ |
| | | — | — | gastric fibropapilloma ²¹ |
| | | — | — | gastric squamous cell carcinoma ¹⁶ |
| Scrub wallaby | <i>Thylogale billardieri</i> | — | — | lymphoid leukemia ³ |
| Whiptail wallaby | <i>Macropus parryi</i> | M | — | Lymphosarcoma/leukemia ³ |
| Parma wallaby | <i>Macropus parma</i> | — | — | mammary adenocarcinoma ³ |
| | | F | — | squamous cell carcinoma-cervix ^{6,9} |
| | | M | — | osteochondroma ²¹ |
| Dorcopsis wallaby | <i>Dorcopsis muelleri</i> | — | — | metastatic carcinoma (lung) ⁴ |
| Common wallaroo | <i>Macropus robustus</i> | — | — | hepatic vascular proliferation/hemangioma ³ |
| | | — | — | metastatic neoplasia ³ |
| | | — | — | chondrosarcoma ¹⁵ |
| Matschie's tree kangaroo | <i>Dendrolagus matschieri</i> | F | 2 | generalized sarcoma ¹⁰ |
| Bennett's tree kangaroo | <i>Dendrolagus bennettianus</i> | — | — | trichoepithelioma ²² |
| Eastern grey kangaroo | <i>Macropus giganteus</i> | M | — | mammary adenocarcinoma hepatoma ¹³ |
| | | F | — | metastatic hemangiosarcoma ³ |
| | | — | — | papilloma ¹⁴ |
| | | — | — | papilloma ¹⁸ |
| Western grey kangaroo | <i>Macropus fuliginosus</i> | — | — | dermal lymphosarcoma ⁴ |
| | | M | — | papilloma of tail ¹⁷ |
| Quokka | <i>Setonix brachyurus</i> | — | — | papilloma of tongue ¹ |
| | | F | 3 | lipomatosis ⁵ |
| Antilopine wallaroo | <i>Macropus antilopinus</i> | — | — | biliary adenocarcinoma ³ |

should be screened for evidence of neoplasia, especially oral squamous cell carcinomas and mammary gland adenocarcinomas.

Acknowledgments: We thank Drs. Margaret Miller, Lanny Pace, L. L. Pittman, Magalie Boucher, John Kreeger, and Alicia Roudabush for their initial evaluation of these cases and the Outback staff, specifically Jacque Blessington, for their care and expertise with the macropod collection at the Kansas City Zoo.

LITERATURE CITED

- Appleby, E. C. 1969. Tumors in captive wild animals: some observations and comparisons. *Acta Zool. Pathol. Antverpiensa* 48: 77–92.
- Canfield, P., T. Bellamy, W. J. Hartley, and D. S. Spielman. 1990. Vasoformative proliferations in a rufous bettong. *Aust. Vet. J.* 67: 334–335.
- Canfield, P. J., and W. J. Hartley. 1992. A survey and review of hepatobiliary lesions in Australian macropods. *J. Comp. Pathol.* 107: 147–167.
- Canfield, P. J., W. J. Hartley, and G. L. Reddacliff. 1990. Spontaneous proliferations in Australian marsupials—a survey and review 1. Macropods, koalas, wombats, possums and gliders. *J. Comp. Pathol.* 103: 135–146.
- Dickson, J., and R. McNeice. 1982. Lipomatosis in a quokka (*Setonix brachyurus*). *Aust. Vet. J.* 58: 218.
- Effron, M., L. Griner, and K. Benirschke. 1977. Nature and rate of neoplasia found in captive wild mammals, birds and reptiles at necropsy. *J. Natl. Cancer Inst.* 59: 185–194.
- Garma-Avina A. 1981. Oral melanoma in a captive wallaby, *Wallabia rufogrisea*. *J. Wildl. Dis.* 17: 409–412.
- Gastinger, W., E. Henschel, and K. Jacob. 1961. Intracranielles blastom bei einem kangaroo (*Macropus rufus*). *Sein Angiographisches und pathologisches Bild. Berl. Munch. Tierärztl. Wochenschr.* 74: 332–337.
- Griner, L. A. 1983. *Pathology of Zoo Animals*. Zoological Society of San Diego, San Diego, California. P. 270.

10. Halloran, P. O. 1955. A bibliography of references to diseases in wild mammals and birds. *Am. J. Vet. Res.* 61(Part 2): 8–19.
11. Kosanke, S. D., D. L. Feeback, and J. M. Jensen. 1979. Oral squamous cell carcinoma in a giant red kangaroo. *J. Am. Vet. Med. Assoc.* 175: 974–976.
12. Loh, R., D. Bergfield, D. Hayes, A. O'Hara, S. Pyecroft, S. Raidal, and R. Sharpe. 2006. The pathology of devil facial tumor disease (DFTD) in Tasmanian devils (*Sarcophilus harrisii*). *Vet. Pathol.* 43: 890–895.
13. Lombard, L. S., and E. J. Witte. 1959. Frequency and types of tumours in mammals and birds at the Philadelphia Zoological Garden. *Cancer Res.* 19: 127–141.
14. McKenzie, R. A., F. R. Fay, and H. C. Prior. 1979. Poxvirus infection of the skin of an eastern grey kangaroo. *Aust Vet. J.* 55: 188–190.
15. Montali, R. J. 1980. An overview of tumours in zoo animals. In: Montali, R.J., and G. Migaki (eds.). *The Comparative Pathology of Zoo Animals*. Smithsonian Institution Press, Washington, D.C. Pp. 531–542.
16. Munday, B. L. 1971. Gastric squamous tumor in the stomach of a pademelon (*Thylogale billardieri*) associated with an infestation with *Labiostrongylus* sp. larvae. *J. Wildl. Dis.* 7: 125.
17. Papadimitriou, J. M., and R. B. Ashman. 1972. A poxvirus in a marsupial papilloma. *J. Gen. Virol.* 16: 87–89.
18. Presedente, P.J.A. 1978. Diseases seen in free-ranging marsupials and those held in captivity. *Proceedings, Course for Veterinarians No. 36*. University of Sydney Post-graduate Committee in Veterinary Science, Sydney, Australia. Pp. 467–471.
19. Ratcliffe, H. L. 1933. Incidence and nature of tumors in captive wild mammals and birds. *Am. J. Cancer* 17: 123.
20. Rungsipipat, A., R. Yamaguchi, N. Naganobu, K. Iwamoto, K. Uchida, S. Tateyama, T. Kurogi, and N. Katayama. 1998. A bone tumor resembling bizarre parosteal osteochondromatous proliferation in a wallaby. *Aust. Vet. J.* 76: 561–564.
21. Schoon, H. A., and W. Murmann. 1985. Zur Pathologie des Digestionstraktes bei Kanguruhs. *Tierarztl. Prax.* 13: 241–253.
22. Speare, R., and D. Banks. 1987. A trichoepithelioma in a wild eastern grey kangaroo (*Macropus giganteus*). *J. Wildl. Dis.* 23: 508–509.
23. Strahan, R. 1995. *Mammals of Australia*. Smithsonian Institution Press, Washington, D.C. P. 353.
24. Wallach, J., and W. J. Boever. 1983. *Diseases of Exotic Animals*. W. B. Saunders Co., Philadelphia, Pennsylvania. P. 600.

Received for publication 7 January 2005