



Estrous Synchronization in Captive Collared Peccaries (Pecari tajacu) using a Prostaglandin F₂ α Analog

Authors: Maia, Keilla Moreira, Peixoto, Gislayne Christianne Xavier, Campos, Lívia Batista, Silva, Andréia Maria da, Castelo, Thibério de Souza, et al.

Source: Zoological Science, 31(12) : 836-839

Published By: Zoological Society of Japan

URL: <https://doi.org/10.2108/zs140112>

BioOne Complete (complete.BioOne.org) is a full-text database of 200 subscribed and open-access titles in the biological, ecological, and environmental sciences published by nonprofit societies, associations, museums, institutions, and presses.

Your use of this PDF, the BioOne Complete website, and all posted and associated content indicates your acceptance of BioOne's Terms of Use, available at www.bioone.org/terms-of-use.

Usage of BioOne Complete content is strictly limited to personal, educational, and non - commercial use. Commercial inquiries or rights and permissions requests should be directed to the individual publisher as copyright holder.

BioOne sees sustainable scholarly publishing as an inherently collaborative enterprise connecting authors, nonprofit publishers, academic institutions, research libraries, and research funders in the common goal of maximizing access to critical research.

Estrous Synchronization in Captive Collared Peccaries (*Pecari tajacu*) Using a Prostaglandin F2 α Analog

Keilla Moreira Maia, Gislayne Christianne Xavier Peixoto, Lívia Batista Campos, Andréia Maria da Silva, Thibério de Souza Castelo, Aracely Rafaelle Fernandes Ricarte, and Alexandre Rodrigues Silva*

Laboratory of Animal Germplasm Conservation - LCGA, Universidade Federal Rural do Semi-Árido - UFERSA, Mossoró, RN, Brazil

We verify the efficiency of a protocol for estrus synchronization in captive female collared peccaries (*Pecari tajacu*) using the prostaglandin analog D-cloprostenol. Five adult female collared peccaries received an intramuscular administration of 60 μ g D-cloprostenol, which procedure was repeated after a 9-day interval. For 10 days after second the D-cloprostenol administration, females were monitored for changes in external genitalia, ovarian ultrasonography, vaginal cytology and reproductive hormonal dosage. As a result, four females synchronized their estrous at 9.5 ± 0.5 days after the second administration of the prostaglandin analog. Such females showed external signs of estrus, including vulvar opening, hyperemic vaginal mucosa, and vaginal mucus, concomitant with an increase in the proportion of superficial cells ($52.2 \pm 9.9\%$) verified through vaginal cytology. An estrogen peak of 22.7 ± 3.4 pg/ml was detected by hormonal dosage, and the presence of anechoic follicles measuring $0.29 \pm 0.05 \times 0.32 \pm 0.07$ mm were detected in the ovary by ultrasonography. Given these findings, we suggest that D-cloprostenol may be effective for use in estrus synchronization in collared peccaries.

Key words: *Tayassu tajacu*, vaginal cytology, ultrasonography, estrous signs, wild pig

INTRODUCTION

The collared peccaries (*Pecari tajacu*) are potential productive species for captive breeding, mainly because its leather is valued on international markets, especially in Europe and the United States (Nogueira and Nogueira Filho, 2011). Such activity could also represent a sustainable alternative for the conservation of the species in the biomes in which its population is declining (Garcia et al., 2009). The role of new breeding techniques would allow the diversification and increase the productivity of the species (Nogueira Filho et al., 2004).

In this sense, estrous synchronization stands out as a method that facilitates the management of the animals and the work of other biotechnologies, such as artificial insemination and embryo transfer (Galina and Orihuela, 2007). For this intent, different pharmacological methods are reported in swine, the domestic animal most closely related to the peccaries (Theimer and Keim, 1998) including the role of progesterin (Wood et al., 1992), gonadotropins (Degenstein et al., 2008), GnRH analogs (Knox et al., 2011), and prostaglandin F2 α (De Rensis et al., 2012). Among these methods, the use of luteolytic agents, such as prostaglandins, is noteworthy as it induces a reduction in progesterone secretion, and promotes the posterior appearance of estrus and

ovulation. The sole use of prostaglandins for synchronization requires that the animals are cycling and have a functional corpus luteum, being dependent of sequential applications (De Rensis et al., 2012).

The female collared peccaries, captive born in semiarid conditions, present an estrous cycle that lasts 21.0 ± 5.7 days, with estrous signs characterized by vulvar lip edema and hyperemic vaginal mucosa, coinciding with developed follicles and high estrogen levels (Maia et al., 2014). No data regarding estrous control, however, is available for this species. We therefore aimed to verify the efficiency of a protocol for estrous synchronization in captive collared peccaries by using a prostaglandin F2 α analog, the D-cloprostenol.

MATERIALS AND METHODS

The ethics committee of the UFERSA, Mossoró, Brazil, approved experimental protocols and animal care practices (Process n° 23091.000250/2011-34). The experimentation was carried during the dry season, from July to August 2010. Five nulliparous female collared peccaries, aging 18 ± 0.4 months, weighing 20.6 ± 1.1 kg were used. The animals belonged to the Center of Multiplication of Wild Animals (CEMAS – UFERSA), located in the north-east of Brazil (Mossoró, RN, Brazil; 5°10'S, 37°10'W). They were maintained under natural photoperiod conditions (~12 h), in paddocks (20 \times 3 m) with a covered area of 3 \times 3 m. The climate is typically semiarid with an annual average temperature of 27°C. The animals were fed with a diet consisting of corn (79.8%), soybean meal (15.4%), wheat bran (1.45%), calcium (2.6%), vitamin (0.2%), and mineral (0.05%) premix, supplemented with tropical fruits, such as melon. Water was provided ad libitum.

For the estrous synchronization, the females were treated with

* Corresponding author. Tel. : +55-84-88571964;
Fax : +55-84-33151778;
E-mail: legio2000@yahoo.com

doi:10.2108/zs140112

two intramuscular injections of 60- μ g D-cloprostenol (Veteglan, Hertape Calier, Belo Horizonte, Brazil) administered at a 9-day interval. The estrous cycles of the animals were monitored every three days, from 15 days prior to the start of the estrous synchronization treatment to the second administration of cloprostenol; after that, the estrus cycles were monitored every two days by blood estrogen dosage, vaginal cytology and ovarian ultrasonography.

For estrous monitoring, animals were physically restrained from 5:00 A.M. to 8:00 A.M. using an appropriate hand net. On each occasion, alterations in the external genitalia were noted and vaginal smears were obtained by introducing a cotton-tipped swab into the caudal vagina. The cells were transferred to a glass slide and stained with a Diff-Quick stain (Instant-Prov[®], Newprov, Pinhais, PR, Brazil). As previously described for peccaries (Mayor et al., 2007a) 200 cells were counted under light microscopy ($\times 400$), and the results were recorded as the proportions of parabasal, intermediate, and superficial cells identified during the estrous cycle.

Blood samples were collected for estrogen dosage by using a commercial kit (Max-Planck-Ring D-21 65 205, Human GmbH, Wiesbaden, Germany) for enzyme-linked immune sorbent assay – ELISA, as previously described for the species (Mayor et al., 2006). The ovaries were evaluated by transabdominal ultrasonography using a 5–7.5 MHz microconvex array transducer and a B-mode, real-time, portable scanner (Aquila vet, Pie Medical[®], Nutricell, Campinas, SP, Brazil). Animals were positioned in lateral recumbence. The abdomen was completely scanned, and the kidneys were identified. Both the ovaries were identified and evaluated for echoic appearance and texture. Identification and measurements of the ovarian structures such as follicles and corpora lutea were conducted. Images were stored for further analysis.

Numeric results were expressed as mean and standard error (SEM), using the “proc print” procedure of the Statistical Analysis System, version 6.10 (SAS).

RESULTS

In the beginning of the experiment, when the first D-cloprostenol dose was administered, two animals were identified as being in the luteal phase, and the other three females were in the follicular phase. After eight days, we observed an estrogen peak, 29.9 ± 5.9 pg/ml, in the two females that were previously in the luteal phase. These females also presented external signs of estrus, such as hyperemic vulva.

Subsequently, the second administration of cloprostenol (day 9), all the animals presented an estrogenic peak about 9.5 ± 0.5 days (Table 1 and Fig. 1). Of those individuals, four females (80%) presented with the external signs of estrus, such as vulvar opening, hyperemic vaginal mucosa (Fig. 2A), and the presence of vaginal mucus (Table 1). The presence of parabasal, intermediate, and superficial cells was identified in all vaginal smears, but no basal cells were observed at any time, with a brief predominance of superficial cells during estrus (52.2%) (Table 2). Through ultrasonography, ovarian follicles (Fig. 2B)

were identified in the four animals that showed external estrous signs. These follicles were regular circular structures containing anechoic fluid, sometimes projected onto the sur-

Table 1. Characteristics of the synchronized estrous cycle of collared peccaries (*Pecari tajacu*; $n = 5$).

Animal	Day of estrogen peak after second PGF-2 α administration	Values for estrogen peak (pg/mL)	Estrous signals	
			Hyperemic vulva	Vaginal mucus discharge
1	10	23.53	+++	+++
2	8	31.05	+	+++
3	10	21.63	++	+++
4*	8	20.11	–	–
5**	10	14.53	+++	+++
Means \pm SEM	9.5 \pm 0.5	22.7 \pm 3.4		

* Animal 4 did not presented external estrous signs and its data were not included in the means

** Animal 5 also presented vulvar opening

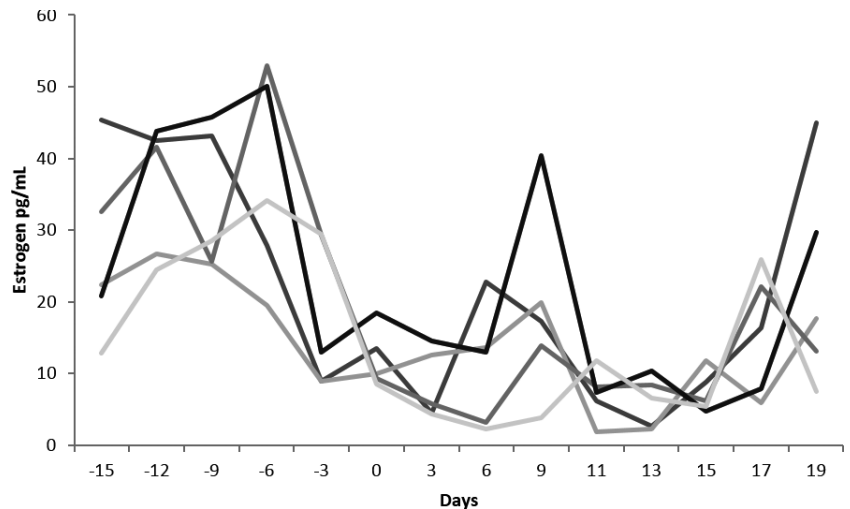


Fig. 1. Values for blood serum estrogen (pg/mL) verified during the estrous cycles of collared peccary (*Pecari tajacu*) females ($n = 5$) submitted to an estrous synchronization protocol using D-cloprostenol administered at day 0 and 9.

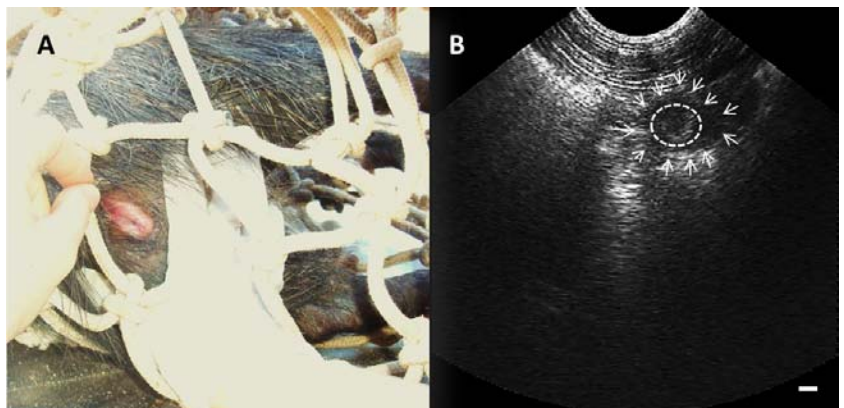


Fig. 2. Estrous signs in collared peccary (*Pecari tajacu*). (A) vulvar opening and hyperemic vaginal mucosa; (B) sonogram of an ovary (white arrows) presenting the pre-ovulatory follicle (ellipsoid).

Table 2. Relative proportions of the cell types found in vaginal cytology and follicular diameter monitored by ultrasonography verified during the serum estrogen peak of female collared peccaries (*Pecari tajacu*) ($n = 5$) submitted to estrous synchronization using D-cloprostenol.

Animal	Vaginal Cytology (%)			Ultrasonography
	Parabasal	Intermediate	Superficial	Follicular Diameter (cm)
1	45	25	30	0.4 × 0.4
2	22	15	63	0.3 × 0.5
3	25	33	42	0.2 × 0.2
4*	51	26	23	–
5	15	11	74	0.2 × 0.2
Means ± SEM	26.8 ± 6.4	21.0 ± 4.9	52.2 ± 9.9	0.3 ± 0.1 × 0.3 ± 0.1

* Animal 4 did not presented external estrous signs and its data were not included in the means

face of the ovary (Table 2).

DISCUSSION

To the best of our knowledge, this is the first study to describe successful estrus synchronization in collared peccaries. We affirmed that some animals (2/5) presented estrous signs after eight days in response to the first prostaglandin administration. In agreement with the results of hormonal monitoring, two of these individuals were in the luteal phase, demonstrating a functional corpus luteum at ultrasonography, which is clearly responsible for luteolytic agents as the cloprostenol (De Rensis et al., 2012).

Once the luteal phase of the estrous cycle of peccaries usually lasts 15 days on average (Maia et al., 2014), a second prostaglandin administration is recommended in order to promote the lysis of corpora luteum that were not formed in first occasion. The second administration was conducted after nine days, enough time for the formation of a new corpora luteum in those females that were in follicular phase in the initial moment.

Four animals presented estrous signs at 9.5 days after the second administration of cloprostenol. These effects suggest that peccaries show a late response to this drug as reported in swine. In such domestic species, a single PGF2 α administration does not induce complete luteolysis before day 12 of the estrous cycle. In fact, the literature reports several factors indicating refractoriness of the early corpus luteum in swine to the effects of a luteolytic dose of PGF2 α , including lack of expression of PGF2 α receptors and the presence of the PGF2 α catabolizing enzyme, 15-hydroxyprostaglandin dehydrogenase (PGDH). In addition, changes in blood flow, alteration in gene expression (VEGF, eNOS, angioprotein, angiotensin, endothelin, CAMKK2, HINT1, YWHAZ, GNB1 and RGS2), and in NO and pO₂, may also affect the luteolytic effects of PGF2 α in a recently formed swine CL (Rensis and Lopez-Gatius, 2007).

Approximately nine days after the second administration of cloprostenol, peccaries showed the estrogenic peak with mean values of 22.7 ± 3.4 pg/ml. Interestingly, the Animal 5 showed the lowest values for estrogen peak (14.5 pg/ml), but it was the one that established the most evident estrous signs, including the opening of the vulva lips. Also of note, the average values found for estrogen peak during synchro-

nized estrous were lower than those described for a similar group of captive individuals during natural estrous, 55.6 pg/mL (Maia et al., 2014). Such differences could probably be associated with a variation among different individuals.

The changes verified in the external genital organ of four females during the synchronized estrus were similar to those previously reported, during natural estrous by newly captured peccaries in the Amazon forest (Mayor et al., 2007b). In domestic sows, these external changes occur as a response to the high concentrations of estradiol that promotes increased vascularization and blood flow, increased uterine tone and mucus secretion (Bortolozzo et al., 2005). Moreover, the predominance of superficial cells (52.2%) during the estrogen peak was observed in the present synchronized females, as also reported for females under natural estrous (Mayor et al., 2007b).

In domestic swine, it was previously found that administration of 500 μ g of cloprostenol induced earlier ovulation in PMSG/hCG treated prepubertal gilts (Srikandakumar and Downey, 1989). The body weight of female sows (> 100 kg) is, in general, larger than the females collared peccary (~20 kg) (Bortolozzo et al., 2005), the prostaglandin dose for peccaries was drastically reduced for 60 μ g in double administration. However, it is necessary to emphasize that there are marked differences in reproductive physiology between swine and peccary. For instance, the mean ovulation rate in the collared peccaries was estimated at 2.3 follicles (Mayor et al., 2006), which is very low compared to that in domestic swine (10–24 follicles). The low mean ovulation rate of the collared peccary may act as a biological limit for the abundance of the species, because the females bear a litter size of 1.7–1.9 fetuses or newborns (Mayor et al., 2005). Furthermore, the ovarian population of a female collared peccary is ~60,000 follicles (Lima et al., 2013), which is closely related to that in caprines (Lucci et al., 1999), than swine ~420,000 follicles (Gosden and Telfer, 1987).

Generally, the response to the estrous synchronization treatment in other mammals occurs at 38–78 h after the administration of the prostaglandin (Vazquez et al., 2010); peccaries, however, only showed estrous signs at 9.5 days after the second application of the drug. Tentatively, a role for a higher D-cloprostenol dose could be proposed for reducing the time for estrus synchronization in peccaries. In fact, when beef heifers received 100 μ g cloprostenol, they showed signs of estrous after 88.8 ± 13.4 h, but when the same animals received major doses of 250 and 500 μ g, the time for estrous signs manifestation was reduced to 57.6 ± 6.9 and 56 ± 7.3 h, respectively (Colazo et al., 2002).

In the present study, we had to use a smaller number of animals due to ethical recommendations, since the procedure of repetitive restraint for estrous monitoring is very stressful and sometimes harmful for the individuals. In fact, it is known that the stress, as a consequence of management practices, could negatively interfere with the dynamics of the peptides and steroidal hormones involved in reproductive function (Dobson et al., 2003). Thus, a possible negative influence of stress on the synchronized estrous manifestation cannot be ruled out, and the development of better restraint methods for collared peccaries is required.

Finally, we suggest that the double administration of

60 µg of D-cloprostenol, a synthetic analogue of prostaglandin, with a 9-day interval, promoted a late, but effective estrus synchronization in captive collared peccaries. In spite of the difficulties of using a great number of individuals, further studies are suggested in order to apply these results in captive breeding at a large scale.

REFERENCES

- Bortolozzo FP, Uemoto DA, Bennemann PE, Pozzobon MC, Castagna CD, Peixoto CH, et al. (2005) Influence of time of insemination relative to ovulation and frequency of insemination on gilt fertility. *Theriogenology* 64: 1956–1962
- Colazo MG, Martinez MF, Kastelic JP, Mapletoft RJ (2002) Effects of dose and route of administration of cloprostenol on luteolysis, estrus and ovulation in beef heifers. *Anim Reprod Sci* 72: 47–62
- Degenstein KL, O'Donoghue R, Patterson JL, Beltranena E, Ambrose DJ, Foxcroft GR, Dyck MK (2008) Synchronization of ovulation in cyclic gilts with porcine luteinizing hormone (pLH) and its effects on reproductive function. *Theriogenology* 70: 1075–1085
- De Rensis F, Saleri R, Tummaruk P, Techakumphu M, Kirkwood RN (2012) Prostaglandin F_{2α} and control of reproduction in female swine: A review. *Theriogenology* 77: 1–11
- Dobson H, Ghuman S, Prabhakar S, Smith R (2003) A conceptual model of the influence of stress on the female reproduction. *Reproduction* 125: 151–163
- Galina CS, Orihuela A (2007) The detection of estrus in cattle raised under tropical conditions: What we know and what we need to know. *Horm Behav* 52: 32–38
- Garcia AR, Kahwage PR, Ohashi OM (2009) Aspectos reprodutivos de caititus (*Tayassu tajacu*). *Rev Bras Reprod Anim, Belo Horizonte* 33: 71–81
- Gosden RG, Telfer E (1987) Numbers of follicles and oocytes in mammalian ovaries and their allometric relationships. *J Zool (Lond)* 211: 169–175
- Knox RV, Willenburg KL, Rodrigues-Zas RL, Greger DL, Hafs HD, Swanson ME (2011) Synchronization of ovulation and fertility in weaned sows treated with intravaginal triptorelin is influenced by timing of administration and follicle size. *Theriogenology* 75: 308–319
- Lima GL, Santos EAA, Luz VB, Rodrigues APR, Silva AR (2013) Morphological characterization of the ovarian preantral follicle population of collared peccaries (*Tayassu tajacu* Linnaeus, 1758). *Anat Histol Embryol* 42: 304–311
- Lucci CM, Amorim CA, Rodrigues APR, Figueiredo JR, Bão SNB, Silva JRV, Gonçalves PBD (1999) Study of preantral follicle population in situ and after mechanical isolation from caprine ovaries at different reproductive stages. *Anim Reprod Sci* 56: 223–236
- Maia KM, Peixoto GCX, Campos LB, Bezerra JAB, Ricarte ARF, Moreira N, et al. (2014) Estrus cycle monitoring of captive collared peccaries (*Pecari tajacu*) in semiarid conditions. *Pesq Vet Bras* (in press)
- Mayor P, Lopez-Gatius F, Lopez-Bejar M (2005) Integrating ultrasonography within the reproductive management of the collared peccary (*Tayassu tajacu*). *Theriogenology* 63: 1832–1843
- Mayor P, Guimarães DA, Lopez-Gatius F, Lopez-Bejar M (2006) First postpartum estrus and pregnancy in the female collared peccary (*Tayassu tajacu*) from the amazon. *Theriogenology* 66: 2001–2007
- Mayor P, Guimarães DA, Le Pendu Y, Silva JV, Jori F, Lopez-Bejar M (2007a) Reproductive performance of captive collared peccaries (*Tayassu tajacu*) in the eastern Amazon. *Anim Reprod Sci* 102: 88–97
- Mayor P, Galvez H, Guimarães DA, Lopez-Gatius F, Lopez-Bejar M (2007b) Serum estradiol-17 beta, vaginal cytology and vulval appearance as predictors of estrus cyclicity in the female collared peccary (*Tayassu tajacu*) from the eastern Amazon region. *Anim Reprod Sci* 97: 165–174
- Nogueira Filho S, Nogueira S, Mendes A, Jori F (2004) A large scale commercial farming of collared peccary (*Tayassu tajacu*) in North Eastern Brazil. *Game Wildl Sci* 21: 413–420
- Nogueira SSC, Nogueira-Filho SLG (2011) Wildlife farming: an alternative to unsustainable hunting and deforestation in neotropical forests? *Biodivers Conserv* 20: 1385–1397
- Rensis F, Lopez-Gatius F (2007) Protocols for synchronizing estrus and ovulation in buffalo (*Bubalus bubalis*): A review. *Theriogenology* 67: 209–216
- Srikandakumar AD, Downey BR (1989) Induction of ovulation in gilts with cloprostenol. *Theriogenology* 32: 445–9
- Theimer TC, Keim P (1998) Phylogenetic relationships of peccaries based on mitochondrial cytochrome B DNA sequences. *J Mammol* 79: 566–572
- Vazquez MI, Blanch MS, Alanis GA, Chaves MA, Gonzalez-Bulnes A (2010) Effects of treatment with a prostaglandin analogue on developmental dynamics and functionality of induced corpora lutea in goats. *Anim Reprod Sci* 118: 42–47
- Wood CM, Kornegay ET, Shipley CF (1992) Efficacy of altrenogest in synchronizing estrus in two swine breeding programs and effects on subsequent reproductive performance of sows. *J Anim Sci* 70: 1357–1364

(Received May 23, 2014 / Accepted August 11, 2014)