

Effects of Follicle-Stimulating Hormone Administration on Oestradiol-Induced Cystic Ovaries in Guinea Pigs

Authors: Champion, Christine E., Trewin, Amanda L., and Hutz, Reinhold J.

Source: Zoological Science, 13(1) : 137-142

Published By: Zoological Society of Japan

URL: <https://doi.org/10.2108/zsj.13.137>

BioOne Complete (complete.BioOne.org) is a full-text database of 200 subscribed and open-access titles in the biological, ecological, and environmental sciences published by nonprofit societies, associations, museums, institutions, and presses.

Your use of this PDF, the BioOne Complete website, and all posted and associated content indicates your acceptance of BioOne's Terms of Use, available at www.bioone.org/terms-of-use.

Usage of BioOne Complete content is strictly limited to personal, educational, and non - commercial use. Commercial inquiries or rights and permissions requests should be directed to the individual publisher as copyright holder.

BioOne sees sustainable scholarly publishing as an inherently collaborative enterprise connecting authors, nonprofit publishers, academic institutions, research libraries, and research funders in the common goal of maximizing access to critical research.

Effects of Follicle-Stimulating Hormone Administration on Oestradiol-Induced Cystic Ovaries in Guinea Pigs

Christine E. Champion¹, Amanda L. Trewin
and Reinhold J. Hutz²

Department of Biological Sciences, University of Wisconsin-Milwaukee,
P.O. Box 413, Milwaukee, Wisconsin 53201, USA

ABSTRACT—A consistent defect in follicle-stimulating hormone (FSH) secretion is seen in humans with Polycystic Ovarian Syndrome (PCOS); therefore, we evaluated whether Metrodin (a highly purified urinary FSH) administration concurrent with cyst induction or following cyst induction inhibits estrogen-induced cyst development and augments ovarian follicular growth in an established guinea pig model. All animals in these studies received subcutaneous implants containing oestradiol-17 β (E₂)-filled Silastic capsules for a 48-hour period. Guinea pigs in study #1 were administered four 0.25 ml injections of FSH or placebo at twelve-hour intervals simultaneously with the E₂ treatment; guinea pigs assigned to study #2 were administered four 0.25 ml injections of FSH or placebo at twelve-hour intervals following the induction of the cystic condition by E₂. Exogenous FSH appears to negate cyst formation when superimposed upon the cyst-inducing agent (E₂). Further, treatment with FSH augmented the number of mid-sized follicles in both paradigms. This study is the first to establish evidence of an anti-cystic effect of FSH in an animal model.

INTRODUCTION

Polycystic Ovarian Syndrome (PCOS) is a condition in which ovarian follicles are transformed into follicular cysts. Since the syndrome affects approximately five percent of the female human population (Barbieri, 1991), it is the most common ovarian disorder of women (Pache *et al.*, 1991). It has been postulated that PCOS is a self-perpetuating cycle in which elevated androgens from the ovary are converted to estrogens in adipose tissue causing inhibition of follicle-stimulating hormone (FSH) release from the anterior pituitary gland; thereby increasing the luteinizing hormone (LH) to FSH ratio (Neyro *et al.*, 1991). Most treatment regimens for PCOS in human females attempt to correct the low concentrations of FSH. In the current studies, we will assess the effects of FSH at the level of the polycystic ovary in an animal model, the guinea pig.

Due to the complicated nature of PCOS, animal models must be utilized to study its etiology and development. It has been well documented that a cystic condition can be induced in various animal models. The rat has been used as the primary model for the study of PCOS. In the rat, the syndrome can be induced by exposing the animals to continuous light (Baldissera *et al.*, 1991) or by hormonal treatment with estradiol-17 β (E₂) (Brawer *et al.*, 1986),

androgen (Carriere *et al.*, 1989; Convery *et al.*, 1990), or human chorionic gonadotropin (Bogovich, 1989). However, because the rat does not have a functional luteal phase, its cycle is not remotely similar to the primate menstrual cycle. Although the monkey most resembles the human both morphologically and functionally with respect to reproductive processes, we have not been able in non-human primates (NHP) to consistently induce ovarian cysts that persist (Dierschke *et al.*, 1987); therefore, NHPs cannot yet serve as a practical model. As the guinea pig exhibits cyclic and luteal phase similarities to the human, and cystic ovaries have been induced consistently (Quandt and Hutz, 1993), the guinea pig is the proposed model for the study of PCOS.

The current study is unique because the effects of FSH can be studied *in vivo* with an induced cystic condition (Quandt and Hutz, 1993). The purpose of this study, then, was to assess the role of FSH in preventing the E₂-induced cystic ovarian condition in the guinea pig (Quandt and Hutz, 1993). We further assessed the role of FSH in ameliorating the cystic ovarian condition once the syndrome has been initiated.

MATERIALS AND METHODS

Animals

Mature, healthy guinea pigs (*Cavia porcellus*) of homogeneous stock (Hartley-albino) weighed at least 500 g and were at least five months of age when studied. Monitoring estrous cycles by analysis of vaginal smears allowed us to choose for the study only animals showing normal, consistent 13–18 day cycle lengths. This five-day range allowed for the common variabilities observed in cycle length among animals; experimental animals showed consistent cycle

Accepted December 11, 1995

Received August 28, 1995

¹ Present Address: Department of Physiology, Animal Reproduction and Biotechnology Laboratory, Colorado State University, Fort Collins, Colorado 80523, USA.

² To whom correspondence should be addressed.

lengths within each animal prior to treatment (15.8 ± 1.3 [mean \pm SD], $n=18$). The day that maximal cornification was observed in the vaginal smears was designated as Day 0, the day of ovulation. Days of the estrous cycle followed thereafter consecutively.

Experimental procedure

This protocol was reviewed and approved by the Animal Care and Use Committee at the University of Wisconsin-Milwaukee. Guinea pigs in study #1 received injections of either FSH or placebo concurrent with an E_2 regimen that is known to induce cystic ovaries in guinea pigs (Quandt and Hutz, 1993). Animals in study #2 received injections of FSH or placebo after the induction of the cystic condition by E_2 .

Guinea pigs in study #1 received four subcutaneous (sc) E_2 -filled Silastic capsule implants (Dierschke *et al.*, 1985) in the upper dorsal integument for a 48-hour period, beginning on Day 12 of the cycle. Beginning at the time of capsule implantation, four 0.25 ml intramuscular (IM) injections of either placebo (phosphate-buffered saline) or Metrodin (Serono Pharmaceuticals, Inc., Norwell, MA; total 50 IU) in placebo were given at 12-hour intervals. The total dosage of 50 IU of FSH was based on dosages that were previously used in Rhesus monkey (Hutz *et al.*, 1991); however, the dose was scaled for the mass of a guinea pig. The Silastic implants were removed after the 48-hour incubation period. Blood was obtained throughout the procedure (Table 1) by cardiac puncture. The animals were monitored daily for atypical cycles and were sacrificed once two criteria were met: (1) At least 56 days passed from the time of Silastic capsule implantation, as this length of time allowed for the development of ovarian cysts in guinea pigs previously (Quandt and Hutz, 1993); and (2) at least one cycle after treatment with E_2 and FSH or placebo deviated from the normal 13-18 day range of cycle lengths. Animals were euthanized on Day 10 of the cycle an average of 109 days following E_2 -capsule implantation. (Cysts were observed superficially and in histologic sections in previous studies by this time.)

Animals assigned to study #2 received injections of FSH or placebo following the induction of the cystic condition. The cystic condition was induced in the same manner as described for study #1. Since cysts were observed 109 days after E_2 treatment, animals in study #2 received four 0.25 ml IM injections of FSH (total 50 IU) or placebo at 12-hour intervals beginning on Day 11 of the cycle following the 109th day after E_2 -capsule implantation. The injections administered to animals in study #2 were initiated an average of 118 days following E_2 treatment. Following the injections, animals were monitored throughout the completion of that estrous cycle and were euthanized on Day 10 of the subsequent cycle. All animals in these experiments were sacrificed by ether anesthesia and decapitation.

All animals were sacrificed on Day 10 of the cycle to normalise the cycles and to allow for proper inter-animal tissue comparisons. Post-mortem trunk blood was collected to allow hormonal measurements at sacrifice. Ovaries were removed and fixed at necropsy and processed for histologic analysis. All blood collected during the course of the study was centrifuged in serum separator tubes and serum was stored at -20°C until assayed for E_2 .

Histology

After excision, the ovaries were cleaned of excess tissue. Ovaries were then placed in Bouin's fixative for 72 hours at 4°C , followed by 70% ethanol at 4°C until further processing. Processing of the tissue involved dehydrating the tissue by immersing it in a series of increasing ethanol concentrations followed by either immersion in xylene (study #1) or Hemo-de (study #2, a non-xylene-based infiltrant, Fisher Scientific, Chicago, IL). The processed ovaries were infiltrated with paraffin. Each ovary was sectioned completely at a thickness of $10\ \mu\text{m}$. Serial sections were placed on slides and stained with hematoxylin and eosin. Microscopic analysis of all serial sections consisted of counting, sizing, and classifying

follicles as described previously (Quandt and Hutz, 1993). In brief, healthy follicles were placed into one of three size categories based on the greatest diameter: $<200\ \mu\text{m}$, $201\text{--}500\ \mu\text{m}$, and $>500\ \mu\text{m}$. Atretic follicles, defined by the presence of pyknotic nuclei in 5% or more of the granulosa cells (Byskov, 1974) and/or complete implosion of the follicle with loss of the oocyte, were excluded from further analysis.

Radioimmunoassays

Radioimmunoassay kits were supplied by Diagnostic Products Corporation (Los Angeles, CA). The kits for assay of human serum were validated for E_2 in guinea pig serum by demonstration of parallelism between samples in serial dilution versus the authentic standards (Hutz *et al.*, 1990). Assayed serum from each kit was analysed for bound radiolabeled hormones using a Cobra II Gamma Counter (Packard Instruments). The interassay variation for the three E_2 kits was 17.4%; the intra-assay coefficients of variation were 8.0%, 6.0%, and 5.7%. The sensitivity of the standard curve was 20 pg/ml of serum.

Statistical analysis

Independent *t*-tests were used for all histologic analyses. All of these data were normalised by calculating the number of follicles or cysts per ovary. Because two ovaries were removed and analysed from each animal studied, the values were averaged and one datum was designated per ovary for each animal as a per-ovary value. An α -level of 0.05 was considered to be statistically significant. Nonparametric methods were applied to the data collected from the radioimmunoassays as these data did not show homogeneity of variance. In these cases, we used a Friedman's test followed by a Wilcoxon signed-rank test to analyse for individual differences (Zar, 1974). Endocrine data for the placebo- and FSH-treated animals in study #2 were pooled, as no treatment differences were observed; the statistical analysis, therefore, evaluated the timing of blood collection. Each "n" value is equal to the number of animals sampled when referring to endocrine data and is equal to the number of ovary pairs for all histologic data. No outliers were removed from either the histologic or the endocrine data. SYSTAT: The System for Statistics was used to assist the evaluator with large data sets (Wilkinson, 1990).

RESULTS

Ovarian morphology

Treatment with E_2 caused induction of cysts within the guinea pig ovary. The cross-section of a cystic ovary from a guinea pig treated simultaneously with E_2 and placebo is depicted in Fig. 1A. Cystic follicles were easily identifiable. Fig. 1B allows for comparison of healthy and cystic follicles at a higher magnification.

Follicle quantitation

Treatment with FSH reduced the number of cystic follicles per ovary when injections were superimposed upon E_2 -capsule implantation (study #1): 4.1 ± 1.8 ($n=4$), 12.7 ± 3.7 ($n=4$) respectively (Fig. 2A). In study #2, the number of cystic follicles observed in FSH-treated animals following E_2 administration and cyst development was not statistically different from the number of cystic follicles observed in placebo-treated animals following E_2 administration. Though not significant, the FSH-treated guinea pigs did show a six-fold reduction in average number of cysts per ovary compared to the placebo-treated group (0.5 ± 0.3 ($n=5$), 3.3 ± 2.2 ($n=5$))

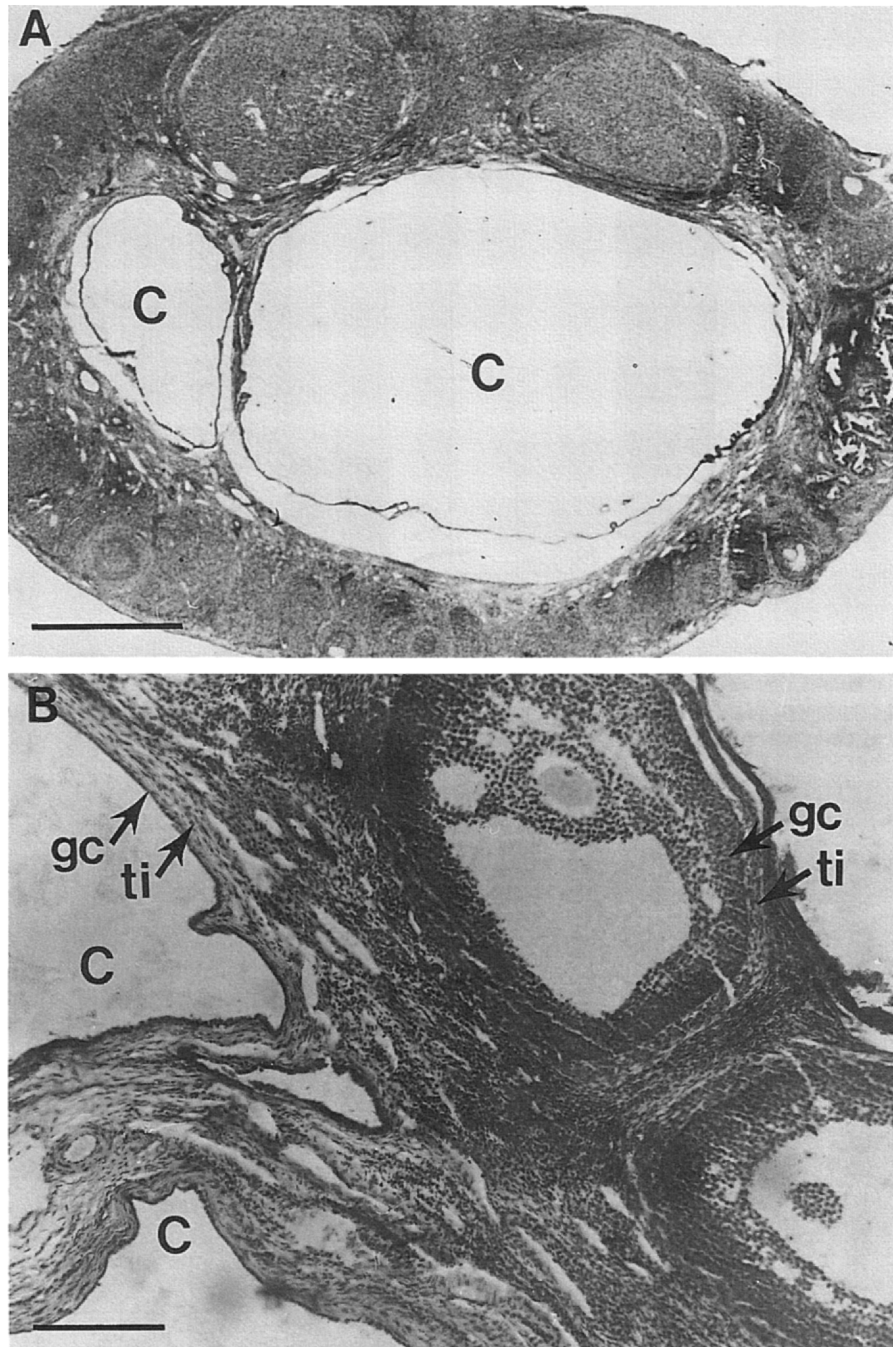


Fig. 1. Cystic guinea pig ovary in cross section. (A) Two large cystic follicles (c) are seen in this section of the E₂-induced cystic condition. (bar=1 mm). (B) Two cystic follicles and two healthy follicles are juxtaposed in cross section of a guinea pig ovary (bar=100 μ m). The healthy follicles contain several layers of granulosa cells (gc) and dense layers of internal thecal layer (ti), whereas the cystic follicles are characterized by two layers of gc and disordered ti.

(Fig. 3A).

Significant differences in the number of healthy mid-sized follicles (201–500 μ m in diameter) with FSH treatment were observed in both studies. Animals treated concurrently with E₂ and FSH had a greater number of healthy mid-sized follicles per ovary than animals treated concurrently with E₂ and placebo (29.3 \pm 6.3 (n=4) vs. 8.1 \pm 1.6 (n=4)) (Fig. 2B). Animals treated with FSH injections after cyst induction also

showed a significantly greater number of healthy mid-sized follicles per ovary than those treated with placebo after cyst induction (24.8 \pm 5.1 (n=5), 11.9 \pm 1.5 (n=5)) (Fig. 3B).

Animals receiving concurrent E₂ and placebo showed 29.7 \pm 10.0 small, healthy follicles (<201 μ m in diameter) per ovary (n=4) while animals receiving concurrent E₂ and FSH showed 51.0 \pm 15.1 small, healthy follicles per ovary (n=4). However, these differences were not statistically significant.

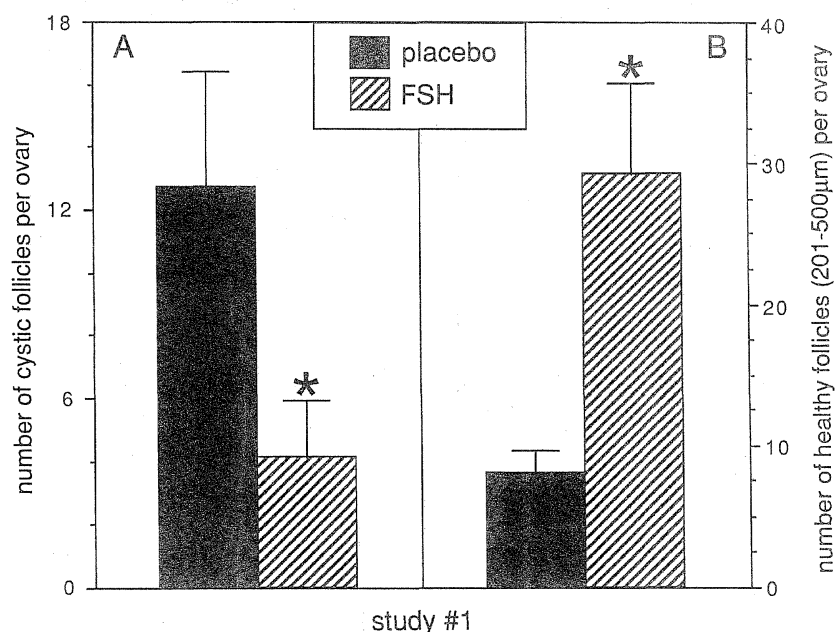


Fig. 2. Changes in the number of cystic follicles (A) and medium-sized healthy follicles (B) per ovary in animals treated concurrently with E_2 and placebo/FSH. Asterisks denote significantly reduced numbers of cystic ovarian follicles in guinea pigs receiving FSH and E_2 concurrently (A) and significantly greater numbers of healthy mid-sized follicles in guinea pigs treated simultaneously with E_2 and FSH (B). Statistical analysis was done with independent *t*-test (mean \pm SEM, $p < 0.05$, $n = 4$ animals per treatment).

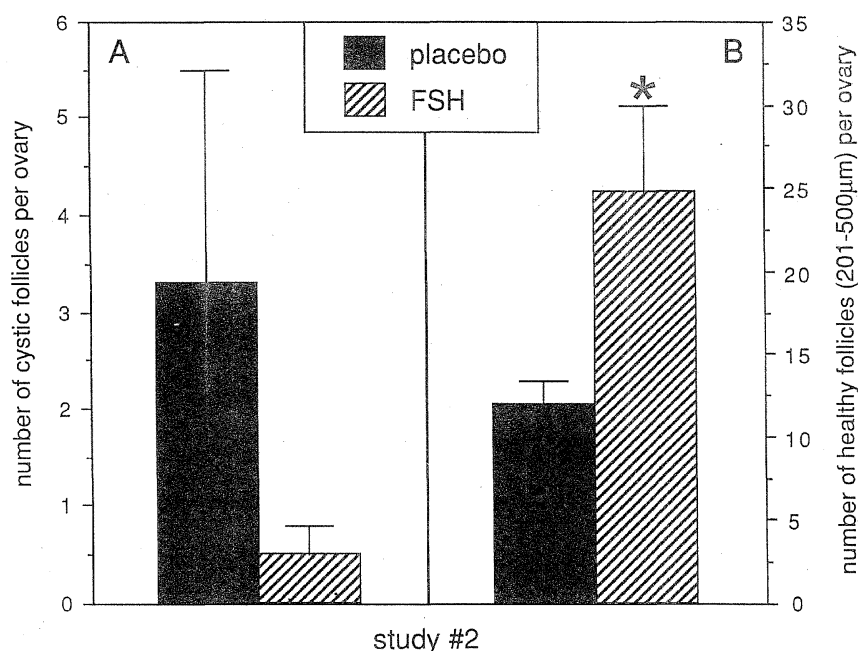


Fig. 3. Changes in the number of cystic follicles (A) and medium-sized healthy follicles (B) per ovary in animals that were given injections of either placebo or FSH subsequent to treatment with E_2 . No significant difference in the number of cystic follicles was observed per ovary in each treatment group (A). As denoted by an asterisk, animals receiving FSH injections showed a significantly greater number of medium-sized healthy follicles than did the placebo-treated animals. Statistical analysis was done with independent *t*-test (mean \pm SEM, $p < 0.05$, $n = 5$ animals per treatment).

Significant differences in the number of small, healthy follicles were observed in ovaries from animals that received FSH versus placebo injections following the induction of cysts (55.4 ± 12.0 ($n = 5$), 28.4 ± 6.2 ($n = 5$), respectively).

Endocrinology

Radioimmunoassay of serum samples that were collected throughout the study confirmed the release of E_2 from the E_2 -containing Silastic capsules implanted sc into each

animal. RIA values obtained from placebo and FSH treatments were pooled (since no significant differences were evident) and analysed. Serum E₂ concentrations were the lowest prior to treatment. Following the implantation of the E₂-capsules, serum E₂ concentrations rose significantly. Serum E₂ concentrations returned to and remained at low concentrations after the removal of the E₂ capsules (Table 1).

Table 1. Changes in serum concentrations of oestrogen following administration of E₂ sc

Schedule of blood collection	Serum E ₂ (pg/ml)
control	217.3± 63.6 (n=11) ^a
2 hours following capsule implantation	1473.8±428.1 (n=11) ^{b,c}
2 days following E ₂ administration	1425.3±270.4 (n=11) ^{b,c}
2 hours following capsule removal	1482.0±344.8 (n=11) ^{b,c}
2 days following capsule removal	835.0±420.7 (n=11) ^b
before first injection of placebo/FSH	143.9± 80.3 (n=11) ^a
2 hours following first injection	325.8±115.3 (n=11) ^{a,b}
2 days following first injection	176.8± 53.7 (n=11) ^a
post-mortem	153.6± 31.0 (n=11) ^a

^{a,b,c}Superscripts that do not contain a common letter denote significance. The data set was analysed with a Friedman's non-parametric test followed by a Wilcoxon signed-rank test (mean±SEM, p<0.05).

DISCUSSION

We have demonstrated previously that sc implantation of E₂-filled Silastic capsules for a 48-hour period induced a cystic condition in the ovaries of guinea pigs (Quandt and Hutz, 1993). Here we report on the anti-cystic effects of FSH at the level of the ovary in this model for PCOS. Animals in study #1 received injections of Metrodin or placebo simultaneously with a cyst-inducing regimen of E₂; we determined that the detrimental effects of E₂ could be negated by the concurrent administration of FSH. Animals in study #2 received injections subsequent to the induction of cysts by the E₂ regimen (Quandt and Hutz, 1993); and we determined that FSH could ameliorate some signs of the cystic ovarian condition.

The decreased number of ovarian cysts present in guinea pigs from study #1 showed that FSH, when superimposed upon E₂, was able to reduce the induction of cysts by E₂. We presume that FSH is inhibited by E₂ in our model, but as yet we have not consistently measured peripheral changes in FSH or LH concentrations. However, we suggest that our model is similar to the ovariectomised primate. In the latter model, FSH is suppressed by E₂ to concentrations similar to those of an intact primate in the mid- to late-follicular phase (Basset and Zeleznik, 1990). In our model, the concentrations to which FSH is suppressed are probably too low to support folliculogenesis and thus induce the formation of cysts. However, when FSH is injected with the E₂ regimen, folliculogenesis is allowed to continue as it would normally.

The number of small healthy follicles observed in

ovarian histologic sections was not significantly different between treatment groups in study #1. However, early treatment with FSH did cause an increase in the number of healthy mid-sized follicles (201–500 µm in diameter). Healthy mid-sized follicles typically continue to develop into ovulatory follicles. The FSH treatment presumably does not affect the number of medium-sized follicles directly since ovary collection occurred more than 100 days following FSH treatment. However, perhaps the inhibition of cyst development induced by FSH indirectly augmented folliculogenesis. Both increased cyst development and decreased numbers of mid-sized follicles were observed in the ovaries of the placebo-treated animals.

When FSH injections were administered after cysts had already been induced (study #2), no reduction in cyst number was observed; therefore, FSH did not improve an already-present cystic condition. However, note that the mean cyst number is six-times greater in the placebo-treated group than in the FSH-treated group. It appears that FSH may be exerting an anti-cystic effect even once the condition is induced, but we cannot yet statistically verify this due to the great variability within these data. Overall, this is the first evidence for an anti-cystic effect of FSH.

The treatment of animals with FSH in study #2 caused a significant increase in the number of small healthy follicles. This FSH-treatment regimen also caused an increase in the number of healthy mid-sized follicles (201–500 µm in diameter). This demonstrated short-term effects of FSH since the treatment with the gonadotropin occurred during the cycle just prior to euthanasia. It is likely that FSH allowed for the recruitment of healthy follicles since FSH is the major signal for the stimulation of follicular recruitment (Fortune, 1994). However, it is also possible that FSH caused its effects by decreasing the incidence of atresia in the follicles that were already present. In this model, the FSH treatment might rescue developing follicles from becoming cysts and thereby allow them to continue to develop. As with FSH therapy in humans and other animals, FSH therapy in the guinea pig allowed for the negation of these effects and permitted an increased number of medium-sized follicles (Mizunuma *et al.*, 1992).

These studies suggest that exogenous FSH negates cyst formation when superimposed upon the cyst-inducing agent (E₂) and may even act to decrease cyst number when cysts have developed. Treatment with FSH does alleviate some clinical signs associated with the ovarian cysts in our E₂-induced model and augments development of follicles in certain size classes. A decrease in FSH secretion via E₂-induced feedback inhibition is likely to play a major role in the decreased number of healthy follicles in the polycystic ovaries of these guinea pigs.

ACKNOWLEDGMENTS

The authors would like to thank Julie Waraksa, Keith Chipman, Cheryl Fischer, and Carol Plankenhorn for their overall assistance

with animal care; and Sandra Ramirez for her contribution in the area of tissue preparation for histologic analysis. We would also like to thank Ares Services S.A., a member of the Ares Serono group of companies. We also extend our appreciation to the Department of Physiology at Colorado State University for some computer use in the preparation of this manuscript. This research was supported by Ares Services S. A., a member of the Ares-Serono group of companies; a Sigma X: Grant-in-Aid of Research; the Graduate School and the College of Letters and Science at the University of Wisconsin-Milwaukee.

REFERENCES

- Baldissera SF, Motta LDC, Almeida MC, Antunes-Rodrigues J (1991) Proposal of an experimental model for the study of polycystic ovaries. *Braz J Med Biol Res* 24: 747–751
- Barbieri RL (1991) Polycystic ovarian disease. *Ann Rev Med* 42: 199–204
- Basset SJ, Zeleznik AJ (1990) Acute suppression of FSH secretion by oestradiol in the ovariectomized rhesus monkey. *J Reprod Fert* 88: 441–446
- Bogovich K (1989) Induction of ovarian cysts in progesterone-synchronized immature rats: Evidence that suppression of follicular aromatase activity is not a prerequisite for the induction of cystic follicles. *Endocrinology* 124: 1646–1653
- Brawer JR, Munoz M, Farookhi R (1986) Development of the polycystic ovarian condition (PCO) in the estradiol valerate-treated rat. *Biol Reprod* 35: 647–655
- Bykov AGS (1974) Cell kinetic studies of follicular atresia in the mouse ovary. *J Reprod Fert* 37: 277–285
- Carriere PD, Farookhi R, Brawer JR (1989) The role of aberrant hypothalamic opioidergic function in generating polycystic ovaries in the rat. *Can J Physiol Pharmacol* 67: 896–901
- Convery M, McCarthy GF, Brawer JR (1990) Remission of the polycystic ovarian condition (PCO) in the rat following hemiovariectomy. *Anat Rec* 226: 328–336
- Dierschke DJ, Hutz RJ, Wolf RC (1985) Induced follicular atresia in rhesus monkeys: Strength-duration relationships of the estrogen stimulus. *Endocrinology* 117: 1397–1403
- Dierschke DJ, Hutz RJ, Wolf RC (1987) Atretogenic action of estrogen in rhesus monkeys: Effects of repeated treatment. *Am J Primatol* 12: 251–261
- Fortune JE (1994) Ovarian follicular growth and development in mammals. *Biol Reprod* 50: 225–232
- Hutz RJ, Bejvan SM, Durning M, Dierschke DJ (1990) Changes in follicular populations, in serum estrogen and progesterone, and in ovarian steroid secretion *in vitro* during the guinea pig estrous cycle. *Biol Reprod* 42: 266–272
- Hutz RJ, Dierschke DJ, Wolf RC (1991) Estradiol-induced follicular atresia in rhesus monkeys is not prevented by exogenous gonadotropins. *Am J Primatol* 23: 247–255
- Mizunuma H, Andoh K, Yamada K, Takagi T, Kamijo T, Ibuki Y (1992) Prediction and prevention of ovarian hyperstimulation by monitoring endogenous luteinizing hormone release during purified follicle-stimulating hormone therapy. *Fert Steril* 58: 46–50
- Neyro JL, Barrenetxea G, Montoya F, Rodriguez-Escudero FJ (1991) Pure FSH for ovulation induction in patients with polycystic ovary syndrome and resistant to clomiphene citrate therapy. *Hum Reprod* 6: 218–221
- Pache TD, Chadha S, Gooren LJG, Hop WCJ, Jaarsma KW, Dommerholt HBR, Fauser BCJM (1991) Ovarian morphology in long-term androgen-treated female to male transsexuals. A human model for the study of polycystic ovarian syndrome? *Histopathology* 19: 445–452
- Quandt LM, Hutz RJ (1993) Induction by estradiol-17 β of polycystic ovaries in the guinea pig. *Biol Reprod* 48: 1088–1094
- Wilkinson L (1990) SYSTAT: The system for statistics. Evanston IL: SYSTAT Inc
- Zar JH (1974) Biostatistical Analysis. Prentice Hall, Inc, Englewood Cliffs, New Jersey