

Dental and skull bone pathologies of the red fox (*Vulpes vulpes*) in Lithuania

Authors: jurgelėnas, Eugenijus, Zakienė, Indrė, and Daugnora, Linas

Source: Journal of Vertebrate Biology, 69(1) : 1-12

Published By: Institute of Vertebrate Biology, Czech Academy of Sciences

URL: <https://doi.org/10.25225/jvb.20004>

BioOne Complete (complete.BioOne.org) is a full-text database of 200 subscribed and open-access titles in the biological, ecological, and environmental sciences published by nonprofit societies, associations, museums, institutions, and presses.

Your use of this PDF, the BioOne Complete website, and all posted and associated content indicates your acceptance of BioOne's Terms of Use, available at www.bioone.org/terms-of-use.

Usage of BioOne Complete content is strictly limited to personal, educational, and non - commercial use. Commercial inquiries or rights and permissions requests should be directed to the individual publisher as copyright holder.

BioOne sees sustainable scholarly publishing as an inherently collaborative enterprise connecting authors, nonprofit publishers, academic institutions, research libraries, and research funders in the common goal of maximizing access to critical research.

Dental and skull bone pathologies of the red fox (*Vulpes vulpes*) in Lithuania

Eugenijus JURGELĖNAS^{1*}, Indrė ZAKIENĖ¹ and Linas DAUGNORA²

¹ Department of Anatomy and Physiology, Veterinary Academy, Lithuanian University of Health Sciences, Tilžės 18, Kaunas, Lithuania; e-mail: eugenijus.jurgelenas@lsmuni.lt, indre.zakienė@lsmu.lt

² Institute of Baltic Region History and Archaeology, Klaipėda University, Herkaus Manto 84, Klaipėda, Lithuania; e-mail: daugnora@gmail.com

► Received 15 January 2020; Accepted 31 March 2020; Published online 13 May 2020

Abstract. The research was aimed at examining 230 skulls and mandibles (113 males and 117 females) of the red fox (*Vulpes vulpes*) in the territory of the Republic of Lithuania. The object of the study was macroscopic evaluation of dental and periodontal pathologies, including changes in the structure of the skull and mandible. The most common teeth pathology was indicated to be hypodontia 13.27% in males and 5.98% in females (excluding M³ molar tooth). The hypodontia of the M³ was found to be common in males 6.19% and 7.69% in females. The findings of the research reveal that pathologies such as hyperdontia, dental fractures, enamel hypoplasia, abrasion, periodontitis stage 3 and stage 4 were less common: 1-4% in both males and females. In four skulls and mandibles of females a complex of severe pathologies of teeth and periodontium were found. There were no similar cases observed in males. This was the only significant difference between males and females. Other pathologies, including fractures of the skull or mandible, atypical form of foramen magnum, and changes in bone structure were rare overall, though slightly more common in males but not significantly.

Key words: Canidae, teeth, non-dental pathology, maxilla, mandible

Introduction

Research on teeth has been widely used in studies of comparative zoology, taxonomy, population identification, and nutrition (Van Vankenbugh & Wayne 1994, Bronner 1996, Thackeray 1997, Badyaev 1998). Dental research has been particularly relevant in palaeontology, since teeth are highly persistent in the fossil record.

Research on dental and periodontal pathologies of carnivores is comparatively frequent. Studies of the teeth pathologies of the red fox have been conducted in several countries: the USA, Czech Republic, and Poland (Szuma 1999, Gisburne &

Feldhamer 2005, Nentvichová & Anděra 2008), and over a relatively long period (Pavlinov 1975).

Comprehensive teeth morphology research was conducted on red foxes by the Mammal Research Institute of the Polish Academy of Sciences. Detailed analysis of the teeth was made in estimating morphotypes of the teeth of red foxes, including examination of sexual dimorphism and evolutionary changes in the teeth (Szuma 2002, 2007, 2008).

Teeth pathologies have been studied in several carnivore species, including grey fox (Gisburne & Feldhamer 2005), wolf (Vilá et al. 1993), and otter (Hauer 2002). A frequent analysis of teeth

* Corresponding Author

pathologies has been associated with ancient specimens, with research revealing that pathologies were more common in domestic dogs than in wild carnivore species (MacKinnon 2010, Kuehn 2014, Janeczek et al. 2015).

Previous studies have tended to include a limited number of categories of teeth pathologies. The most common have been changes in the number of teeth (oligodontia and polydontia), shape varieties of the crown or root, and periodontal structure. This problem was raised by authors who adapted a clinical method for the examination of domestic dogs to evaluate teeth pathologies of wild carnivores (Janssens et al. 2016).

While a variety of studies of teeth have been carried out, including teeth pathologies, there has been a lack of studies of non-dental skull and mandible pathologies. When they have been conducted, studies have been incomplete because research was focused on long bones. Skull pathologies have been conducted on farmed blue foxes (Mustoten et al. 2017), and individual case studies on inflammation and fracture pathologies of the skulls and mandibles of wolves (Barber-Meyer 2012) and brown bears (Pinto & Etxebarria 2001).

Research on the pathological shape of the foramen magnum has only been conducted in domestic dogs (Baranowski 2010, Janeczek et al. 2011), though further research on this structure is warranted since shape pathologies can damage the spinal cord, resulting in locomotory disorders. Further research on pathologies of the foramen magnum may provide insights on neurological disorders (Simoens et al. 1994, Onar et al. 1997, Kahvecioğlu et al. 2000, Janeczek et al. 2008).

There are currently no data on teeth and skull pathologies of wild and domestic carnivores in Lithuania. The current research is intended to provide new information on red fox dental and non-dental pathologies in the territory of Lithuania. These data offer the opportunity for comparison with other regions, including in neighbouring countries for which data are available (Poland, Czech Republic). A standardized method was used to evaluate teeth pathologies (Janssens et al. 2016) and is advocated for use in evaluating oral pathologies of the family Canidae.

An additional motivation to investigate the prevalence of dental and non-dental disease in

red foxes in Lithuania is to explore an association between dental disease and overall systemic health (Bellows et al. 2019). Affected animals with dental problems demonstrate changes in diet selectivity, behaviour, and often decrease food intake (Andrade et al. 2015). Severe dental cases, therefore, lead to starvation and death of the animal, and potentially make an impact on local ecosystems (Andrade et al. 2015, Soe et al. 2017).

Material and Methods

Data were collected from November 1, 2018 to February 1, 2019. The study material was a collection of red fox (*Vulpes vulpes*) skulls held at the Kaunas Tadas Ivanauskas Museum of Zoology, Lithuania. Skulls were collected in the Republic of Lithuania from 1955. The source of the collection was hunters and specimen collectors who found the cadavers of animals. The collection was inventoried and included a registration card with data for body length, weight and gender. In males, the penis bone (*os penis*) has attached with a registration card to confirm gender. Only skulls of adult foxes were examined for this study. The maturity of the red fox skulls was determined by the closure of the presphenoid-vomer and basisphenoid-presphenoid sutures (Evenhuis et al. 2018). A total of 230 skulls and mandibles were investigated (n = 230): 113 males (n = 113) and 117 females (n = 117).

Pathological changes to skulls were evaluated in all locations, described and photographed. Pathologies were divided into two groups based on the topography of bone changes. Group 1 included changes in teeth and alveolar bone and group 2 included pathologies of the skull bones.

Evaluation of teeth was based on a study by Janssens et al. (2016) on the pathologies of carnivore teeth. Two methods of teeth identification were used in the study. The primary method was a classic anatomical dental chart. A modified Triadan System was used for multiple pathologies cases analysis (based on American Veterinary Dental College recommendations). Non-dental pathologies were analysed based on Maxie (2007) and Evans & de Lahunta (2012). Categories of all pathologies are presented in Table 1.

Some digital X-ray images were made to confirm pathological changes. Digital X-ray imaging conducted in a private small animal clinic ('VetPet LT') using Amadeo V-AX stationery system.

Table 1. Descriptions of dental and non-dental pathologies.

Categories	Sub-categories	Short explanation
Dental pathologies (Group 1)		
Periodontal disease	Stage 3	More than 25% but less than 50% loss of alveolar bone
	Stage 4	More than 50% loss of alveolar bone
Tooth fractures	Uncomplicated crown fracture	Fracture without pulp exposure
	Complicated crown fracture	Fracture with pulp exposure
Abnormal number of teeth	Hypodontia	No alveolus present (genetic)
	Traumatic	A tooth is missing, alveolus visible and deformed
	Excessive teeth	Polyodontia/hyperdontia (genetic)
Abrasion	-	Loss of tooth structure due to external factors
Attrition	-	Loss of tooth structure due to wear from opposing teeth
Enamel hypoplasia	-	Due to the severe general disease at a young age or local trauma to a deciduous tooth
Non-dental pathologies (Group 2)		
Bone fractures	-	-
Hyperostotic disease	-	Excessive bone formation (exostosis or osteophytes) Cranio-mandibular periosteal damage
Shape changes of foramen magnum	-	-

Table 2. Numerical dental pathologies and surface changes in males (* same animals).

Dental pathology	Maxilla Left	Maxilla Right	Maxilla Bilateral	Mandible Left	Mandible Right	Mandible Bilateral
Hypodontia – excluding M ³		P ¹ – 1	I ³ – 1	P ¹ – 1	P ¹ – 2	P ¹ – 1
		P ² – 2		P ³ – 1	P ² – 2	
		P ³ – 1		M ¹ – 1	P ⁴ – 1	
		M ² – 1				
Total: 15		5	1	3	5	1
Hypodontia – M ³ only				M ³ – 2	M ³ – 2	M ³ – 3
Total: 7				2	2	3
Hyperdontia				M ³ – 1		
Total: 1				1		
Dental fractures	C – 1			P ⁴ – 1	C – 1 M ¹ – 1	
Total: 4	1			1	2	
Enamel hypoplasia		M ¹ – 1				
Total: 1		1				
Abrasion			C – 3*		C – 3*	
Total: 3			3			
Total number of dental numerical pathologies and surface changes: 31						

Descriptive studies were employed to examine data. Data analysis was performed using SPSS 24.0. Comparison between males and females was evaluated with a Chi-square test.

Results

Group 1 – dental pathologies (males)

Dental numerical pathologies and surface changes of male red foxes were grouped by localization and presented in Table 2.

Oligodontia and multiple pathologies: no cases.

Periodontal disease:

1. Periodontitis, stage 3, left side, maxilla, P³ area.

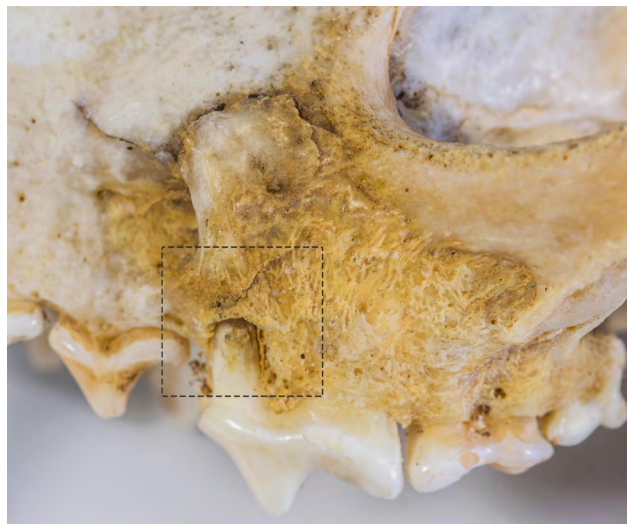


Fig. 1. Periodontitis with local dehiscence (marked by a square) in the skull of a male red fox, (photo Kazimieras Martinaitis).

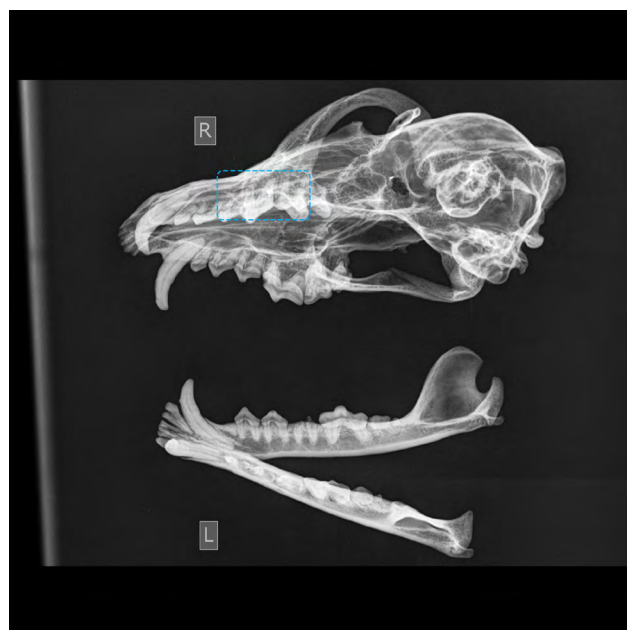

Fig. 2. X-ray of the skull of the male red fox in Fig. 1 (periodontitis with local dehiscence – marked by a square).

2. Periodontitis, stage 3, left side, mandible, P¹-P⁴ area.

3. Periodontitis, stage 4, left side, maxilla, P⁴ area (see below, Fig. 1, Fig. 2).

The total number of dental pathologies in males: 34.

Group 2 – non-dental pathologies of skull bones and mandible (males)

Craniomandibular periosteal damage: three cases. The left lateral side of mandible – porous bone tissue, colour changes. Two identical cases in different skulls. The right lateral side of mandible – porous bone tissue, colour changes.

Bones fractures: one case (see below, Fig. 3, Fig. 4). The left ventral side of the mandible, the interval between P²-P⁴: compression fracture.




Fig. 3. Compression fracture (marked by a square) of the left mandible of a male red fox, (photo Kazimieras Martinaitis).

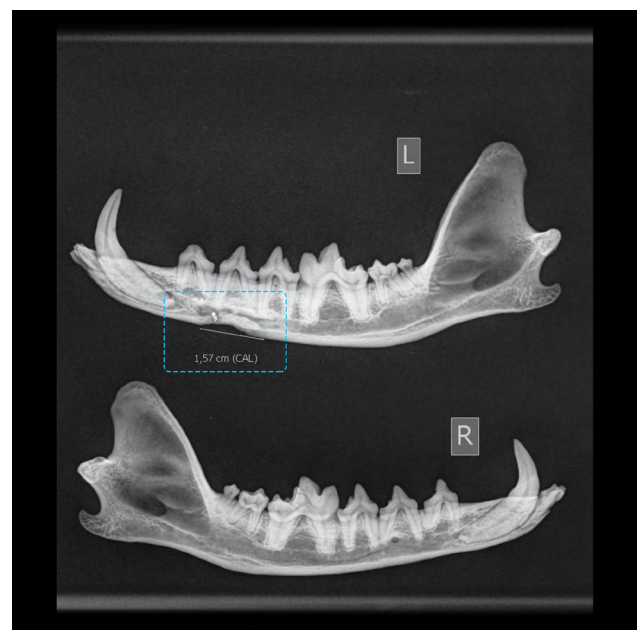

Fig. 4. X-ray of compression fracture (marked by a square) of the left mandible of a male red fox.

Table 3. Numerical dental pathologies and surface changes in females (* same animals).

Dental pathology	Maxilla Left	Maxilla Right	Maxilla Bilateral	Mandible Left	Mandible Right	Mandible Bilateral
Hypodontia – excluding M ³	I ² – 1	P ² – 2		P ¹ – 2 P ² – 1	P ¹ – 1	
Total: 7	1	2		3	1	
Hypodontia – M ³ only				M ³ – 2	M ³ – 4	M ³ – 3
Total: 9				2	4	3
Hyperdontia	C – 1				P ⁴ – 1	
Total: 2	1				1	
Dental fractures	C – 1				C – 1	
Total: 2	1				1	
Enamel hypoplasia	C – 1					
Total: 1	1					
Abrasion		C – 1	C – 4*			C – 4*
Total: 5		1	4			
Total number of numerical dental pathologies and surface changes: 26						

Excessive bone formation: three cases. The left side of the connection between zygomatic and temporal bones, the right side of the frontal bone frontal crest, the left side of the connection between maxilla and zygomatic bone.

Atypical shape of the foramen magnum: no cases.
The total number of non-dental pathologies of skull bones and mandible in males: seven.

Group 1 – dental pathologies (females)

Dental numerical pathologies and surface changes of female red foxes were grouped by localization and presented in Table 3.

Periodontal disease: in other skulls (except severe cases of multiple pathologies (see below), no 3rd or 4th stage periodontitis found.

Oligodontia and multiple pathologies

Case 1 – reg. number M-4414 (Fig. 5, Fig. 6, Fig. 7).

Changes of alveolar bone:

Complete disappearance: 101, 201, 205, 301-304, 311, 401-404.

Partial disappearance: 102, 202, 204.

Alveoli with dental roots: 103-107, 203, 206, 305-308, 405, 406.

Alveoli with teeth: 108-110, 207-210, 309, 310, 407-411.

The rostral part of the maxilla is asymmetrical. Acute porous bone tissue in rostral part maxilla and mandible. Dehiscence because of loss of teeth. Vertical bone resorption in the rostral part.

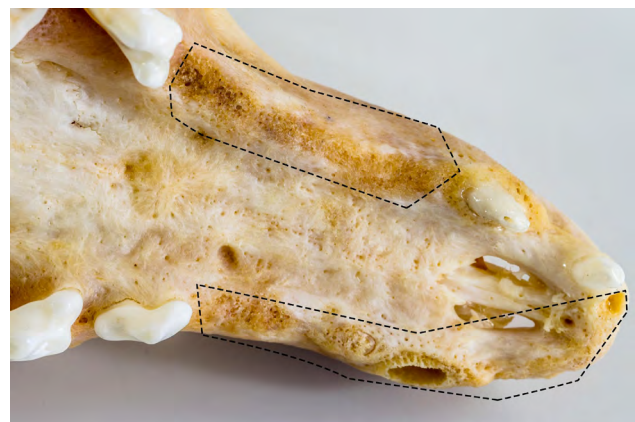

Fig. 5. Multiple pathologies: alveoli with roots or total disappearance, vertical bone resorption and acute porous bone tissue (marked by squares) in the skull of a female red fox, (photo Kazimieras Martinaitis).

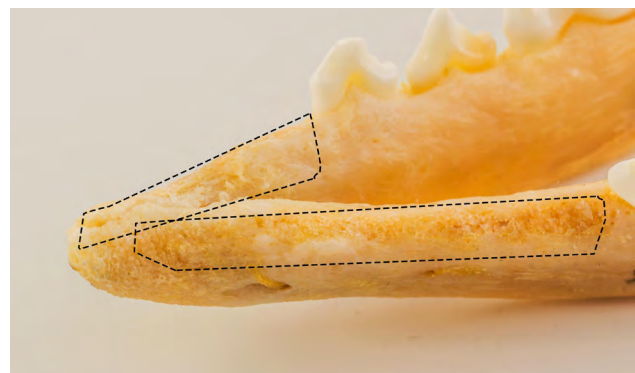


Fig. 6. Multiple pathologies: alveoli with roots or total disappearance, vertical bone resorption and acute porous bone tissue (marked by squares) in the mandible of a female red fox, (photo Kazimieras Martinaitis).

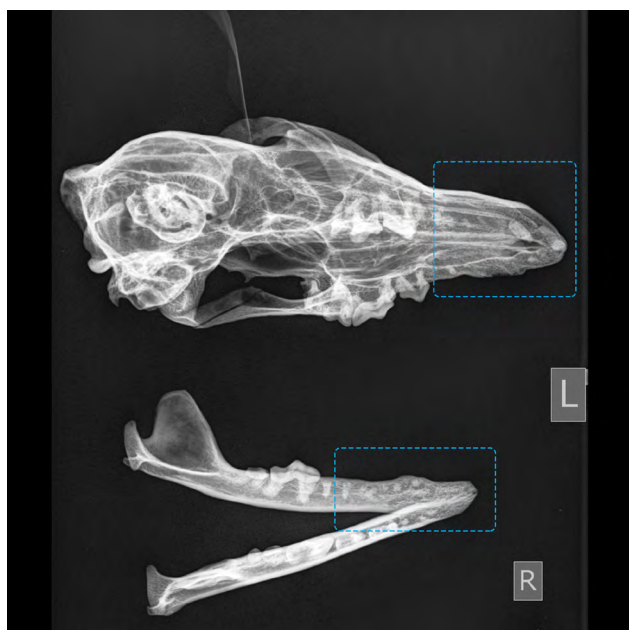


Fig. 7. X-ray of skull and mandible in Fig. 5 and Fig. 6: alveoli with roots or total disappearance, vertical bone resorption and acute porous bone tissue (marked by squares) in a female red fox.

Case 2 – reg. number M-0746. Apertures in nasal, palatal bones and maxilla approximately 1.7 cm.

Changes of alveolar bone:

Complete disappearance: 105, 309, 409.

Partial disappearance: 201, 301, 302, 306, 401, 402.

Alveoli with dental roots: 101, 104, 307, 308, 406-408.

Alveoli with teeth: 105-110, 202-210, 303-305, 310, 311, 403-405, 410, 411.

Alveoli only: 102, 103.

Vertical tooth fracture: 310.

Attrition: 105-110, 202-210, 303-305, 310, 311, 403-405, 410, 411.

Generalised attrition appeared due to traumatic fractures of teeth in mandible.

Roots of teeth kept bone in tone, and bone resorption not evident, except alveoli absent.

Tooth prolongation: 108-110, 208-210. Changes in teeth length appeared due to a lack of antagonist.

Case 3 – reg. number M-0727.

Changes of alveolar bone:

Complete disappearance: 106, 208, 305, 306.

Partial disappearance (spongiosal bone): 101, 102, 105, 108 (mixed type bone resorption), 110, 205.

Alveoli only: 103, 104, 201, 204, 404, 411.

Alveoli with teeth: 107, 109, 202, 203, 206, 207, 209, 210, 307-311, 405-411.

Incisive teeth of mandible were lost during preparation: 301-303, 401-403.

Prolongation of teeth: compensative change of occlusion because of changes in forces in chewing: 309 (changes of occlusion surface), 409 (lack of

antagonist, changes in the curve of occlusion surface).

Changes in cementum – enamel junction: 309 – caries near buccal groove and dehiscence of the bone, changes of dentin.

Attrition: Functional attrition because of lack of antagonist, changes in the symmetry of occlusion and stronger forces in chewing: 109, 206, 209, 210, 304, 309, 409.

Case 4 – reg. number DFM-422.

Changes of alveolar bone:

Complete disappearance: 101-103, 201, 302, 305, 311, 402, 403.

Partial disappearance: 107, 306-309.

Alveoli only: 411.

Alveoli with teeth: 104-106, 108-110, 202-210, 301, 303, 304, 306, 310, 401, 404-410.

Tooth prolongation: Changes in teeth length appeared because of a lack of antagonist. Loss of alveolar bone and teeth because of periodontal disease.

Attrition and abrasion: Functional attrition because of lack of antagonist and abrasion of canines because of behaviour issues.

Total number of dental pathologies: 30.

Group 2 – non-dental pathologies of skull bones and mandible (females)

Craniomandibular periosteal damage: no cases.

Bones fractures: no cases.

Excessive bone formation: one case. The left side of the connection between zygomatic bone and maxilla.

Atypical shape of foramen magnum: two cases (Fig. 8).

Total number of non-dental pathologies of skull bones and mandible: 3.



Fig. 8. Foramen magnum atypical form (on the right) of the skull of a female red fox (marked by a square) compared to typical form (marked by a square on the left), (photo Kazimieras Martinaitis).

Table 4. Statistical significance and distribution of pathologies.

Pathology	Males N = 113	%	Females N = 117	%	χ^2
Hypodontia – excluding M ³	15	13.27	7	5.98	3.53; $P = 0.06$
Hypodontia – M ³ only	7	6.19	9	7.69	0.19; $P = 0.65$
Hyperdontia	1	0.88	2	1.70	0.30; $P = 0.58$
Dental fractures	4	3.53	2	1.70	0.75; $P = 0.38$
Enamel hypoplasia	1	0.88	1	0.85	0.00; $P = 0.98$
Abrasion	3	2.65	5	4.27	0.44; $P = 0.50$
Oligodontia and multiple pathologies	0	0	4	3.41	3.93; $P = 0.04$
Periodontitis	3	2.65	0	0	3.14; $P = 0.07$
Craniomandibular periosteal damage	3	2.65	0	0	3.14; $P = 0.07$
Excessive bone formation	3	2.65	1	0.85	1.09; $P = 0.29$
Atypical shape of foramen magnum	0	0	2	1.70	1.94; $P = 0.16$
Bones fractures	1	0.88	0	0	1.03; $P = 0.30$

Overall, 230 skulls with mandibles (males – 113, females – 117) were examined. Seventy-four skull pathologies (dental and non-dental) of both sex foxes were identified (32.17%), in males – 41 (36.28%), in females – 33 (28.20%).

Our findings revealed that skull pathologies in males were not significantly more frequent compared to females ($\chi^2 = 1.71$, $P = 0.18$).

The number of pathologies comparing maxilla to the mandible in males: maxilla 32.25%, mandible 67.74%; in females: maxilla 28.57%, mandible 71.42%. The distribution of pathologies was also not dependent on sex ($\chi^2 = 0.77$, $P = 0.08$) (abrasions are not included).

Thus, across different types of dental and skull bone pathologies, we detected no statistical difference between males and females, except in multiple pathologies where more cases were found in females (Table 4).

Discussion

In the present study, hypodontia was the most common dental pathology and was identified in 16.5% of red fox skulls ($n = 38$). Szuma (1999) analysed the same pathology in a neighbouring region in Poland, and detected a lower prevalence of hypodontia in red foxes (7.2%). The lack of M³ was the most common type of hypodontia and was observed in 6.95% of skulls ($n = 16$). In the study by Szuma (1999) only 2.8% of skulls

had M³ hypodontia. Similar results were found by Nentvichová & Anděra (2008) in the Czech Republic where the lack of M³ and P¹ was the most prevalent, especially in females (males 6.4%; females 11.4%). Moreover, Gisburne & Feldhamer (2005) compared the dental pathologies of grey and red foxes in the USA and the most common pathology was hypodontia of M³ and P¹. In this study, 19.8% grey foxes and 8.6 % red foxes had hypodontia and more than half of all foxes of both species lacked M³. These findings demonstrate that in several different regions (Poland, Czech Republic, USA, and Lithuania), red foxes primarily have the same prevailing dental pathology – hypodontia of M³ and P¹. The lack of M³ and P¹ has a negligible impact on food processing and quality of life in comparison with the absence of canines, larger premolars, and molars (Nentvichová & Anděra 2008). In the present study we additionally demonstrated that the absence of P² was more frequent ($n = 7$ from 230 evaluated skulls) in comparison with Szuma's (1999) study, in which the absence of P² has found in 4 cases of 1453 skulls.

Hypodontia is a common pathology in the Canidae and similar results have been demonstrated in other canid species. For example, Janssens et al. (2016) analysed wolf (*Canis lupus*) skulls and demonstrated hypodontia in 20% ($n = 8$). However, hypodontia it is not a general rule for all carnivores:

only 0.9% of otter skulls (*Lutra lutra*) exhibited hypodontia (Hauer 2002).

The main reason for hypodontia is genetics and trauma, though in some cases, teeth may be lost in the preparation of skulls. In the present study, a probable reason for hypodontia was genetic since there was no evidence for fractured root fragments and alveoli (Janseens et al. 2016). Yom-Tov et al. (2003) investigated the progressive increase in size of red fox skulls and teeth during the twentieth century. In the author's opinion, the aetiology of hypodontia may be associated with the increased size of teeth which creates limited space for the third molar. In another study the connection between X-linked hypohidrotic ectodermal dysplasia and hypodontia in dogs was investigated (Lewis et al. 2010). Other factors, such as canine distemper virus (*Canine morbillivirus*) infection, could affect teeth development in early life and might increase the likelihood of hypodontia (Janseens et al. 2015). Unfortunately, it was impossible to evaluate those explanations in the current study.

Possession of supernumerary teeth, hyperdontia, was also recognised in some specimens (1.3%). An explanation for this pathology may also have a genetic basis. Pavlica et al. (2001) revealed that the supernumerary teeth in domestic dogs (*Canis familiaris*) can appear as a result of a mutation caused by inbreeding. Walton et al. (2017) made a detailed study of the home ranges of red foxes in the Scandinavian region. Their study showed that the home range of red foxes was smaller in the southern area of their study compared with the northern region. In our study of specimens from Lithuania, which is the most southerly Baltic state, home ranges may be relatively small and gene flow may be more limited than elsewhere, though further research on red fox migration in the Baltic region will be needed to clarify this explanation.

In the study by Szuma (1999), only 2% of skulls showed hyperdontia ($n = 29$), while Nentvichová & Anděra (2008) found 10 cases of hyperdontia in 758 skulls. Gisburne & Feldhamer (2005) detected just 0.4% ($n = 3$) of cases of hyperdontia in red and grey fox skulls. These authors suggest that the most common supernumerary teeth were P^1 and P^2 . However, in our study M^1 , P^4 and some canines were in excess. Hyperdontia of canines was also seen in grey foxes by Gisburne & Feldhamer (2005). Hyperdontia in wolves was recorded at a rate of

3.6%, although the supernumerary tooth in this species was P^1 (Vilá et al. 1993). A study of wolf skulls in Latvia, showed that polydontia (5.3%) occurred more frequently than oligodontia (2.1%) (Andersone & Ozolins 2000).

In the present study, only clear cases of dental fractures were included and our results exclude artefacts arising from skull preparation and storage. Complicated dental crown fractures were the most frequent. Only two cases of uncomplicated crown fractures (P^4 – maxilla, M^1 – mandible) were discovered. Dental fractures comprised 2.6% of all skulls in the collection. Previous studies of feral cats have shown complicated crown and root fractures in 54.8% of individuals and 7.0% of their teeth, with fractures most common in the canine and carnassial teeth (Verstraete et al. 1996). Collados et al. (2018) analysed Iberian lynx dental fractures and detected 215 with fractured teeth (11.3%), with fractures primarily seen in the maxillary (24.2%) and mandibular canine teeth (16.7%). Dental fractures in polar bears were recorded in 52 out of 317 skulls examined (20.9%). Fractures appeared more frequent in males than females, though these results are questionable (Winer et al. 2016). In general, dental fractures were rarely seen in the present study, but otherwise our findings were similar to previous work. Notably, in Janssens et al.'s (2016) analysis of wolf skulls it was canines that were the most frequently fractured teeth. In contrast, Butković et al. (2001) found that incisors and the first premolars were the most fractured teeth in domestic dogs. In each case the cause of fractures was attributed to trauma of the teeth, probably as a result of fighting and hunting. Enamel hypoplasia is rare in wild carnivores. In the current study, only two cases (0.9%) were detected in 230 skulls. Szuma (1999) similarly found that just 2.5% of 1453 red fox skulls had enamel hypoplasia, while Evenhuis et al. (2018) identified only a single case among 637 grey fox skulls. Results were similar in a study of wolves, with 2.4% of skulls showing signs of enamel hypoplasia (Döring et al. 2018). In a separate study, only 17 dogs and wolves were affected out of 544 individuals examined by Losey et al. (2014). The most commonly affected teeth were the mandibular canines, though the number of affected teeth was too small meaningful patterns to be identified (Losey et al. 2014).

Attrition of the canine teeth was a common pathology in severe cases in the present study. Attrition of the canines was evident in all quarters

of the skull ($n = 7$), though only clear cases of attrition were scored. In these cases, the dentin layer was visible. Evenhuis et al. (2018) recorded low-level abrasions that could not be detected macroscopically, so the number of attritions or abrasions in their study was high relative to ours ($n = 487$, 85.6%). Functional attrition develops in response to increased pressure on the teeth, changes in dentition symmetry following trauma, changes in the number of teeth, and absence of an antagonist tooth. The reason for incisor attrition may be due to intensive coat nibbling (Janssens et al. 2016).

Low-level periodontal disease was excluded from the present research because of the lack of oral soft tissue and periodontal ligaments and only the third and fourth stage periodontal disease was evaluated. Third and fourth stage periodontal disease was found in three skulls of males and with severe cases in some females. Second stage periodontal disease is typically reported in previous research and, therefore, shows higher prevalence than in the current study. Döring et al. (2018) noted evidence of periodontal disease stages 2-4 on 115 skulls (55.6%) of wolves. Stage 2 periodontal disease presented on 865 teeth of 29 skulls (10.0% and 14.0%, respectively). Similar results were reported by Evenhuis et al. (2018), with almost half of all grey fox skulls examined ($n = 276$, 48.7%) displaying some degree of bony change consistent with periodontitis. Among affected specimens, 226 (39.7%) displayed bony changes suggestive of stage 2 periodontitis, 120 (21.1%) indicating stage 3 and 13 (2.3%) stage 4.

An additional goal of the current research was to evaluate skull and mandible pathologies. Temporomandibular joint changes and osteoarthritis were excluded from the study, though a fuller analysis of these issues is warranted. The first category of analysed pathologies was craniomandibular periosteal damage, including bony growths – exostoses and osteophytes. Their prevalence was low and did not vary significantly between the sexes.

Research on bone changes in the skulls of wild carnivores is less common than studies on dental changes. Gomerčić et al. (2009) made a study of bone pathologies in Eurasian lynx (*Lynx lynx*). Non-dental disorders of the skull were observed in two of 58 skulls. In one, the zygomatic process

of the frontal bone was shorter and covered with osteophytes during the lifetime.

In the present study, osteophytes were frequent in the region of the zygomatic arch and osteophytes were observed in the frontal crest. There is a hypothesis that the connection between bone and muscle is significant in aetiology of this pathology. Evans & de Lahunta (2012) mentioned that the biggest muscle for chewing, the temporal muscle, is connected to the zygomatic crest in domestic dogs.

Foreign bodies trapped between the left and right-side premolars and molars are one of the reasons why inflammation of bone appears in the palatine region. Barber-Meyer (2012) mentioned that trapped foreign bodies caused severe inflammation on both sides of the maxilla and zygomatic bone of wolves. In the present study, bone inflammation was more prevalent in the mandible, though we could not detect the cause because of a lack of soft tissue.

Only one case of a skull or mandible fracture was detected in this study. This finding is similar to other studies, probably because skull fractures, especially in the region of the brain, are severe and typically lethal. Kuehn (2014) found only isolated fractures in domestic dogs. In general, mandible fractures in domestic dogs represent 1.5-2.5% of all fractures. Fractures in the premolar region are the most prevalent and the main cause is trauma in accidents and fights. In this study, the only fracture that was found in the premolar region in the skull of a male fox may have been the result of a fight.

Changes in the shape of the foramen magnum was observed in two female red foxes. The usual shape of the foramen magnum in a typically proportioned (mesaticephalic) domestic dog is oval. Hidaka et al. (1998) indicated this shape is also seen in Japanese raccoon dogs (Tanuki). Karan et al. (2006) similarly observed an oval shaped foramen magnum in the Kangal breeds of dog, as well as in cats, badgers, and martens. In the present study an atypical shape was triangular with a projection to the dorsal side. Some authors have observed that it is not clear whether the dorsal notch of the foramen magnum seen in some animal species reflects anatomy or pathology (Janeczek et al. 2008). In beagles, Pekingese and Doberman pinschers it is usually described as a normal morphological feature, yet

in German shepherds (mesaticephalic skull) as a pathology (Onar et al. 2013). The skulls of red foxes are categorised as mesaticephalic (Jurgelėnas et al. 2011), so the change in shape of the foramen magnum is possibly a pathology.

In general, the dental and non-dental skull pathologies in red foxes in Lithuania are similar to those in other regions of Europe. Missing or supernumerary teeth was the most common pathology in red foxes. Evidence of trauma was associated with damage to teeth and compromised bone health. Attrition was attributed to missing teeth caused by trauma but may also be associated with genetic disorders, especially in severe cases. Enamel hypoplasia appeared a rare pathology in the red fox. We identified a need for a fuller analysis of the effects of periodontal disease and bone changes in the temporomandibular joints in red foxes. Dental and non-dental inflammatory disease appeared rare in the red fox. Finally, there

was no significant evidence for an association between pathology and sex in this study, though further research to examine the link between severe trauma, sex, and behaviour in the red fox is warranted.

Acknowledgements

We grateful to Vaclovas Gedminas, Head of the Mammal Department of Kaunas Tadas Ivanauskas Museum of Zoology, for help with our research, as well as Kazimieras Martinaitis, Head of Accounting and Storage of the Collections Department for photographs. We also thank small animal clinic "VetPet LT" for taking X-ray images. Author contributions: E. Jurgelėnas conceived the research and analysed the data. E. Jurgelėnas and L. Daugnora carried out measurements. I. Zakienė performed clinical evaluation models and X-ray analysis. E. Jurgelėnas and I. Zakienė wrote the manuscript with assistance from L. Daugnora. E. Jurgelėnas took overall charge of directing and planning the study.

Literature

- Andersone Ž. & Ozolins J. 2000: Craniometrical characteristics and dental anomalies in wolves *Canis lupus* from Latvia. *Acta Theriol.* 45: 549–558.
- Andrade P.M., Thais O.M., Mallmann P.R. et al. 2015: Occurrence of oral diseases in neotropical wild carnivores kept in captivity at the zoo from Federal University of Mato Grosso – Cuiabá. *Semin. Cienc. Agrar.* 36: 2633–2640.
- Badyaev A.V. 1998: Environmental stress and developmental stability in dentition of the Yellowstone grizzly bears. *Behav. Ecol.* 9: 339–344.
- Baranowski P. 2010: Morphometric analysis of early medieval dog skulls from Pomerania allowing for forehead position index and dorsal notch of the foramen magnum. *Electron. J. Pol. Agric. Univ.* 13: #16.
- Barber-Meyer Sh. 2012: Severe maxillary osteomyelitis in a gray wolf (*Canis lupus*). *Can. Field-Nat.* 126: 238–241.
- Bellows J., Berg M.L., Dennis S. et al. 2019: 2019 AAHA dental care guidelines for dogs and cats. *J. Am. Anim. Hosp. Assoc.* 55: 49–69.
- Bronner G.N. 1996: Non-geographic variation in morphological characteristics of the Hottentot golden mole, *Amblysomus hottentotus* (Insectivora: Chrysochloridae). *Mammalia* 60: 702–727.
- Butković V., Šimpraga M., Šehić M. et al. 2001: Dental diseases of dogs: a retrospective study of radiological data. *Acta Vet. Brno* 70: 203–208.
- Collados J., Garcia C. & Rice C. 2018: Dental pathology of the Iberian lynx (*Lynx pardinus*), part I. Congenital, developmental, and traumatic abnormalities. *J. Vet. Dent.* 35: 195–208.
- Döring S., Arzi B., Winer J.N. et al. 2018: Dental and temporomandibular joint pathology of the grey wolf (*Canis lupus*). *J. Comp. Pathol.* 160: 56–70.
- Evans H.E. & de Lahunta A. 2012: Miller's anatomy of the dog. W. B. Saunders Company, Philadelphia.
- Evenhuis J.V., Zisman I., Kass P. & Verstraete F. 2018: Dental pathology of the grey fox (*Urocyon cinereoargenteus*). *J. Comp. Pathol.* 158: 39–50.
- Gisburne T.J. & Feldhamer G.A. 2005: Dental abnormalities in the gray fox *Urocyon cinereoargenteus* and the red fox *Vulpes vulpes*. *Acta Theriol.* 50: 515–520.
- Gomerčić T., Gužvica G., Gomerčić M.D. et al. 2009: Variation in teeth number, teeth and skull disorders in Eurasian lynx, *Lynx lynx* from Croatia. *Folia Zool.* 58: 57–65.
- Hauer S. 2002: Population analysis of dental anomalies of otters *Lutra lutra* from eastern Germany. *Acta Theriol.* 47: 339–362.
- Hidaka S., Matsumoto M., Hiji H. et al. 1998: Morphology and morphometry of skulls of raccoon dogs, *Nyctereutes procyonoides* and badgers, *Meles meles*. *J. Vet. Med. Sci.* 60: 161–167.
- Janeczek M., Chrószcz A. & Czerski A. 2011: Morphological investigations of the occipital area in adult American Staffordshire terriers. *Anat. Histol. Embryol.* 40: 278–282.
- Janeczek M., Chrószcz A., Henklewski R. et al. 2015: Vertebral disease in excavated canine in Lower Silesia, Poland. *Int. J. Paleopathol.* 10: 43–50.
- Janeczek M., Chrószcz A., Onar V. et al. 2008: Morphological analysis of the foramen magnum of dogs from the Iron Age. *Anat. Histol. Embryol.* 37: 359–361.
- Janssens L., Napierala H. & Street M. 2015: Description and pathology of the Bonn-Oberkassel dog. In: Giemsch L. & Schmitz R.W. (eds.), The late Glacial burial from Oberkassel revisited. *Rheinische Ausgrabungen* 72: 275–289.
- Janssens L., Verhaert L., Berkowic D. & Adriaens D. 2016: A standardized framework for examination of oral lesions in wolf skulls (Carnivora: Canidae: *Canis lupus*). *J. Mammal.* 97: 1111–1124.
- Jurgelėnas E., Daugnora L., Lasys V. & Venskutonis D. 2011: Skull shape variation of raccoon dogs and red foxes in Lithuania. *Vet. Zootech.* 55: 8–13.
- Kahvecioğlu K.O., Onar V., Alpak H. & Pazvant G. 2000: The morphometry of the foramen magnum in rabbits and its correlation with craniometric measurements. *Folia Vet.* 44: 62–69.
- Karan M., Timurkaan S., Özdemir D. & Ünsaldi E. 2006: Comparative macroanatomical study of the neurocranium in some carnivora. *Anat. Histol. Embryol.* 35: 53–56.
- Kuehn S. 2014: Prehistoric dog pathology in the American bottom: evidence from the Janey B. Goode Site (11S1232), St. Clair County, Illinois. *Illinois Archaeology Survey* 26: 97–129.
- Lewis J.R., Reiter A.M., Mauldin E.A. et al. 2010: Dental abnormalities associated with X-linked

- hypohidrotic ectodermal dysplasia in dogs. *Orthod. Craniofac. Res.* 13: 40–47.
- Lozey R.J., Jessup E., Nomokonova T. & Sablin M. 2014: Craniomandibular trauma and tooth loss in northern dogs and wolves: implications for the archaeological study of dog husbandry and domestication. *PLOS ONE* 9: e99746.
- MacKinnon M. 2010: 'Sick as a dog': zooarchaeological evidence for pet dog health and welfare in the Roman world. *World Archaeol.* 42: 290–309.
- Maxie G.M. 2007: Jubb, Kennedy & Palmer's pathology of domestic animals, vol. 1/ed. 5. *Elsevier Health Sciences*.
- Mustonen A., Lawier D., Ahola L. et al. 2017: Skeletal pathology of farm-reared obese juvenile blue foxes (*Vulpes lagopus*). *J. Vet. Anat.* 10: 51–74.
- Nentvichová M. & Anděra M. 2008: Dental anomalies and dental variations in the red fox *Vulpes vulpes* in the Czech Republic. *Acta Theriol.* 5: 217–228.
- Onar V., Mutuş R. & Kahvecioğlu K.O. 1997: Morphometric analysis of the foramen magnum in German shepherd dogs (Alsations). *Ann. Anat.* 179: 563–568.
- Onar V., Pazvant G., Gezer Ince N. et al. 2013: Morphometric analysis of the foramen magnum of byzantine dogs excavated in Istanbul Yenikapi at the site of theodosius harbour. *Mediterr. Archaeol. Archaeom. Int. J.* 13: 135–142.
- Pavlica Z., Erjavec V. & Petelin M. 2001: Teeth abnormalities in the dog. *Acta Vet. Brno* 70: 65–72.
- Pavlinov I.Y. 1975: Tooth anomalies in some Canidae. *Acta Theriol.* 20: 507–519.
- Pinto A.C. & Etxebarria F. 2001: Description of pathological conditions in the skeleton of an adult male brown bear *Ursus arctos* from the Cantabrian range of mountains (Reserva Nacional de Caza de Riano, León). *Cadern. Lab. Xeol. Laxe* 26: 564–477.
- Simoens P., Poels P. & Lauwers H. 1994: Morphometric analysis of foramen magnum in Pekingese dogs. *Am. J. Vet. Res.* 55: 34–39.
- Soe E., Davison J., Süld K. et al. 2017: Europe-wide biogeographical patterns in the diet of an ecologically and epidemiologically important mesopredator, the red fox *Vulpes vulpes*: a quantitative review. *Mammal Rev.* 47: 198–211.
- Szuma E. 1999: Dental abnormalities in the red fox *Vulpes vulpes* from Poland. *Acta Theriol.* 44: 393–412.
- Szuma E. 2002: Dental polymorphism in a population of the red fox (*Vulpes vulpes*) from Poland. *J. Zool. Lond.* 256: 243–253.
- Szuma E. 2007: Geography of dental polymorphism in the red fox *Vulpes vulpes* and its evolutionary implications: *Biol. J. Linn. Soc. Lond.* 90: 61–84.
- Szuma E. 2008: Geography of sexual dimorphism in the tooth size of the red fox *Vulpes vulpes* (Mammalia, Carnivora). *J. Zool. Syst. Evol. Res.* 46: 73–81.
- Thackeray J.F. 1997: Morphometric, palaeoecological and taxonomic consideration of southern African zebras: attempts to distinguish the quagga. *S. Afr. J. Sci.* 93: 89–93.
- Van Valkenburgh B. & Wayne R. 1994: Shape divergence associated with size convergence in sympatric East African jackals. *Ecology* 75: 1567–1581.
- Verstraete F., Van Aarde R., Nieuwoudt B.A. et al. 1996: The dental pathology of feral cats on Marion Island, part I. Congenital, developmental and traumatic abnormalities. *J. Comp. Pathol.* 115: 265–282.
- Vilá C., Urios V. & Castroviejo J. 1993: Tooth losses and anomalies in the wolf (*Canis lupus*). *Can. J. Zool.* 71: 968–971.
- Walton Z., Samelius G., Odden M. & Willebrand T. 2017: Variation in home range size of red foxes *Vulpes vulpes* along a gradient of productivity and human landscape alteration. *PLOS ONE* 12: e0175291.
- Winer J.N., Arzi B., Leale D.M. et al. 2016: Dental and temporomandibular joint pathology of the polar bear (*Ursus maritimus*). *J. Comp. Pathol.* 155: 231–241.
- Yom-Tov Y., Yom-Tov S. & Baagøe H. 2003: Increase of skull size in the red fox (*Vulpes vulpes*) and Eurasian badger (*Meles meles*) in Denmark during the twentieth century: an effect of improved diet? *Evol. Ecol. Res.* 5: 1037–1048.