



Skeletal Injuries of Passerines Caused by Road Traffic

Authors: Orłowski, Grzegorz, and siembieda, Jan

Source: Acta Ornithologica, 40(1) : 15-19

Published By: Museum and Institute of Zoology, Polish Academy of Sciences

URL: <https://doi.org/10.3161/068.040.0106>

BioOne Complete (complete.BioOne.org) is a full-text database of 200 subscribed and open-access titles in the biological, ecological, and environmental sciences published by nonprofit societies, associations, museums, institutions, and presses.

Your use of this PDF, the BioOne Complete website, and all posted and associated content indicates your acceptance of BioOne's Terms of Use, available at www.bioone.org/terms-of-use.

Usage of BioOne Complete content is strictly limited to personal, educational, and non - commercial use. Commercial inquiries or rights and permissions requests should be directed to the individual publisher as copyright holder.

BioOne sees sustainable scholarly publishing as an inherently collaborative enterprise connecting authors, nonprofit publishers, academic institutions, research libraries, and research funders in the common goal of maximizing access to critical research.

Skeletal injuries of passerines caused by road traffic

Grzegorz ORŁOWSKI^{1*} & Jan SIEMBIEDA²

¹Department of Agricultural Bases for Environmental Management, Agricultural University of Wrocław, pl. Grunwaldzki 24, 50-363 Wrocław, POLAND

²Department and Clinic of Surgery, Faculty of Veterinary Medicine, Agricultural University of Wrocław, pl. Grunwaldzki 51, 50-366 Wrocław, POLAND

*Corresponding author: orlog@poczta.onet.pl

Orłowski G., Siembieda J. 2005. Skeletal injuries of passerines caused by road traffic. *Acta Ornithol.* 40: 15–19.

Abstract. Radiographic examination of 35 birds (17 species) killed on roads revealed bone injuries in 17 (47%) cases. There were 30 different kinds of injuries to the skeletal system. In 29 cases these fractures concerned the long bones of the wings (n = 15) and the lower extremities (n = 14). One bird had a dislocated spinal column. Wing fractures affected the humerus (n = 6), radius (n = 6) and ulna (n = 3), while leg fractures affected the femur (n = 5), tibiotarsus (n = 8) and tarsometatarsus (n = 1). No relationship was found between the body weight and the location and number of bone injuries. In our opinion, the nature and type of skeletal injuries suggest that they were not the direct cause of death.

Key words: road-kills, small passerines, avian injuries, bone fractures, radiological analysis

Received – Dec. 2004, accepted – March 2005

INTRODUCTION

Mortality from road traffic in wild populations of animals is a serious ecological problem in many regions of the world (Underhill & Angold 2000, Erritzoe et al. 2003). Birds are among those animals which are most often killed on roads (Lode 2001, Clevenger et al. 2003, Erritzoe et al. 2003). Notwithstanding the number of articles about bird mortality on roads there is no detailed information about the specific injuries sustained by road-killed birds (see: Clevenger 2000, Erritzoe et al. 2003). Quantitative information about the scale of the problem and type of injuries are available from bird rehabilitation centres, where typically large birds of prey are treated (Wendell et al. 1999). In North Carolina, for example, of several thousand injured birds of prey that were treated between 1998–2002, 39% sustained injuries from collisions with cars and most had broken wing bones (data from North Carolina Raptor Center). More quantitative data on collision injuries are available from birds killed at buildings and power lines (Clausen & Gudmunson 1981, Klem 1990, Hebert & Reese 1995, Veltri & Klem 2005).

Recently, veterinary practices have increased their attention to diagnostic and treatment procedures of bone fractures in wild birds (mainly birds of prey) injured by collisions with man-made objects (e.g. Beregi et al. 1999, Wendell et al. 1999).

Bone fractures may be frequent in wild birds (e.g. Lidauer 1983, Brandwood et al. 1986, Wokac 1990), but not necessarily lethal. Out of 1930 examined skeletons of 173 species of birds, which were collected throughout Germany, 430 (22%) had healed fractures and most of these were forest birds (Wokac 1990). Brandwood et al. (1986) reported similar data describing healed fractures of wings and legs in 0.2 to 0.5% of all birds. They examined a few hundred skeletons of ducks, gulls and Rock Pigeons *Columba livia* from different habitats (Brandwood et al. 1986).

Our objectives were: 1) to describe skeletal injuries in birds killed by cars, and 2) to determine if bird body mass is associated with the number and kind of bone injuries caused by these collisions.

MATERIALS AND METHODS

Thirty five passerines belonging to 17 species were examined radiographically. Most

specimens were Barn Swallow *Hirundo rustica* (n = 9) and House Sparrow *Passer domesticus* (n = 8). Most victims were collected as part of ongoing research program devoted to road mortality of vertebrates (Orłowski & Nowak 2004, G. Orłowski unpubl. data). Data were collected from June 2001 to August 2003 on 48.8 km road network located in the agricultural landscape in the vicinity of Wrocław city (Lower Silesia, SW Poland). Birds without clear external body damages were chosen for examination. Additionally, three road-kills were collected in the neighbourhood of Głogów (SW Poland) and one individual – a Nutcracker *Nucifraga caryocatactes*, in the area of the Bieszczady (SE Poland). Birds were stored frozen (-25°C). Prior to radiographic examination specimens were thawed at room temperature (ca. 20°C). Radiographs were taken by a Siemens 150kVp, 1000 mA X-ray unit and developed using the AGFA ADC Solo computer radiography system (CR). To document more precisely the skeleton damage, single large-size radiographs were taken of specific fracture sites. Because of possible weight loss of road-killed birds, caused by being dried up postmortem (precise data of collision were not known), body masses of birds were calculated on the basis of the mean values of birds' weight from central and northern Europe, taken from Ferens (1971) and Cramp (1998). Data were analysed using the Mann-Whitney test, χ^2 (2×2) test, sign tests, and the Spearman rank correlation coefficient. We used MS Excel 2000 and Statistica 5 for all statistical analyses. We considered test results to be statistically significant where $p \leq 0.05$.

RESULTS

Bone injuries were detected in 17 (49%) of the 35 victims (Table 1). Besides that, in one radiographically examined road-killed specimen of Collared Dove *Streptopelia decaocto* no fractures were found (this result was not included in further analysis). Thirty bone injuries were detected: 29 were in long bones, and the spinal column was dislocated in one victim. Single fractures were found in eight birds (Fig. 1). In four birds, two individuals of House Sparrow *Passer domesticus*, a Marsh Warbler *Acrocephalus palustris* and a Yellow Wagtail *Motacilla flava*, fractures were in the leg and wing. The number of fractures of wing and leg was 15 and 14, respectively. Wing fractures were in the humerus (n = 6), radius (n = 6) and ulna (n = 3) (Fig. 2A and 2B). Leg injuries were in the femur (n = 5), tibiotarsus (n = 8) and tarsometatarsus (n = 1). Fractures occurred on both the left (n = 18) and right (n = 11) side of the body ($\chi^2 = 3.38$, df = 1, $p = 0.07$). In 27 (93%) cases fractures were found in the midshaft of the bones. In two cases (7%) fractures were located in the epiphysis of the bone (Fig. 2B).

In the group of birds (n = 5) with injuries of the forearm, two individuals had both the ulna and radius fractured, and in the remaining victims only the radius was fractured (sign test, two-tailed, $p > 0.30$). In the group of birds (n = 7) with injuries within leg, one individual had both the tibiotarsus and tarsometatarsus fractured, and in the remaining victims only the tibiotarsus was fractured (sign test, two-tailed, $p = 0.031$).

There were no significant differences in average bodyweight between birds with (n = 17)

Table 1. Skeletal injuries (n = 30) of 35 road-killed birds collected in southern Poland in 2001–2003; abbreviations are: humerus (Hum), ulna (Uln), radius (Rad), femur (Fem), tibiotarsus (Tib), tarsometatarsus (Trs), vertebral column (Vbc).

Species	No of individuals/ No ind. with skeleton injuries	Number of fractures within skeleton elements						
		Hum	Uln	Rad	Fem	Tib	Trs	Vbc
<i>Passer montanus</i>	2/2		1	1		1		
<i>Passer domesticus</i>	8/6	2		1	2	5		1
<i>Hirundo rustica</i>	9/4	3			1			
<i>Carduelis chloris</i>	1/1			2				
<i>Acrocephalus palustris</i>	1/1	1			2			
<i>Nucifraga caryocatactes</i>	1/1		2	1				
<i>Sylvia atricapilla</i>	2/1					1		
<i>Motacilla flava</i>	1/1			1		1	1	
Total	25/17	6	3	6	5	8	1	1

Remaining birds without skeletal injuries (number of individuals):

Oenanthe oenanthe (1), *Carduelis cannabina* (1), *Miliaria calandra* (1), *Phylloscopus trochilus* (1), *Sylvia communis* (1), *Fringilla coelebs* (2), *Delichon urbica* (1), *Lanius collurio* (1), *Luscinia megarhynchos* (1).

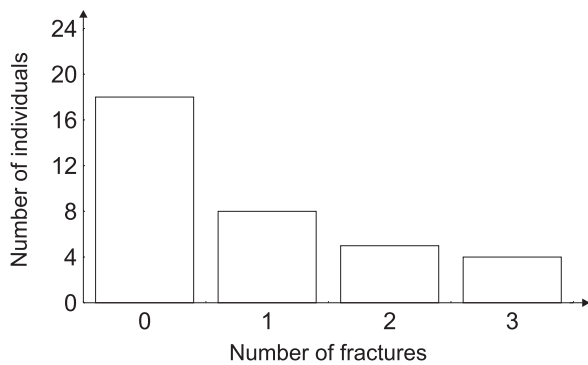


Fig. 1. Distribution of skeletal fractures ($n = 30$) in 35 road-killed birds collected in southern Poland in 2001–2003.

and without ($n = 18$) fractures (in the group of all 35 road killed passerines: weight of birds with fractures 31.8 g vs 22.3 g for birds without fractures, Mann-Whitney test, $U = 104.0$, $Z = 1.62$, $p = 0.10$; in the group of 34 birds without a Nutcracker: weight of birds with fractures 23.9 g vs 22.3 g for birds without fractures, Mann-Whitney test, $U = 104.0$, $Z = 1.38$, $p = 0.17$). Also, no relation was found between body weight of birds and number of fractures (for all 35 birds: $r_s = -0.28$, $p = 0.10$; in the group of 17 birds with injuries: $r_s = 0.16$, $p = 0.54$), number of fractures of wing bones (for all 35 birds: $r_s = 0.19$, $p = 0.03$; for 17 birds with injuries, $r_s = 0.17$, $p = 0.50$) and number of fractures of leg bones (for all 35 birds: $r_s = 0.12$, $p = 0.48$; for 17 birds with

injuries, $r_s = -0.19$, $p = 0.47$). In the birds with skeletal injuries there was a statistically significant negative correlation between the number of fractures in the wing and leg ($n = 17$, $r_s = -0.66$, $p = 0.004$).

DISCUSSION

The nature of the skeletal injuries sustained by the road-killed specimens we studied suggests that these were not the direct cause of their death. However, the fractures we found were serious enough to hamper or prevent flight. In general, we found road-killed injuries to be similar for all casualties. Probably the nature and the number of injuries depended mainly on the speed of a vehicle and the surface area of the bird's body and not on the bodyweight of the bird. Similarly, no relationship between body mass and number of skeletal fractures was found in birds killed after colliding with towers or windows (Veltri & Klem 2005).

The detected damages correspond to those described for much heavier large birds of prey and in Anatidae that were injured because of collisions with power lines. Usually, as a result of such collisions, birds had fractures in the humerus, radius and ulna (e.g. Clausen & Gudmundsson 1981, Wendell 1999). Despite the small number of examined specimens, our results reliably show that fractures of radius appear

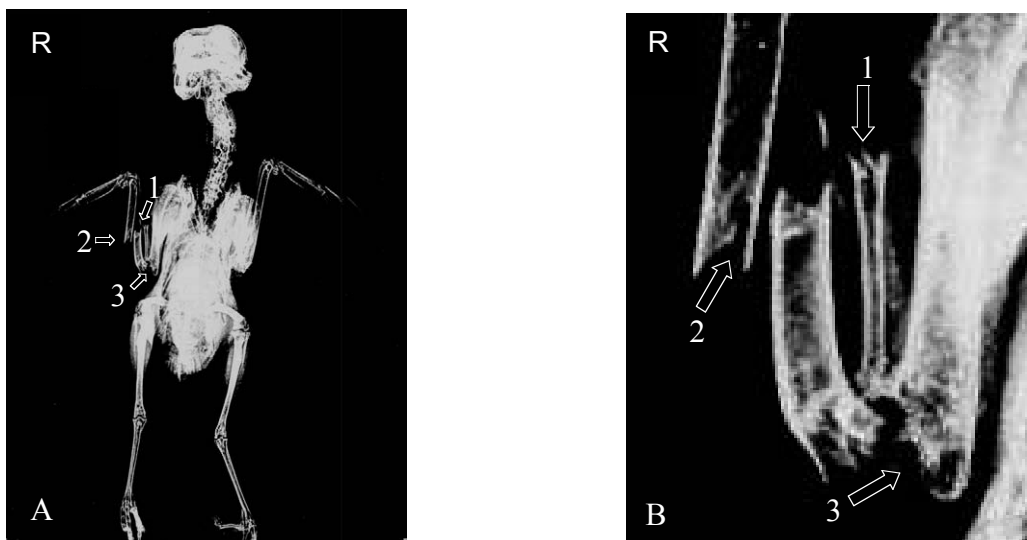


Fig. 2. Triple skeletal fracture of wing of a road-killed Nutcracker from southern Poland. A) general view, B) magnification. Numbered arrows are: 1 – middle shaft of the radius, 2 – middle shaft of the ulna, 3 – fracture of the lateral epicondyle of the humerus, R – right side of the body.

more often than those of ulna. A reason for this may be the location of the radial bone cranially to ulna and its smaller size. The more frequent fractures of the tibiotarsus than of the tarsometatarsus may be explained by the smaller robust size of the tarsometatarsus, and the ability to absorb and thereby lessen the force of impact by having more flexibility (mobility) associated with the articulations of the tarsometatarsus with the proximal tibiotarsus and distal metatarsals.

Multiple fractures of long bones in both wings and legs, noted in some individuals, as well as high percentage of House Sparrows with injuries (75%) suggest that they were hit directly by approaching cars. It cannot be ruled out that some of the birds without bone injuries could be killed as a result of collision with the sides of the passing vehicle rather than by a head-on collision, or because of the strong gust formed around the car. This seems to be especially true for swallows (which comprise 40% of the birds with injuries in this study) which often fly along roads, near passing cars, searching for food (Hobson & Sealy 1987).

The results of the present study did not show fractures of the skull, jaw and maxilla, which are the most common bone injuries in tower and window collision victims (Klem 1990, Veltri & Klem 2005). In Pennsylvania, amongst 502 tower- and window-killed birds, 13% sustained skeletal injuries of the head (Veltri & Klem 2005).

The most often self-healed, and therefore not fatal fractures noticed in wild living birds are the fractures of sternum and clavicles. Among passerines, the highest percentage of healed fractures was found in the representatives of Turdidae (up to 48% in urban Blackbirds *Turdus merula*, n = 214 individuals). Fractures of bones of wings and legs formed only a small percentage of all cases of healed bone injuries (Wokac 1990), which may be the proof of the large mortality of birds with these injuries. Cases of fracture repair were also recorded in wild large birds of prey. In Eastern Africa, in three of 14 examined vulture specimens (*Gyps africanus* and *G. rueppellii*), signs of healed ulnar injuries were found (Houston 1993).

ACKNOWLEDGEMENTS

We are grateful to Professor Daniel Klem Jr. (Department of Biology of Muhlenberg College,

USA), Professor Dr. hab. Andrzej Dyrz and Dr. Konrad Hałupka (Wrocław University), Dr. Tomasz Osiejuk (Adam Mickiewicz University in Poznań) and an anonymous referee for valuable remarks on the editing of this paper. Further thanks are due to Dr. Wojciech Atamaniak (Agricultural University of Wrocław) for translating and Dr. Kenneth A. Monsch (Wrocław University) and Marcin Sęk for editing the English version of the text. We are thankful to Krzysztof Martini and Paweł Gębski for help in data collection.

REFERENCES

- Beregi A., Molnar V., Felkei F., Szentgali Z. 1999. Diagnostic radiology of pet and wild birds, review. Radiographic techniques and radiographs of healthy birds. *Acta Vet. Hungarica* 47: 291–302.
- Brandwood A., Jayes A., Alexander R. 1986. Incidence of healed fracture in the skeletons of birds, molluscs and primates. *J. Zool.* 208: 55–62.
- Clausen B., Gudmundsson F. 1981. Causes of mortality among free-ranging gyrfalcons in Iceland. *J. Wildlife Dis.* 17: 105–109.
- Clevenger A. P. 2000. Effects of highways and other linear developments on wildlife populations. A literature collection. Banf National Park, Canada. (available: <http://www.cmiae.org/biblio.html>).
- Clevenger A. P., Chruszcz B., Gunson K. 2003. Spatial patterns and factors influencing small vertebrate fauna road-kill aggregations. *Biol. Conserv.* 109: 15–26.
- Cramp S. (ed.). 1998. The complete birds of the Western Palearctic on CD-ROM. Oxford Univ. Press.
- Erritzoe J., Mazgajski T. D., Rejt Ł. 2003. Bird casualties on European roads — a review. *Acta Ornithol.* 38: 77–93.
- Ferens B. 1971. [The Guides for identification of vertebrates of Poland]. Part IV A-B. Birds — Aves, vol. 1–2, Warszawa/Kraków.
- Hebert E., Reese E. (eds). 1995. Avian collision and electrocution, An annotated bibliography. California Energy Commission. Publication Number, P700-95-001. (available: http://www.energy.ca.gov/reports/avian_bibliography.html).
- Hobson K. A., Sealy S. 1987. Foraging, scavenging and other behaviour of swallows on the ground. *Wilson Bull.* 99: 111–116.
- Houston D. C. 1993. The incidence of healed fractures to wing bones of White-backed and Ruppell's Griffon Vultures *Gyps africanus* and *Gyps rueppellii* and other birds. *Ibis* 135: 468–469.
- Klem D. Jr. 1990. Bird injuries, cause of death, and recuperation from collisions with windows. *J. Field Ornithol.* 61: 115–119.
- Lidauer R. M. 1983. [Bone fractures in urban Blackbirds]. *Ökologie der Vögel* 5: 111–126.
- Lode T. 2001. Effect of a motorway on mortality and isolation of wildlife populations. *Ambio* 29: 163–166.
- North Carolina Raptor Center (available: <http://www.carolinaraptorcenter.org/stats.php>)
- Orłowski G., Nowak L. 2004. Road mortality of hedgehogs *Erinaceus* spp. in farmland in Lower Silesia (south-western Poland). *Pol. J. Ecol.* 52: 369–374.
- Underhill J. E., Angold P. 2000. Effects of roads on wildlife in an intensively modified landscape. *Environ. Rev.* 8: 21–39.


- Veltri C. J., Klem D. Jr. 2005. Comparison of fatal bird injuries from collisions with towers and windows. *J. Field Ornithol.* 76: 127–133.
- Wendell M. D., Sleenan J., Kratz G. 1999. Retrospective study of morbidity and mortality of raptors admitted to Colorado State University Veterinary Teaching Hospital during 1995 to 1999. *J. Wildlife Dis.* 38: 101–106.
- Wokac R. M. 1990. [Healed fractures of skeleton of European bird species]. *Ökologie der Vögel* 12: 175–203.

STRESZCZENIE

[Uszkodzenia układu kostnego ptaków wróblowych zabitych przez samochody]

Pomimo, że tematyka dotycząca śmiertelności ptaków na drogach poruszana była wielokrotnie, w literaturze brak jest szczegółowych informacji poświęconych uszkodzeniom ptaków na skutek kolizji z pojazdami. Analiza radiologiczna zabitych przez samochody 35 ptaków (17 gatunków),

wykazała uszkodzenia układu kostnego u 17 (49%) osobników (Fig. 1). Ogółem rozpoznano 30 uszkodzeń układu kostnego (Tab. 1). W 29 przypadkach uszkodzenia dotyczyły złamań kości długich w obrębie skrzydeł ($n = 15$) i kończyn dolnych ($n = 14$). W jednym przypadku stwierdzono nadwichnięcie kręgosłupa (Tab. 1). Złamania skrzydeł dotyczyły kości ramiennej ($n = 6$), promieniowej ($n = 6$) oraz łokciowej ($n = 3$) (Fig. 2A i 2B). Uszkodzenia kończyn dolnych to złamania kości udowej ($n = 5$), piszczelowo-śródstępowej ($n = 8$) oraz stępowo-śródstępowej ($n = 1$). Nie stwierdzono związku pomiędzy masą ciała ofiar a pojawieniem się uszkodzenia układu kostnego, ani liczbą doznanych złamań. Charakter i rodzaj opisanych uszkodzeń szkieletu w zdecydowanej większości przypadków wskazywał, że nie były one bezpośrednią przyczyną śmierci ptaków.



T. Cofta