

## **Medical Intervention and Rehabilitation of a Northern Tamandua (*Tamandua mexicana*) with Traumatic Head Injury**

Authors: Paquet-Durand, Isabelle, Pohlin, Friederike, Baron, Ella, Kollias, George V., and Boesch, Jordyn M.

Source: *Edentata*, 15(2014) : 60-65

Published By: IUCN/SSC Anteater, Sloth and Armadillo Specialist Group

URL: <https://doi.org/10.5537/020.015.0109>

---

BioOne Complete ([complete.BioOne.org](https://complete.BioOne.org)) is a full-text database of 200 subscribed and open-access titles in the biological, ecological, and environmental sciences published by nonprofit societies, associations, museums, institutions, and presses.

Your use of this PDF, the BioOne Complete website, and all posted and associated content indicates your acceptance of BioOne's Terms of Use, available at [www.bioone.org/terms-of-use](https://www.bioone.org/terms-of-use).

Usage of BioOne Complete content is strictly limited to personal, educational, and non-commercial use. Commercial inquiries or rights and permissions requests should be directed to the individual publisher as copyright holder.

---

BioOne sees sustainable scholarly publishing as an inherently collaborative enterprise connecting authors, nonprofit publishers, academic institutions, research libraries, and research funders in the common goal of maximizing access to critical research.

## CASE REPORT

# Medical intervention and rehabilitation of a northern tamandua (*Tamandua mexicana*) with traumatic head injury

ISABELLE PAQUET-DURAND<sup>A</sup>, FRIEDERIKE POHLIN<sup>A</sup>, ELLA BARON<sup>B,1</sup>,  
GEORGE V. KOLLIAS<sup>C</sup> AND JORDYN M. BOESCH<sup>C</sup>

<sup>A</sup> Belize Wildlife and Referral Clinic, George Price Highway 68, Central Farm, Belize. E-mail: [ipaquet@belizewildlifeclinic.org](mailto:ipaquet@belizewildlifeclinic.org) (IPD),  
E-mail: [friederike.pohlin@gmail.com](mailto:friederike.pohlin@gmail.com) (FP)

<sup>B</sup> Tamandua Refuge at Ian Anderson's Caves Branch Jungle Lodge, Mile 41,5 Humminbird Hwy. P.O. Box 356, Belmopan, Belize.  
E-mail: [ellabaron@yahoo.com](mailto:ellabaron@yahoo.com)

<sup>C</sup> Department of Clinical Sciences, College of Veterinary Medicine, Cornell University, Ithaca, 14853-6401, NY, USA.  
E-mail: [gvk2@cornell.edu](mailto:gvk2@cornell.edu) (GVK), [jmb264@cornell.edu](mailto:jmb264@cornell.edu) (JMB)

<sup>1</sup> Corresponding author, [tamanduarefuge@gmail.com](mailto:tamanduarefuge@gmail.com)

**Abstract** An adult female tamandua (*Tamandua mexicana*) was found in a yard near an area of high vehicular traffic in Belize. Severe cephalic trauma implied a possible collision or an episode of human-wildlife conflict. The anteater sustained a traumatic injury that led to a fracture of the skull and loss of the right eye. Two surgeries, including evisceration of the eye, enucleation and tarsorrhaphy, were performed using different anesthetic protocols. Neurologic signs were pronounced at first, but disappeared with the course of treatment. Rehabilitation is described. The tamandua was released in a suitable area three months after initial presentation.

**Keywords:** anesthesia, anteater, prolapsed eye, rehabilitation, skull fracture, trauma

### Tratamiento médico y rehabilitación de un tamandúa (*Tamandua mexicana*) con trauma craneano

**Resumen** Una hembra adulta de tamandúa (*Tamandua mexicana*) herida fue hallada en un jardín cerca de una carretera muy frecuentada en Belice. El trauma craneano indicaba un accidente vehicular o un conflicto entre la fauna silvestre y humanos. La tamandúa había sufrido trauma que causó la fractura del cráneo y la pérdida del ojo derecho. Se realizaron dos cirugías incluyendo la evisceración, enucleación y la tarsorrhafia del ojo, con protocolos anestésicos distintos. Los signos neurológicos fueron significativos al inicio pero desaparecieron con el tratamiento. El animal fue liberado en un área protegida tres meses después del rescate.

**Palabras clave:** anestesia, fractura del cráneo, hormiguero, prolapso del ojo, rehabilitación, trauma

## INTRODUCTION

The northern tamandua (*Tamandua mexicana*) is a medium-sized anteater inhabiting forests from southern Mexico, through Central America to western Colombia, Venezuela, Ecuador, and the northwestern corner of Peru (Navarette & Ortega, 2011). Four subspecies of *T. mexicana* are currently recognized, including *T. m. mexicana*, which occurs in Belize (Navarette & Ortega, 2011). The northern tamandua is currently listed as "Least Concern" (LC) by the IUCN Red List of Threatened Species because of its wide distribution and large population (Ortega

Reyes *et al.*, 2014). Vehicular trauma represents a major threat to these animals and deaths are reported throughout Central and South America (Monge-Najera, 1996; Pinowski, 2005; Martinelli & Volpi, 2011; Catzefflis & de Thoisy, 2012; Payan *et al.*, 2013; Seijas *et al.*, 2013; Ortega Reyes *et al.*, 2014).

Human-wildlife conflict is a global threat to wildlife (Distefano, 2009). Deliberate killing of wildlife perceived as pests has taken place on all continents (Woodroffe *et al.*, 2005). In wildlife rehabilitation centers, head trauma was the third most common injury seen in all species of wildlife, and

categorized as a major cause for non-releasable animals (Casey & Casey, 2000). The authors aim to provide step-by-step documentation of the treatment and rehabilitation process after head trauma in a tamandua, and to emphasize the importance of rapid medical intervention to improve the individual's chances of survival and release.

### CASE REPORT

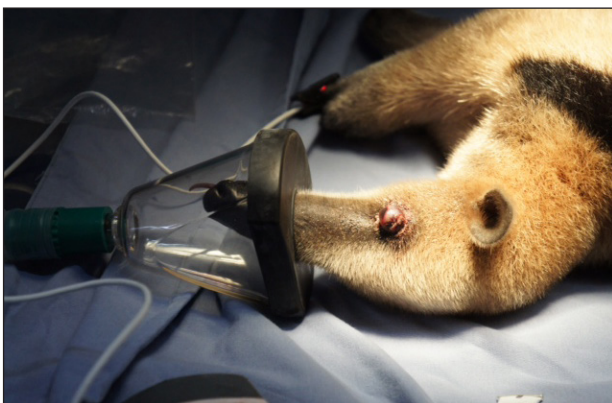
An adult 4.5 kg female *T. mexicana* was rescued by ACES (American Crocodile Education Sanctuary) on Ambergris Caye, Belize and then transferred to the "Tamandua Refuge" (day one). The prostrate anteater had been found by a member of the public in a yard next to a high-traffic road. The tamandua was quickly transported to the near-by Belize Zoo, where international wildlife veterinarians were visiting. During transport the animal was kept warm by the rescuer.

### INITIAL CLINICAL FINDINGS

On presentation the tamandua appeared obtunded (mostly unconscious and only responding briefly to painful stimuli) with little movement, had shallow breathing, and held its mouth open with a protruding tongue. The animal reacted to manipulation and injection with brief periods of weak and disoriented activity. Physical exam findings included a rectal temperature of 35.2 °C and a small (4 × 4 mm) darkened area over the left temporal region of the cranium. The right eye-globe was proptosed (displaced forward) and protruded from the skull (FIG. 1). The tamandua was bleeding (serosanguinous nasal discharge) from the right nostril and was unable to completely close its mouth. No palpable fractures of the skull, spine or extremities were found.

### INITIAL TREATMENT

Upon presentation, the tamandua was considered stable enough to be anesthetized. Further



**FIGURE 1.** Northern tamandua (*Tamandua mexicana*) with head trauma on presentation (day 1), during anesthetic maintenance via face mask. Note the proptosed globe of the right eye. Photograph by Ella Baron.

assessment and surgery was determined to be necessary. Manipulation of the injured eye would have been severely painful and there was a high risk for further injury and bleeding without removal of the proptosed globe. The risk of neurologic shock was felt to outweigh anesthetic risk. The animal was given 4 mg/kg ketamine HCl (Vetalar, 100 mg/ml; Fort Dodge Laboratories, Fort Dodge, Iowa, USA) and 0.04 mg/kg dexmedetomidine (Dexdomitor, 0.5 mg/ml; Orion Pharma, Orion Corp., Espoo, Finland) in the muscle mass of the upper right rear leg. Fourteen minutes post-injection, the tamandua became immobile. The heart rate was 82 beats per minute (bpm), and respiratory rate was 15 breaths per minute. The tamandua was maintained on 1% isoflurane (Piramal Healthcare Limited, Digwal Village, India) and 1.5–2 l/min oxygen via facemask (FIG. 1) due to the unique skull and mouth anatomy.

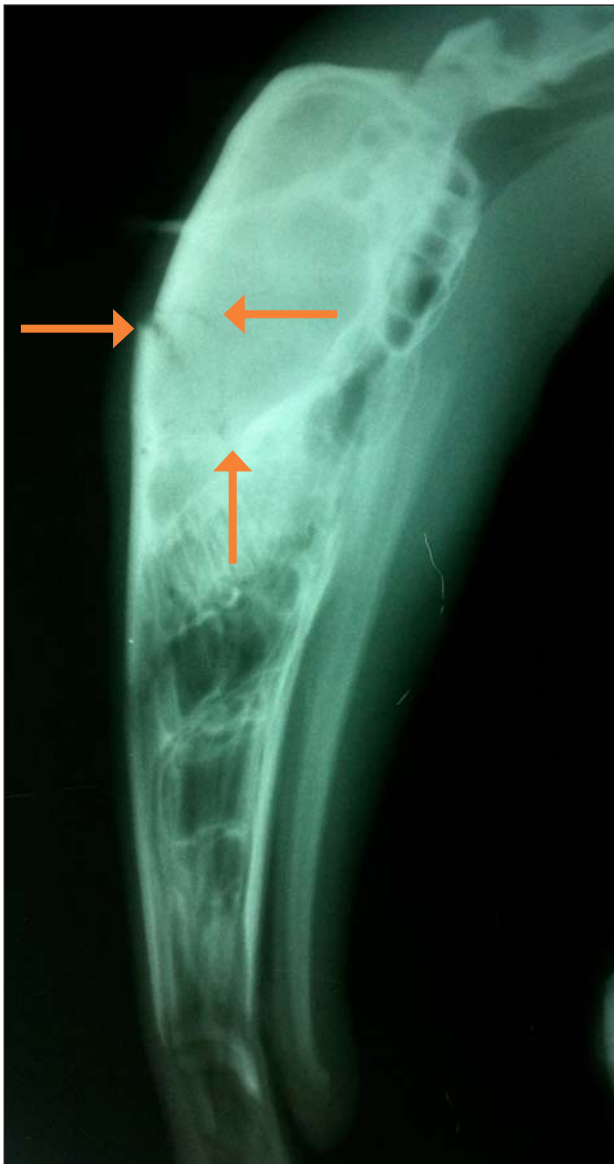During this initial procedure, only the most urgent, quicker and less traumatic eye evisceration procedure was performed. The enucleation was left for a second surgery, once the animal had been further stabilized. During the initial procedure, the liquid contents of the right globe were aspirated and the remaining contents surgically removed. The sclera and extraocular muscles were left intact. The collapsed globe was flushed with sterile saline and repositioned in its orbit. A temporary tarsorrhaphy was performed over the remaining tissues. The eyelids were sutured closed with a single horizontal mattress suture using absorbable 3-0 PDS suture.

During the procedure, 150 ml of lactated Ringer's solution were given subcutaneously in the right and left inguinal region. Meloxicam at a dose of 0.5 mg/kg (Metacam, 1.5 mg/ml; Boehringer Ingelheim Vetmedica, Inc., St Joseph, USA) and 6.6 mg/kg long-acting (96 h) ceftiofur (Excede, 200 mg/ml; Pfizer Inc., New York, USA) were given subcutaneously as anti-inflammatory and antibiotic, respectively. Once the isoflurane was discontinued, the dexmedetomidine was reversed with 0.1 mg/kg atipamezole (Antisedan, 1 mg/ml; Orion Pharma, Orion Corp., Espoo, Finland) administered by intramuscular injection. A second injection at the same dose was used 20 min later to fully reverse the effect of the sedative. Tongue withdrawal and very limited body movements were present 20 min following the second application of the reversal agent. The patient remained sedated and calm, apparently sleeping for the remainder of day one.

### INTENSIVE CARE

Post-surgery, the anteater was taken to the "Tamandua Refuge" where it was placed under intensive care. For the first six days, the tamandua was held around the clock by a rehabilitator in order to monitor breathing and provide warmth. It showed bilateral serosanguinous discharge and appeared

obtunded. Warm water compresses were applied over the right eye for 10 min three times daily, and bandages were placed on all four paws over-night to prevent manipulation of the surgical wound. On day two meloxicam was not repeated due to dehydration and a concern for renal compromise. A 50 cm × 70 cm × 55 cm sized indoor enclosure provided the tamandua with soft bedding, warmth, and restricted movement. Thirty ml of a blend of mashed avocado, banana, puppy milk formula (Just Born Highly digestible Milk Replacer, Farnam Companies Inc., Phoenix, USA), coconut water, watermelon juice, papaya, and orange juice diluted in water were offered to the tamandua in a syringe every one to two hours. The rehabilitator massaged the tamandua's throat to encourage swallowing while feeding.



**FIGURE 2.** Radiograph with a laterolateral view on the tamandua's skull. A fracture of the frontal and parietal bone is visible (arrows). Photograph by Isabelle Paquet-Durand.

Due to inactivity and depressed vital status, the anteater was presented to the consulting veterinarians two days after the first surgery. On day three, 0.25 mg/kg meloxicam and 15 ml of lactated Ringer's solution were administered subcutaneously.

### FURTHER DIAGNOSTICS AND TREATMENTS

On day four the tamandua was taken to the national specialized wildlife medical facility, the Belize Wildlife and Referral Clinic (BWRC), in order to obtain radiographs and continue treatment. The tamandua remained severely depressed and obtunded. It was sleeping continuously (estimated at least 23 hours daily) and waking up only periodically for a few minutes at a time. Radiographs revealed a skull fracture of the frontal and parietal bones involving the ethmoid (**FIG. 2**). Continued drainage from the surgery site was observed and long-acting antibiotics (ceftiofur) were repeated at the same dose as used initially. Oral B complex-vitamins (Compleland B12, 320 g/ml; Laboratorios Veterland Ltd., Bogotá, Colombia) were added to the daily treatment schedule at a dose of 0.5 ml for 10 days. As the animal's hydration status improved, meloxicam was continued at a dose of 0.2 mg/kg orally every other day after day four. The prognosis for full recovery was questionable at this time, but the veterinary team decided to provide treatment for at least one week before re-assessing the head trauma.

On day nine, the antibiotic was changed to 5 mg/kg enrofloxacin (Enrofland, 100mg/ml; Laboratorios Veterland Ltd., Bogotá, Colombia) and administered orally once daily. The meloxicam was continued at 0.1 mg/kg orally every other day. A bacterial culture of the surgery site was performed and found to be inconclusive.

### REHABILITATION

The tamandua was provided a 200 cm × 200 cm × 150 cm indoor enclosure after seven days at the sanctuary. This enclosure was enriched with termite nest-laden trees, and an elevated nest-box for shelter. On day seven, the tamandua's behavior started improving and for the first time it awoke for one hour. On day eight it awoke for several hours, and in the following days it became increasingly alert and active for more hours of the day. On day nine it started taking food on its own. The rehabilitator tried a variety of juices, coconut water, puppy formula and coconut oil mixed with other foods to facilitate oral application of medication to the anteater. When the medications were mixed with mashed avocado and coconut oil the tamandua swallowed the prescribed medications on its own.

Gradually the animal was introduced to a 7 m × 10 m × 5 m sized outdoor enclosure, starting with one

hour per day on day 10. This enclosure had a high density of plants inside it and layers of fabric were stretched from wall to wall, allowing the tamandua to move and climb but preventing it from falling to the ground. Additional termites and powdered dog food were added to the diet. The injured eye was cleaned and treated with antibiotic ointment on a daily basis. As the tamandua became more active, it demonstrated further neurological signs including walking in circles, bumping into trees, and disorientation. Although tree-climbing ability remained unaffected, it appeared to experience dysmetria (difficulty estimating the distance between branches).

Both enclosures were modified to provide soft padding and additional support to prevent further trauma. The tamandua's level of activity increased, and the neurologic signs ameliorated over time. Food and water ingestion as well as daily output increased over time. Neurologic signs resolved by day 16. By this time the animal moved and ate normally, and spent four to six hours a day in the outdoor enclosure. The tamandua continued to show gradual signs of improvement in the subsequent weeks.

#### FURTHER SURGICAL TREATMENT

The enucleation and permanent tarsorrhaphy surgery were performed at the BWRC 53 days after initial presentation. The tamandua was placed in an induction chamber with 4% isoflurane for anesthetic induction. The animal was maintained under anesthesia with 3.5 to 4% isoflurane and oxygen via face-mask throughout the procedure. Average heart rate was 76 bpm (range 64–140), average respiratory rate was 22 breaths per minute (range 10–28), and average body temperature was 34.3 °C (range 33.6–35.7 °C). All remaining structures of the right eye globe were removed and the eyelids were permanently sutured closed. Additionally, 16 bot-fly larvae (*Oestridae*) were removed from the dorsal subcutaneous tissue. The total time of gas-anesthesia was 118 min. During the procedure, 0.2 mg/kg meloxicam and 10 mg/kg amoxicillin (Zoobiotic, 150 mg/kg; Laboratorios Calier S. A., Barcelona, Spain) were given by subcutaneous injection. Normal body movements were present within 15 min after discontinuing the anesthetic gas. The tamandua was fully awake after one hour.

#### FOLLOW UP AND RELEASE

Following second surgery, the tamandua was given oral meloxicam (0.1 mg/kg) once daily for five days and 10 mg/kg amoxicillin (Andimox, 50 mg/ml; Laboratorios Andifar, Tegucigalpa, Honduras) orally once daily for ten days. The tamandua took all medications voluntarily with coconut-water. No redness or discharge was present at the surgical site. After the procedure the eye remained slightly swollen for 12 days.



**FIGURE 3.** Fully recovered tamandua after approximately three months of rehabilitation, climbing one of the trees in the outside-enclosure in order to forage. Photograph by Ella Baron.

The tamandua continued gaining weight and strength. Seven days after the second surgery (day 62) it was moved permanently into an outdoor enclosure designed for pre-release conditioning. The tamandua was very active. It climbed trees (**FIG. 3**), dug in the ground and foraged for insects. The animal did not use a nest box provided, and chose to sleep in alternate sites.

For two weeks prior to release, daily two-hour observations were conducted. Thereafter the tamandua was observed for two full days, and morphometric measurements were taken. Observers assessed its climbing abilities, orientation, coordination, sleeping pattern, sense of smell, audio awareness, and recognition of human presence. Measurements included the length from the tip of the nose to the base of the neck (20 cm), the length from the base of the neck to the base of the tail (40.5 cm), and the length of the tail (56 cm). No signs of discomfort, inability to run, walk, climb, or forage were observed.

The tamandua was released into a protected area 85 days after presentation. After three hours of foraging and exploring its surroundings, the animal left the area. Ten months later and on two occasions, observers reported a tamandua with similar markings in the vicinity of the release site. Unfortunately, photographs could not be taken and the missing eye was not verifiable. However, both observers were confident that the coloration and tail markings were the same as those of the released animal.

#### DISCUSSION

The location where the tamandua was found and the nature of its head trauma indicated that its injuries were likely inflicted by a car or a human. Reports throughout much of Latin America indicate that tamanduas are often victims of vehicular fatalities. In Costa Rica, tamanduas are one of the two species most often killed by vehicles (Monge-Najera,

1996). In Colombia they are the most impacted vertebrate species, accounting for 27% of vehicle deaths (Payan *et al.*, 2013). Seijas *et al.* (2013) recently confirmed that vehicle collision is still the main cause of tamandua mortality in Venezuela. Catzefflis & de Thoisy (2012) report similar findings in French Guyana, and in Espirito Santo, Brazil, the tamandua represents 3.64% of mammals killed by cars (Martinelli & Volpi, 2011). Monge-Najera (1996) and other researchers suggest that the high vehicle mortality rate is due to the tamandua's slow movement. To make matters more difficult for the slow anteater species, Bertassoni (2012) suggests that superstition may encourage vehicle mortality, at least in giant anteaters (*Myrmecophaga tridactyla*), as they are considered bad omens.

Neurological signs were expected due to head trauma. Successful treatment of severe cephalic trauma, rehabilitation and release had never been reported for anteaters in Belize. A case report by Oliveira *et al.* (2009) describes similar signs in a giant anteater (*M. tridactyla*) that had suffered similar cranial trauma. The animal was given dexamethasone once daily, and the neurologic signs decreased by the fifth day. However, the anteater died after one week of intensive care. Marked cerebral edema and discrete epidural hemorrhage were found in a post-mortem exam. Use of dexamethasone in wildlife with head trauma is generally recommended because of its potent anti-inflammatory effect (Stout, 2002). Notably, steroid use in human medicine seems to increase mortality for unknown reasons (Alderson & Roberts, 2009). In this case, meloxicam was successfully used as an anti-inflammatory drug. In contrast to the report by Oliveira *et al.* (2009), our treatment focused not only on the head trauma but also on the proptosed eye of the anteater. Antibiotic coverage was required to prevent infection. Long-acting antibiotics minimized the number of applications to once every 96 h. Ceftiofur appeared to provide adequate antibiotic coverage, but as an injectable it was inconvenient and caused an aversive response by the animal. Therefore the antibiotic was switched to oral enrofloxacin on day nine to reduce stress to the animal.

Two surgeries including evisceration of the globe and tarsorrhaphy were performed using different anesthetic protocols. For the first surgical procedure, the recommended dose of ketamine and dexmedetomidine was used (West *et al.*, 2007). The animal was maintained on isoflurane throughout the procedure, allowing anesthetic control of a prolonged procedure. Due to the special anatomic features of anteaters, orotracheal intubation is very difficult (West *et al.*, 2007; Martínez-Giménez, 2013). The anesthetic gas was therefore provided via facemask in both events. Even though atipamezole was used to antagonize the  $\alpha$ -adrenergic dexmedetomidine,

the recovery time of the tamandua was prolonged. Head trauma was the likely cause for depression, lethargy and sleepiness after surgery. For the second procedure, the anteater was placed in an induction chamber with a 4% isoflurane and oxygen mix at a constant rate. This method seems to be preferred in smaller species of xenarthrans because it causes less physiological alterations (West *et al.*, 2007; Carregaro *et al.*, 2009).

The mean heart rate was higher when induced with injectable anesthetics than when only inhalant anesthesia was used, but bradycardia was present during both procedures. The normal heart rate of an anteater lies between 110 and 160 bpm (West *et al.*, 2007; Carregaro *et al.*, 2009). The respiratory rate remained within the normal range of 10–30 breaths per minute (West *et al.*, 2007; Carregaro *et al.*, 2009). All xenarthrans are known to be "heterotherm", experiencing high fluctuations in body temperature depending on environment and air temperature, especially in periods of inactivity (Fournier-Chambrillon *et al.*, 1997).

Minimum Standards for Wildlife Rehabilitation (Miller, 2012) and Hall's (2005) checklist for animals considered for release were followed. These standards include the presence of adequate fight or flight response, appropriate interaction with conspecifics, as well as further consideration concerning the release site, time, and regulations. Also, the animals must be able to acquire and process food, find or construct nests and shelters, and orient and navigate in a complex environment. Territorial species must define their range limits (Hall, 2005). Hall (2005) suggests that the patient's behavior be benchmarked by that of a healthy individual and physiotherapy be performed to assist the animal in regaining strength. In our case, the tamandua was introduced to an outside enclosure with gradually increasing outdoor activity. The enclosure was large enough to allow the animal to exercise. The outdoor enclosure was enriched with termite-laden trees, thus stimulating foraging. The tamandua responded within normal ranges for each activity. Since the anteater was injured as an adult it could be assumed that it had learned to live independently prior to its injury.

Successful surgery, rehabilitation and release after severe cephalic trauma have rarely been reported in tamanduas, even anecdotally. Despite losing an eye, the medical team concluded that the anteater would be a suitable candidate for release. This was in part due to strong reliance on its sense of smell. After three months of rehabilitation the tamandua was released in a suitable nearby area and observed foraging normally for three hours before it climbed out of sight. Unfortunately no identification-markers were available to monitor the long-term success, but two sightings of a similar looking tamandua within the area of release give hope that this patient continues to thrive in the release area.

## ACKNOWLEDGEMENTS

The authors would like to thank the Belize Zoo for enabling the initial evaluation and treatment of the tamandua with the help of the co-authors Drs. Kollias and Boesch; the Belize Wildlife and Referral Clinic and its professional interns, Dr. Angela Gimmel and Dr. Jennifer Riley for their assistance with procedures; and Ian Anderson's Caves Branch Jungle Lodge for providing the "Tamandua Refuge". Thank you to the Summerlee Foundation for the grant support for free medical care for injured Wildlife at the Belize Wildlife & Referral Clinic in 2013.

## REFERENCES

- Alderson, P. & I. Roberts. 2009. Corticosteroids for acute traumatic brain injury (Review). The Cochrane Library 3: 1–27.
- Bertassoni, A. 2012. Perception and popular reports about giant anteaters (*Myrmecophaga tridactyla* Linnaeus, 1758) by two Brazilian traditional communities. *Edentata* 13: 10–17.
- Carregaro, A. B., P. M. Gerard & D. K. Honscho. 2009. Allometric scaling of chemical restraint associated with inhalant anesthesia in giant anteaters. *Journal of Wildlife Diseases* 45: 547–551.
- Casey A. M. III & S. J. Casey. 2000. A survey of conditions seen in wildlife admitted for wildlife rehabilitation. Pp. 143–160 in: *Wildlife rehabilitation*, Volume 18 (D. R. Ludwig, ed.). National Wildlife Rehabilitators Association, St. Cloud, MN.
- Catzefflis, F. & B. de Thoisy. 2012. Xenarthrans in French Guiana: a brief overview of their distribution and conservation status. *Edentata* 13: 29–37.
- Distefano, E. 2009. FAO – Food and Agricultural Organization of the United Nations. Human-wildlife conflict worldwide: collection of case studies, analysis of management strategies and good practices. <[http://www.fao.org/SARD/common/ecg/1357/en/HWC\\_final.pdf](http://www.fao.org/SARD/common/ecg/1357/en/HWC_final.pdf)>. Downloaded on 15 March 2012.
- Fournier-Chambrillon, C., P. Fournier & J-C. Vié. 1997. Immobilization of wild collared anteaters with ketamine- and xylazine-hydrochloride. *Journal of Wildlife Diseases* 33: 795–800.
- Hall, E. 2005. Release considerations for rehabilitated wildlife. Proceedings of the National Wildlife Rehabilitation conference, Gold Coast, Australia.
- Martinelli, M. M. & T. A. Volpi. 2011. Mamíferos atropelados na Rodovia Armando Martinelli (ES-080), Espírito Santo, Brazil. *Natureza Online* 9: 113–116.
- Martínez-Giménez, J. 2013. Giant anteater anatomy: tracheostomy as an alternative to intubation. European Association of Zoo and Wildlife Veterinarians Student Workshop, Kormarden.
- Miller, E. A. 2012. Minimum standards for wildlife rehabilitation. National Wildlife Rehabilitators Association, 4<sup>th</sup> Edition. National Wildlife Rehabilitation Association, St. Cloud, Minnesota. 116 pp.
- Monge-Najera, J. 1996. Vertebrate mortality on tropical highways: the Costa Rican case. *Vida Silvestre Neotropical* 5: 154–156.
- Navarrete, D. & J. Ortega. 2011. *Tamandua mexicana* (Pilosa: Myrmecophagidae). *Mammalian Species* 43: 56–63.
- Oliveira, F. S., P. F. G. Carvalho, M. H. B. Camargo, A. Delfini & L. L. Martins. 2009. Vestibular syndrome in giant anteater (*Myrmecophaga tridactyla*). *Ciências Agrárias* 30: 683–686.
- Ortega Reyes, J., D. G. Tirira, M. C. Arteaga & F. Miranda. 2014. *Tamandua mexicana*. The IUCN Red List of Threatened Species. Version 2014.2. <<http://www.iucnredlist.org/>>. Downloaded on 29 September 2014.
- Payan, E., C. Soto, A. Diaz-Pulido, A. Benítez & A. Hernández. 2013. Wildlife road crossing and mortality: lessons for wildlife friendly road design in Colombia. Proceedings of the International Conference on Ecology and Transportation, Scottsdale, Arizona.
- Pinowski, J. 2005. Road kills of vertebrates in Venezuela. *Revista Brasileira de Zoologia* 22: 191–196.
- Seijas, A. E., A. Araujo-Quintero & N. Velásquez. 2013. Vertebrate mortality in the Guanare-Guaranito road, Portuguesa state, Venezuela. *Revista de Biología Tropical* 61: 1619–1636.
- Stout, H. 2002. Head trauma. Pp. 4.71–4.72 in: *NWRA principles of wildlife rehabilitation* (A. T. Moore & S. Joosten, eds.). National Wildlife Rehabilitation Association, St. Cloud, Minnesota.
- West, G., T. Carter & J. Shaw. 2007. Edentates (Xenarthra). Pp. 349–353 in: *Zoo animal and wildlife immobilization and anesthesia* (G. West, D. Heard & N. Caulkett, eds.). Blackwell Publishing, Iowa, Ames.
- Woodroffe, R., S. Thirgood & A. Rabinowitz. 2005. *People and wildlife, conflict or co-existence*. Cambridge University Press.

Received: 15 August 2014; Accepted 4 October 2014