

**AN EARLY UNILATERAL THYMIC LYMPHOMA IN A
POSTIRRADIATED WHITE-FOOTED MOUSE,
Peromyscus leucopus ***

Authors: COSGROVE, G. E., DIGREGORIO, D., and DUNAWAY, P. B.

Source: Journal of Wildlife Diseases, 10(1) : 32-33

Published By: Wildlife Disease Association

URL: <https://doi.org/10.7589/0090-3558-10.1.32>

BioOne Complete (complete.BioOne.org) is a full-text database of 200 subscribed and open-access titles in the biological, ecological, and environmental sciences published by nonprofit societies, associations, museums, institutions, and presses.

Your use of this PDF, the BioOne Complete website, and all posted and associated content indicates your acceptance of BioOne's Terms of Use, available at www.bioone.org/terms-of-use.

Usage of BioOne Complete content is strictly limited to personal, educational, and non - commercial use. Commercial inquiries or rights and permissions requests should be directed to the individual publisher as copyright holder.

BioOne sees sustainable scholarly publishing as an inherently collaborative enterprise connecting authors, nonprofit publishers, academic institutions, research libraries, and research funders in the common goal of maximizing access to critical research.

AN EARLY UNILATERAL THYMIC LYMPHOMA IN A POSTIRRADIATED WHITE-FOOTED MOUSE, *Peromyscus leucopus**

G. E. COSGROVE, D. DIGREGORIO¹ and P. B. DUNAWAY,² Biology Division
and Ecological Sciences Division, Oak Ridge National Laboratory, Oak Ridge,
Tennessee 37830, U.S.A.

Abstract: An early unilateral thymic lymphoma was found in one of 12 white-footed mice, *Peromyscus leucopus*, 7 months after 950 rads of whole-body irradiation.

Thymic lymphoma occurs frequently in some strains of laboratory mice as a delayed effect of ionizing irradiation exposure. It is rarely encountered in other species of animals,³ and has not been reported in the white-footed mouse, *Peromyscus leucopus*. A histological study of the organs of 12 white-footed mice was made 7 months after a whole-body dose of 950 rads of ⁶⁰Co gamma irradiation. The radiation was administered at a dose rate of 6.5 rad/sec in a GammaCell 200 (Atomic Energy of Canada, Ltd.) to young adult white-footed mice born and raised in the laboratory. The mice were kept under

standard colony conditions and used in a fertility experiment involving caging of one female with one male.¹ Histologically, restoration of hemopoietic organs was seemingly complete, except that the paired thymuses of all were still atrophic (Fig. 1). In one white-footed mouse with a developing unilateral thymic lymphoma, one thymus was atrophic and the other was markedly enlarged. This thymus showed a massive deposition of cortical lymphocytic cells, with some invasion through the capsule but no other local or distant extension (Fig. 2). The only other lesion in this female was radiation-induced ovarian atrophy.

LITERATURE CITED

1. DIGREGORIO, D., P. B. DUNAWAY and G. E. COSGROVE. 1973. Effect of acute gamma irradiation on the reproduction of *Peromyscus leucopus*. In *Proceedings of the Third National Symposium on Radioecology*, D. J. Nelson, editor. In press.
2. UPTON, A. C. and G. E. COSGROVE. 1968. Radiation-induced leukemia. In *Experimental Leukemia*, M. Rich, editor. Appleton-Century-Crofts, pp. 131-158.

* Research sponsored by the United States Atomic Energy Commission under contract with the Union Carbide Corporation.

¹ Present address: Oak Ridge City Schools, Oak Ridge, Tennessee.

² Present address: U.S.A.E.C., Nevada Operations Office, Las Vegas, Nevada.

Address correspondence to: Dr. G. E. Cosgrove, Biology Division, Oak Ridge National Laboratory, Post Office Box Y, Oak Ridge, Tennessee 37830.

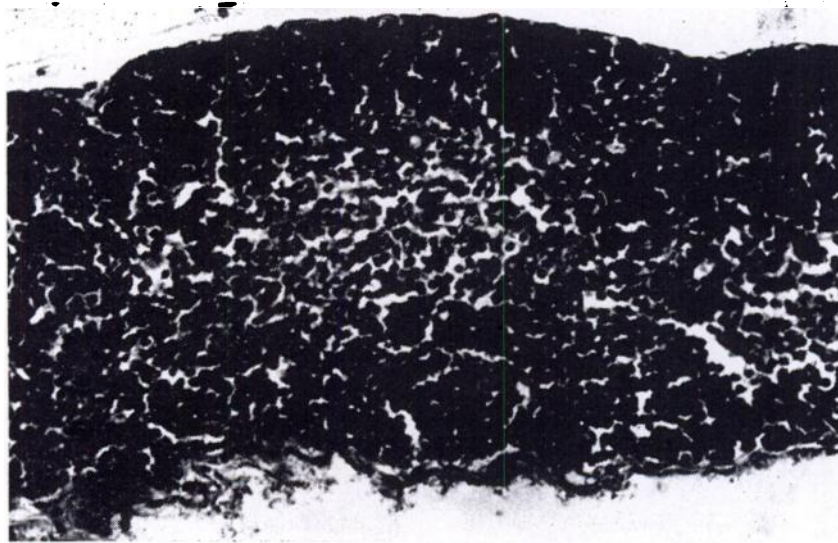


FIGURE 1. Thymic atrophy in a female white-footed mouse 7 months after 950 rad whole-body irradiation. The entire width of the thymus is shown. X 125.



FIGURE 2. Thymic lymphoma in one thymus of a female white-footed mouse. Only $\frac{1}{8}$ of the width of the thymus is shown. X 125.

Received for publication 24 July 1973