

## **INFECTION WITH THE NEMATODE *Streptocara incognita* IN THE CHILEAN FLAMINGO 1**

Authors: FOX, J. G., SNYDER, S. B., SCHMIDT, G. D., and  
CAMPBELL, L. H.

Source: Journal of Wildlife Diseases, 10(1) : 66-69

Published By: Wildlife Disease Association

URL: <https://doi.org/10.7589/0090-3558-10.1.66>

---

BioOne Complete ([complete.BioOne.org](https://complete.BioOne.org)) is a full-text database of 200 subscribed and open-access titles in the biological, ecological, and environmental sciences published by nonprofit societies, associations, museums, institutions, and presses.

Your use of this PDF, the BioOne Complete website, and all posted and associated content indicates your acceptance of BioOne's Terms of Use, available at [www.bioone.org/terms-of-use](https://www.bioone.org/terms-of-use).

Usage of BioOne Complete content is strictly limited to personal, educational, and non - commercial use. Commercial inquiries or rights and permissions requests should be directed to the individual publisher as copyright holder.

---

BioOne sees sustainable scholarly publishing as an inherently collaborative enterprise connecting authors, nonprofit publishers, academic institutions, research libraries, and research funders in the common goal of maximizing access to critical research.

## INFECTION WITH THE NEMATODE *Streptocara incognita* IN THE CHILEAN FLAMINGO<sup>1</sup>

J. G. FOX, S. B. SNYDER, G. D. SCHMIDT and L. H. CAMPBELL

**Abstract:** Naturally-occurring streptocarosis, caused by *Streptocara incognita* Gibson, 1968, was diagnosed in two Chilean flamingos, *Phoenicopterus chilensis*. Ulcerative lesions of the proventriculus and gizzard caused by the nematodes resulted in a severe debilitating condition and eventual death. *Streptocara incognita* has been reported previously only in anseriform birds.

### CASE HISTORY

Two adult Chilean flamingos, one male and one female, maintained in an outdoor aviary at the San Francisco Zoological Gardens died in October and December 1972. The female flamingo had been at the zoo for 2 years, the male bird for only 3 months. Their diet consisted of pheasant meal,<sup>2</sup> trout chow,<sup>3</sup> ground shrimp and grain. They were housed with a number of flamingos and several species of water birds, including ducks and geese. Signs of illness were not noted prior to death.

### GROSS AND HISTOPATHOLOGICAL FINDINGS

Each bird was thin, with marked atrophy of the thoracic pectoral muscles, and easily palpable carinal apex and keel bone. Subcutaneous adipose tissue was lacking. In the female bird, the upper intestinal tract was empty and dark bile-stained semi-solid material coated the mucosa of the ileum and colon. The mucosa in this part of the intestinal tract was bright red. Four ulcers 1-2 cm in diameter were at the junction of the gizzard and proventriculus (Figure 1).

Four to eight parasites, 8 to 12 mm long, were visible in each ulcer. Other organs appeared normal.

The male flamingo had similar ulcerative lesions on the proventriculus and gizzard. The proximal intestinal tract was empty and the terminal colon contained watery feces. The pericardial sac contained approximately 5 ml of clear straw-colored fluid and the left ventricular coronary groove contained fat of a gelatinous consistency. A reddish yellow liver had four or five 1-2 mm circumscribed nodules scattered through the parenchyma. Bacteria were not isolated in aerobic cultures of the heart blood and pericardial fluid.

Histologically, the parasitic ulcerations were similar in both cases. The ulcers extended through the mucosal epithelium and lamina propria of the gizzard and proventriculus. Necrotic cellular debris and polymorphonuclear cells had formed a pseudomembrane over the eroded portions (Figure 2). Cystic blood-filled spaces lined with fibrous tissue were present in the muscular layers of the gizzard. Perivascular lymphocytic infiltration was also marked in the muscular portions of the gizzard underlying the ulcers.

Supported in part by grants from National Institutes of Health, Animal Resources Branch RR282 and RR5004.

The authors acknowledge the assistance of the San Francisco Zoo staff for providing the birds for this study. The authors also thank Ms. Susan Maggetti for typing the manuscript.

<sup>1</sup> From the Division of Laboratory Animal Medicine, Stanford Medical Center, Stanford, California 94305 and (Schmidt).

<sup>2</sup> Trout Chow, Ralston-Purina Company, Checkerboard Square, St. Louis, Missouri.

<sup>3</sup> Ralston-Purina Game Bird Chow.

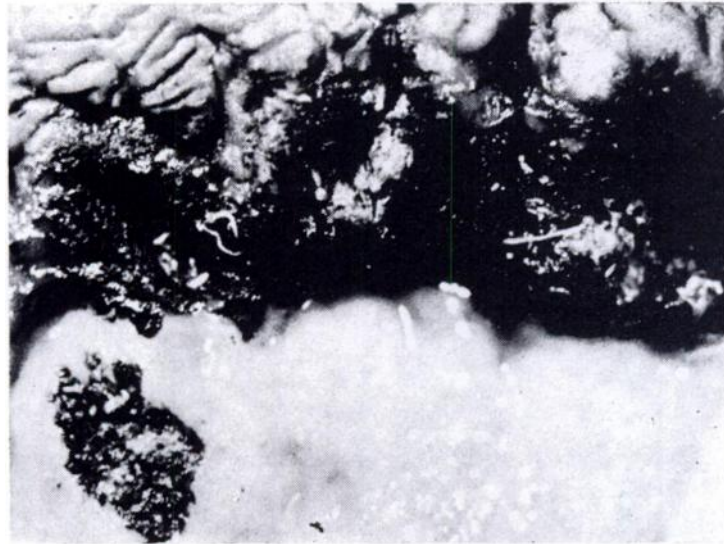


FIGURE 1. Ulcers measuring 1-2 cm at the junction of the gizzard and proventriculus. Nematodes are visible in the centers of the ulcers.

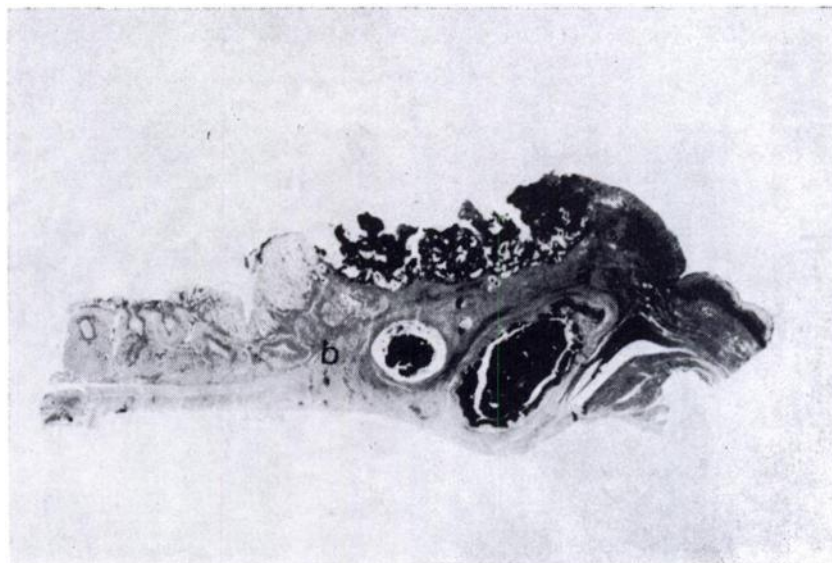


FIGURE 2. Ulcer and pseudomembrane formation at junction of gizzard (a) and proventriculus (b). Cystic blood-filled spaces are present in the muscular layers of the gizzard. H. and E. X1.

There were numerous cross sections of the nematodes in the pseudomembrane, in the mucosa surrounding the ulcer, and in the muscularis mucosae. Parasites in the muscular layers were surrounded by granulation tissue. Also

present in the necrotic areas of the gizzard and proventriculus were numerous thick-walled embryonated eggs measuring 37 to 39 $\mu$  by 20 to 21 $\mu$  (Figures 3 and 4).

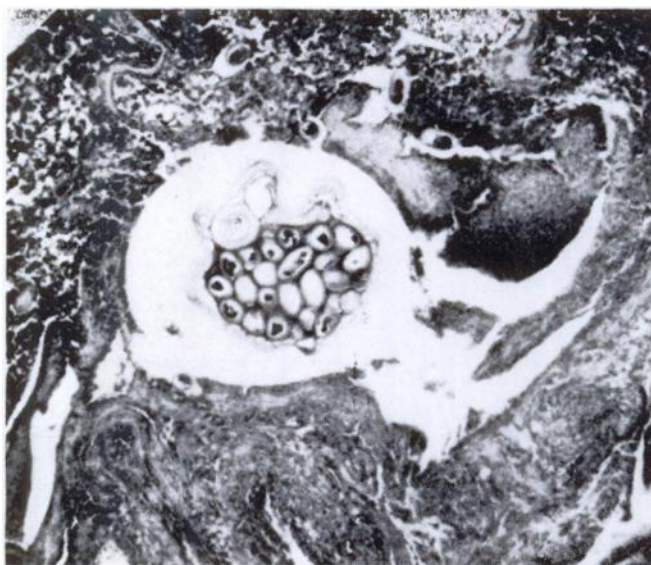


FIGURE 3. Cross section of *Streptocara incognita* in pseudomembrane of gizzard. H. and E. X100.

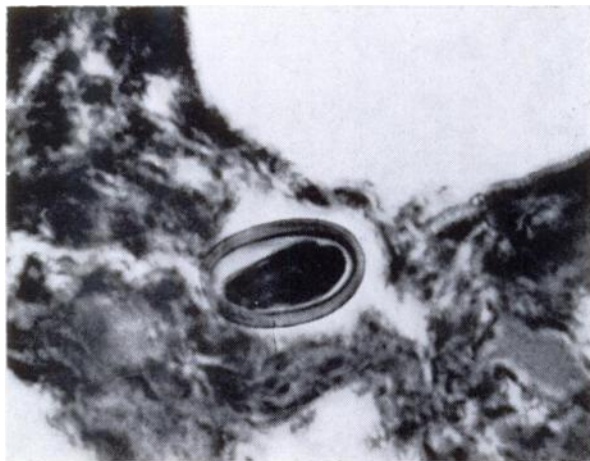


FIGURE 4. Thick-walled embryonated egg of *Streptocara incognita*. Egg measures approximately 37-39 $\mu$  X 20-21 $\mu$ . H. and E. X400.

The colon of the female flamingo had chronic inflammation of the mucosa. The nodules seen grossly in the liver of the male flamingo consisted of homogeneous necrotic material surrounded by a fibrous capsule. All other organs examined histologically appeared normal.

#### RESULTS AND DISCUSSION

Several nematodes in excellent condition were recovered from the lesions and preserved for identification. They agree in every detail with *Streptocara incognita* Gibson, 1968,<sup>2</sup> known previously only from anseriform birds.

Gibson reported *S. incognita* from ruddy duck, *Oxyura jamaicensis*, mallard, *Anas platyrhynchos*, and Barrow's goldeneye, *Bucephala islandica*, in British Columbia; in ruddy duck in Alberta; in mallard in Utah; and in the domestic Japanese goose, *Sygnopsis sygnoides*, in Yugoslavia. It has not been reported since its original description. Our specimens are deposited in the United States National Museum, Helm. Coll. No. 72636.

Gibson's description of lesions in the proventriculus and gizzard of ruddy ducks and goldeneyes parallel those in flamingos. Further, Karlovic et al.,<sup>3</sup> described similar lesions, often fatal, due

to this parasite in the esophagus of Japanese geese.

The life cycle of *S. incognita* is unknown, but probably it is similar to that of *Streptocara crassicauda* (Creplin, 1829) Railliet, Henry et Sisoff, 1912, a closely related species that also is a parasite of ducks. Garkavi<sup>1</sup> showed that larvae develop to the infective third stage in amphipod crustaceans, and that fish can serve as paratenic hosts. It appears that the source of infection for the flamingos may have been crustacea that had eaten eggs released by ducks kept in the same enclosure.

The emaciated condition of the flamingos, lack of food in the intestinal tract and the severe ulceration of the gizzard and proventriculus support the view that the infection with *Streptocara* was the cause of the debility and eventual death of both birds. The focal hepatic necrosis and chronic inflammation of the colon and their relationship to the *Streptocara* infection, remain obscure.

If infections with *Streptocara* become enzootic in an aviary, a search for intermediate crustacean hosts should be undertaken, and if identified, their eradication with CuSo<sub>4</sub> should be attempted. The efficiency of various anthelmintics on removal of the adult parasite from the intestinal tract of affected birds should also be tested.

#### LITERATURE CITED

1. GARKAVI, V. L. 1949. A study of the development of *Streptocara crassicauda* (Creplin, 1829), parasite of domestic and wild ducks. Dokl. Akad. Nauk SSSR 65: 421-424. (in Russian).
2. GIBSON, G. G. 1968. Species composition of the genus *Streptocara* Railliet et al., 1912 and the occurrence of these avian nematodes (Acuariidae) on the Canadian Pacific Coast. Canad. J. Zoo. 46: 629-645.
3. KARLOVIC, M., S. RICHTER and Z. ALERAJ. 1959. Streptocarosis in the Japanese goose (*Sygnopsis sygnoides* L.) Vet. Arkiv. 30: 7-12. (In Yugoslavian).

Received for publication 18 May 1973