

STOMATITIS IN A JUVENILE WHITE PELICAN DUE TO *Piagetiella peralis* (MALLOPHAGA: MENOPONIDAE)

Authors: WOBESER, G., JOHNSON, G. R., and ACOMPANADO, G.

Source: Journal of Wildlife Diseases, 10(2) : 135-138

Published By: Wildlife Disease Association

URL: <https://doi.org/10.7589/0090-3558-10.2.135>

BioOne Complete (complete.BioOne.org) is a full-text database of 200 subscribed and open-access titles in the biological, ecological, and environmental sciences published by nonprofit societies, associations, museums, institutions, and presses.

Your use of this PDF, the BioOne Complete website, and all posted and associated content indicates your acceptance of BioOne's Terms of Use, available at www.bioone.org/terms-of-use.

Usage of BioOne Complete content is strictly limited to personal, educational, and non - commercial use. Commercial inquiries or rights and permissions requests should be directed to the individual publisher as copyright holder.

BioOne sees sustainable scholarly publishing as an inherently collaborative enterprise connecting authors, nonprofit publishers, academic institutions, research libraries, and research funders in the common goal of maximizing access to critical research.

STOMATITIS IN A JUVENILE WHITE PELICAN DUE TO *Piagetiella peralis* (MALLOPHAGA: MENOPONIDAE)

G. WOBESER, G. R. JOHNSON and G. ACOMPANADO

Abstract: Hemorrhagic ulcerative stomatitis caused by the biting louse *Piagetiella peralis* was diagnosed in one live and three dead juvenile white pelicans (*Pelecanus erythrorhynchus*). The pathology of the condition is described, and the significance of infestation with this parasite is discussed.

INTRODUCTION

Biting lice of the genus *Piagetiella* are parasites of the throat pouches of pelicans and cormorants. Rothschild and Clay² state with regard to members of this genus, "their diet must consist of blood and serum, and possibly epidermal debris taken from the walls of the pouch"; however, no reference was found which described disease produced by these parasites. This note describes the lesions caused by *Piagetiella peralis* infestation in a young white pelican.

CASE HISTORY

On July 16, 1973, personnel of the Prairie Migratory Bird Research Centre, Canadian Wildlife Service, Saskatoon, Saskatchewan, reported mortality among juvenile white pelicans in a small island colony in Middle Quill Lake, Saskatchewan. The colony was visited the following day.

Twelve adult and seven juvenile pelicans left the island at our approach but one live juvenile pelican remained. This bird was weak and lethargic and offered little resistance when captured. Nine apparently normal juvenile Double-crested Cormorants (*Phalacrocorax auritus*) and one unidentified immature (dark plumage) gull were also present on the

island. The gull had flaccid paralysis of all limbs, and there was pasting of feces on the feathers about the cloaca and extensive fly maggot infestation on the ventral areas of the body. Forty-four juvenile pelicans, one adult pelican, two juvenile cormorants, and ten California (*Larus californicus*) and Ring-billed Gulls (*Larus delawarensis*) were found dead on the island. Of 41 of the juvenile pelicans and the adult, only skin and bones remained. These juveniles were all of a similar size and appeared to have died when approximately 1 to 2 weeks of age.

The other three juvenile pelicans had died more recently and were similar in size to the sick bird (weight 1430 g). These birds were autolyzed and only a cursory examination was performed. All of the gulls found dead on the island appeared to have been of flying age.

The juvenile pelican and gull died during transit to the laboratory. Botulism was subsequently diagnosed in the gull on the basis of a mouse protection test.

FINDINGS

The oral cavity of the juvenile pelican contained more than 500 large (3-6 mm) biting lice (Fig. 1, 2). These lice were primarily concentrated along the internal surface of the mandibles and on the

* Department of Veterinary Pathology (Wobeser and Johnson) and Department of Veterinary Microbiology (Acompanado), Western College of Veterinary Medicine, University of Saskatchewan, Saskatoon, Saskatchewan, Canada S7N 0W0.

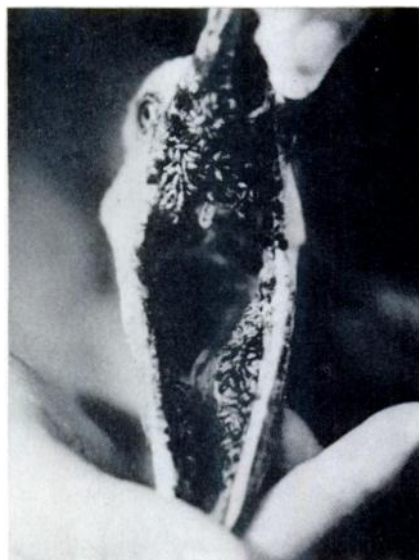

FIGURE 1. Massive infestation of *Piagetiella peralis* in the oral cavity of a live juvenile white pelican.

palate about the internal nares. Adult and juvenile lice were also attached at other sites in the pouch. The tissue surrounding the concentrations of lice was covered with a tenacious brown exudate which appeared to be a mixture of blood and louse excrement. Lice were firmly attached to the mucosa, and when detached, the underlying mucosa was ulcerated and hemorrhagic.

A very large number of immature lice were present over the body surface. The muscles were pale and the blood seemed thin and watery. Liver and spleen were pale and the former had rounded edges. The proventriculus was distended with foreign material (wood, dead grass and stones) and the intestine was empty. The only food item found in the alimentary tract was one dragon-fly nymph. Approximately ten nematodes (*Contracaecum* sp.) were present in the proventriculus.

No significant microorganisms were isolated on routine culture of tissues from this bird. The adult lice inhabiting




FIGURE 2. Lingual aspect of mandible. Numerous lice are attached to the mucosa, and former attachment sites are marked by small ulcers (arrows).

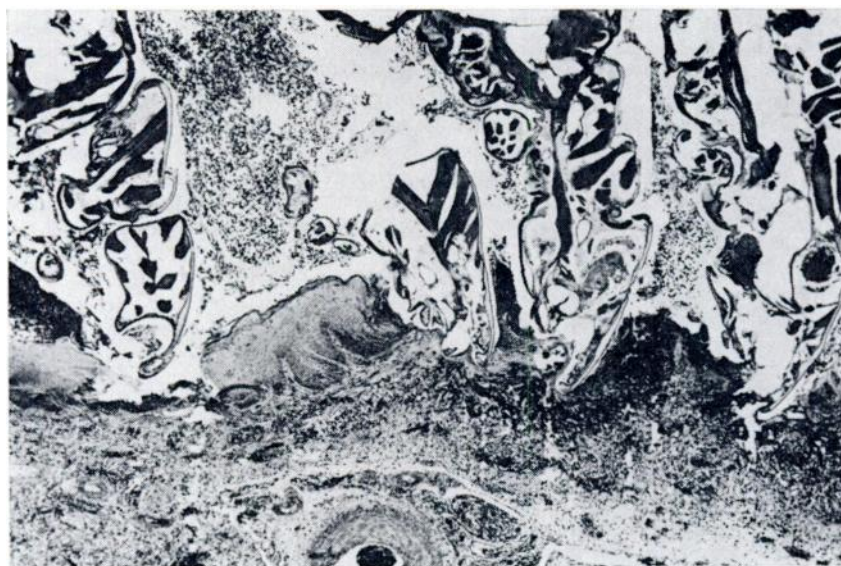

FIGURE 3. Oral mucosa: Epithelial ulceration at site of louse attachment, with submucosal hemorrhage and heterophil infiltration. Bodies of lice are surrounded by hemorrhagic debris. Hematoxylin-eosin. x 45.

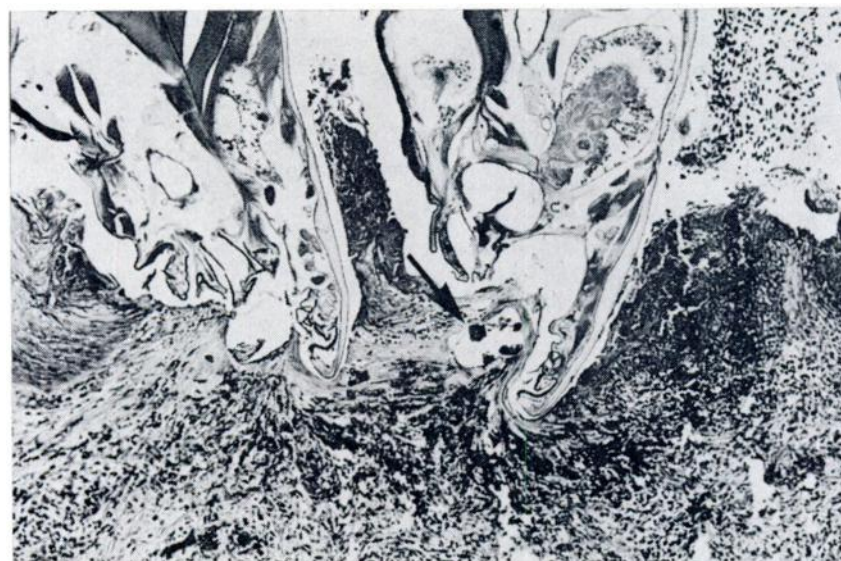

FIGURE 4. Oral mucosa: Part of Fig. 3 showing mandible of louse deeply imbedded in submucosa (arrow), and submucosal hemorrhage and cellular infiltration. Hematoxylin-eosin. x 110.

the pouch and the juvenile lice on the body surface were identified as *P. peralis* by the use of the key to the genus *Piagetiella* prepared by Price.³

Histologically, the oral mucosa was covered by a layer of blood and cellular debris. The mucosa contained numerous ulcers in which lice were firmly attached to the submucosa (Figs. 3, 4). There was marked submucosal hemorrhage in the areas of ulceration and extensive infiltration of the submucosa by heterophils, with occasional lymphocytes and histiocytes also present. Large bacterial colonies were present in the superficial debris and in the devitalized mucosa and submucosa at the margins of the ulcers.

Liver, spleen and kidney contained extensive hematopoietic tissue. A few small foci of inflammatory cells were present in the congested lungs.

The three dead large juvenile pelicans had ulcerations of the oral mucosa, with similar brown material in the pouch. Small numbers of dead lice were attached along the mandibles and on the palate of these birds.

DISCUSSION

Piagetiella peralis has been reported to occur on white pelicans from various

areas of North America,³ but this appears to be the first report of lesions produced by this parasite. "Normal" populations of biting lice apparently have little effect on their avian hosts, and populations of lice may be controlled by preening^{1,2}; however, heavy populations of lice may exert a serious effect on sick, captive or young birds.² The close association of numbers of susceptible hosts in a colonial nesting area, and the fact that the adults of *P. peralis* are located within the pouch where they are protected from preening might favour the development of large populations of this louse on young pelicans.

This parasite can produce a severe hemorrhagic stomatitis as evidenced in this case. This lesion might cause significant blood loss, and would provide a potential portal of entry for other pathogens. The severity of the oral lesions in the live bird, and the presence of similar lesions in the three dead juveniles suggests that *P. peralis* infestation may be a serious disease of young pelicans.

Further study is required to determine "normal" population levels of this louse, and the significance of these populations for juvenile pelicans.

LITERATURE CITED

1. ASH, J. S. 1960. A study of the Mallophaga of birds with particular reference to their ecology. *Ibis*: 102: 93-110.
2. ROTHSCHILD, M. and T. CLAY. 1952. *Fleas, Flukes and Cuckoos, a study of bird parasites*. Collins, London. 304 pp.
3. PRICE, R. D. 1970. The *Piagetiella* (MALLOPHAGA: MENOPONIDAE) of the Pelicaniformes. *Can. Ent.* 102: 389-404.

Received for publication 19 September 1973