

INTERNAL PARASITES OF COYOTES IN SOUTHERN TEXAS *

Authors: THORNTON, JACK E., and BELL, R. R.

Source: Journal of Wildlife Diseases, 10(3) : 232-236

Published By: Wildlife Disease Association

URL: <https://doi.org/10.7589/0090-3558-10.3.232>

BioOne Complete (complete.BioOne.org) is a full-text database of 200 subscribed and open-access titles in the biological, ecological, and environmental sciences published by nonprofit societies, associations, museums, institutions, and presses.

Your use of this PDF, the BioOne Complete website, and all posted and associated content indicates your acceptance of BioOne's Terms of Use, available at www.bioone.org/terms-of-use.

Usage of BioOne Complete content is strictly limited to personal, educational, and non - commercial use. Commercial inquiries or rights and permissions requests should be directed to the individual publisher as copyright holder.

BioOne sees sustainable scholarly publishing as an inherently collaborative enterprise connecting authors, nonprofit publishers, academic institutions, research libraries, and research funders in the common goal of maximizing access to critical research.

INTERNAL PARASITES OF COYOTES IN SOUTHERN TEXAS*

JACK E. THORNTON and R. R. BELL, Department of Veterinary Parasitology, and
M. J. REARDON, Department of Veterinary Pathology,
Texas A&M University, College Station, Texas 77843, U.S.A.

Abstract: Thirteen coyotes (*Canis latrans*) collected from Nueces County, Texas, harbored the following helminths: *Filaroides osleri*, *Dirofilaria immitis*, *Physalaptera* sp., *Alaria americana*, *Ancylostoma caninum* and *Taenia* sp. Aortic aneurysms were present in nine of ten adult coyotes (90%) while *Spirocerca lupi* was found on or in the wall of the thoracic esophagus of only three adult coyotes (30%). Oocysts of *Isospora rivolta* were found in the feces from one of two coyotes examined.

INTRODUCTION

The coyote, *Canis latrans*, is a predator of ecologic value to wildlife populations and can be an important factor concerning the management of domestic livestock. As man's understanding of the coyote's ecologic role is maturing, so is his aesthetic appreciation of this sometimes unjustly maligned predator.

Coyotes may also be an important reservoir for certain diseases and parasites transmissible to domestic dogs. Knowlton⁷ estimates that parts of southern Texas may average four to six coyotes/mi² (ca two/km²) in the fall, a figure of relatively high density. Holmes and Podesta have recently reviewed the recorded helminths reported from coyotes from several other regions of North America.⁸

MATERIALS AND METHODS

Thirteen coyotes were collected from Nueces County, Texas, four in April, four in June and five in August. All of the coyotes were mature adults except three collected in August which were approximately 4 months old.

Blood was collected just before or immediately after death from 10 of the coyotes. Blood smears from the 10

coyotes and lung impression smears taken from all 13 coyotes were stained with Giemsa stain and examined for blood parasites.

A necropsy was performed on each of the coyotes and internal organs were examined for parasites. Selected tissues were collected, preserved in buffered 10% formalin and processed for paraffin embedding. Tissue sections were cut at 6 microns thickness and stained with hematoxylin and eosin.

The contents and mucosal washings from each stomach and each intestinal tract were collected and washed by sedimentation. The sediment was examined under a stereoscope at 7x magnification. Nematodes were mounted and cleared in lactophenol and trematodes were stained with acetic acid alum carmine. Cestodes were identified to genus using a stereoscope at 15-30x magnification. A simple salt flotation technique was used on feces from two of the coyotes.

RESULTS AND DISCUSSION

Nodules 2-6 mm in diameter were present in the submucosal tissue at the tracheal bifurcation, associated with *Filaroides osleri*, in four coyotes, two of which were juveniles (Fig. 1). Erick-

* Joint contribution from the Department of Veterinary Parasitology, Texas Agricultural Experiment Station, Texas A&M University and the Texas Pittman-Robertson Project W-93-R.

son⁴ found what he thought to be *F. osleri* in 5.6% of 65 Minnesota coyotes, although he stated that worms recovered from tracheal cysts were so fragmentary that positive identification was impossible.

Dirofilaria immitis was recovered from the right ventricle and pulmonary artery of three coyotes. Numerous microfilariae were observed on blood and lung impression smears from each of these animals.

Physaloptera sp. was found in three coyotes, one to six per animal. Gier

and Ameal⁵ found that laboratory infections of coyote or dog pups with 50 or more *P. rara* regularly caused anemia and poor growth. *Physaloptera* feed largely on blood.

Although *Alaria americana* was found in the small intestine of all 13 coyotes, there were no gross lesions observed associated with its presence. In dogs the parasite is not regarded as a significant pathogen, though a catarrhal duodenitis has been observed in certain cases.¹² Allen and Mills' study in Saskatchewan revealed no clinical signs and only mini-

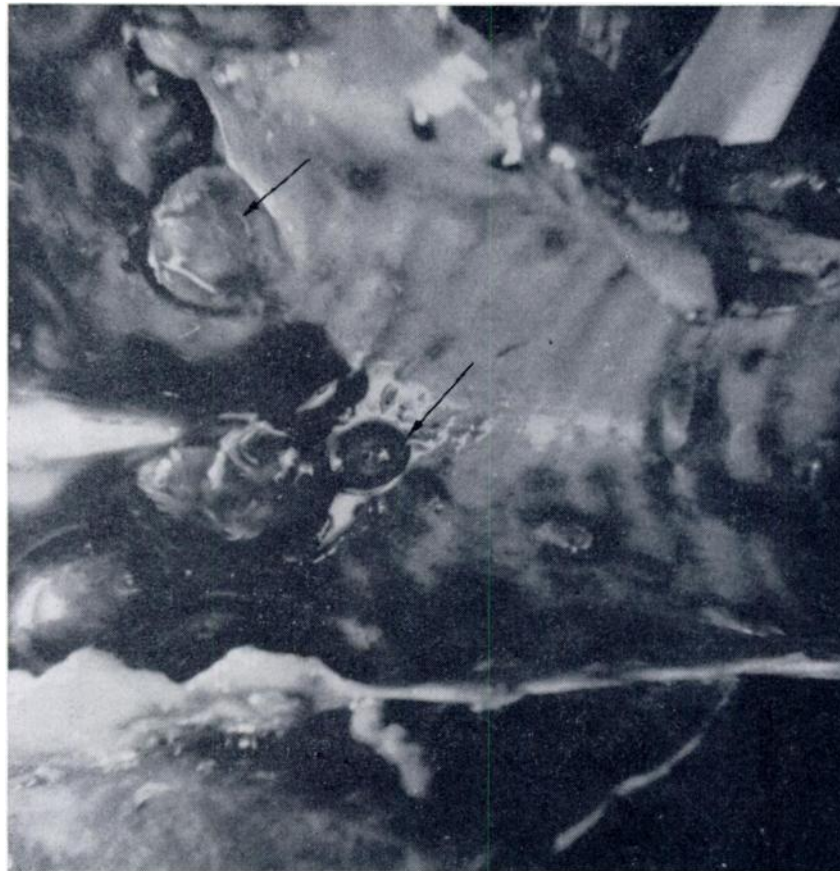

FIGURE 1. Nodules containing *Filaroides osleri* (arrows) at the tracheal bifurcation of a juvenile coyote.

mal gross and histopathological lesions in dogs harboring *Alaria arisaemoides*, further substantiating the low pathogenicity of this genus.

Canine hookworms, *Ancylostoma caninum*, were recovered from all 13 coyotes, ranging from less than 10 to over 150 per coyote. *Taenia* sp. was found in eight animals, 3-64 per coyote. In a report on intestinal parasites in coyotes from Zapata County, Texas, Smith¹⁰ reported finding *A. caninum*, *Taenia* sp., *Physaloptera* sp., *Mesocystoides* sp., *Toxascaris leonina* and *Oncicola canis*.

Adults of *Spirocera lupi* located on or in the wall of the thoracic esophagus were found in three coyotes, although multiple aneurysms were evident throughout the arch of the aorta in nine of ten adult animals. Scarring of the thoracic aorta is a pathognomonic lesion of *Spirocera* infection, and aneurysms of variable size are often present.² Adult *S. lupi* and aortic lesions were absent in the three juvenile coyotes. In one coyote a nodule 15mm in diameter was observed in the wall of the esophagus with an opening to the serosal surface (Fig. 2). The nodule contained two adult worms

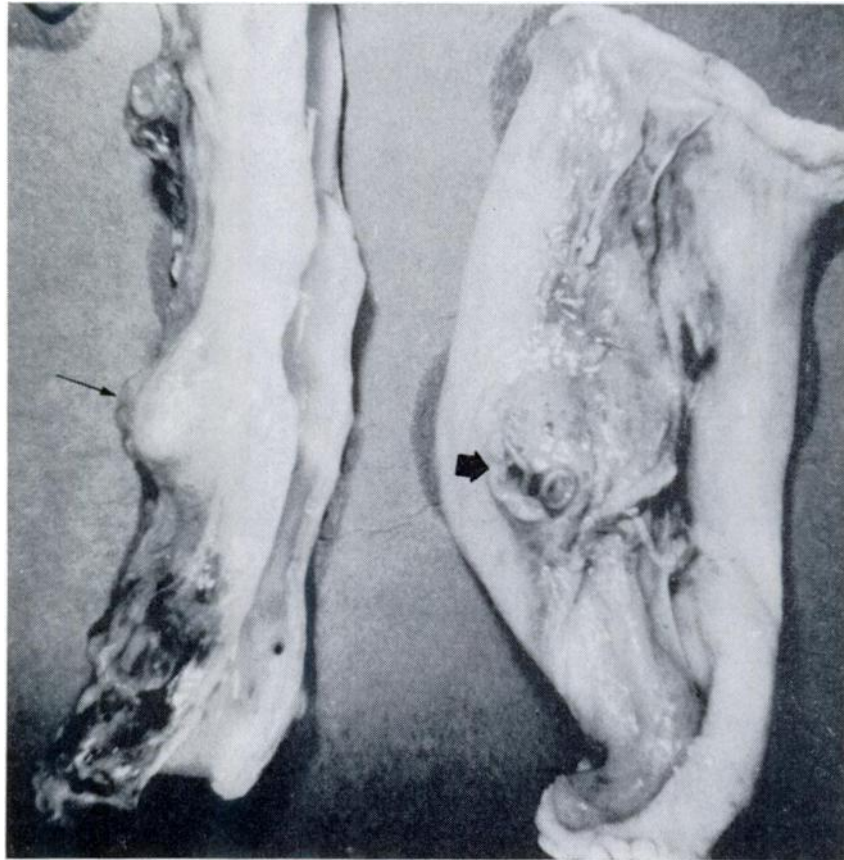


FIGURE 2. Coyote aortic arch (left) with aneurysm (long arrow). Esophageal granuloma (right) containing adult *S. lupi* (short arrow). There was no communication with the esophageal lumen.

and there was no communication between it and the esophageal lumen. In a second coyote, a pedunculated nodule 25mm in diameter was found communicating with the esophageal lumen via a pedicel 7-8mm long through which the posterior aspects of three worms were protruding into the lumen. Histological examination revealed both nodules to be granulomas. One adult *S. lupi* was found on the esophageal serosa of a third coyote, without gross lesions. In none of the coyotes with aortic lesions without esophageal lesions was there any evidence to suggest regression of an earlier esophageal granuloma.

Gross lesions of coyote aortae involved the proximal 7 - 12 cm and as seen from the serosal aspect, these were characterized by multiple, irregular, bubble-like lesions 1 - 10mm wide (Fig. 2) projecting from the normally smooth surface. Correspondingly, the intimal surface of affected aortae consisted of irregular, deep pits and depressions up to 8mm in width.

Although the coyote is generally known to be a host for *S. lupi*, there is a paucity of information concerning this host-parasite relationship. Smith¹¹ reported finding aortic aneurysms in 67 of 107 coyotes (62%) from different regions in Texas, whereas only 6 of 107 coyotes (6%) showed evidence of spirurid lesions in the wall of the esophagus. It was not reported how many of the esophageal lesions contained viable parasites and if the adult worms had established communication with the esophageal lumen. Ross and Suzuki⁸ employed selective lateral angiocardiograms to identify lesions in the thoracic portion of the aorta caused by *S. lupi* in 4 of 11 coyotes captured in eastern Texas.

Although the coyote appears to be a common host for *S. lupi* throughout Texas, the failure of worms to reach the esophagus in most of the infected animals suggests that the coyote is not as favorable a host for *Spirocera* as is the dog. There is apparently a high prevalence of spirocercosis in coyotes throughout Texas. According to Bailey,² even though adult worms are found in the wall of the esophagus in only about 9% of

infected coyotes, they still could be an important reservoir host if the worms in the esophagus establish communication with the lumen as they do in dogs.

Veterinary practitioners within a 24km radius of the site at which coyotes were acquired in this study were queried as to the prevalence of *S. lupi* in dogs from that area. Of six veterinarians questioned none had seen the parasite in dogs, although each stated that he did few necropsies and was not likely to be concerned with those organs characteristically showing lesions.

There have been no reports of esophageal sarcoma in coyotes. The high frequency of the sarcoma in *Spirocera*-infected hounds suggests that it develops only in dogs with a genetic predisposition to the neoplasm, regardless of the nature of the oncogenic stimulus. However, occurrence of the sarcoma in other breeds shows that this is not a strict breed predisposition.²

Pinworms (Oxyuridae) live in the colon of various animals, including rodents and rabbits, and have been reported from coyotes in Utah⁸ and California.⁹ Small oxyurids were found in the stomachs of two coyotes in this study, apparently from the digestion of small mammals, as strongly suggested by the location (stomach) and by hair and bone material concurrently found in the stomach contents. This phenomenon might account for the finding of oxyurids in the large intestine of coyotes, although some may argue that such worms would by then be digested. Gier and Ameel⁵ found no pinworms in coyotes from Kansas, though 350 animals were examined especially for them. In addition to these findings, it should be noted that in general surveys conducted by Erickson in Minnesota⁴ and Holmes and Podesta in Alberta,⁹ no pinworms were reported from coyotes.

Oocysts of *Isospora rivolta* were found by fecal examination on one of two adult coyotes using a simple salt flotation technique. No blood protozoa were observed on either the blood or lung impression smears.

Acknowledgements

The authors acknowledge Mr. Rod Marburger and members of the Texas Parks and Wildlife Department for their valuable assistance.

LITERATURE CITED

1. ALLEN, J. R. and J. H. L. MILLS. 1971. *Alaria arisaemoides* in Saskatchewan Dogs. Can. Vet. J. 12: 24-28.
2. BAILY, W. S. 1972. *Spirocerca lupi*: a continuing inquiry. J. Parasit. 58: 3-22.
3. BUTLER, J. M. and A. W. GRUNDMANN. 1954. The intestinal helminths of the coyote *Canis latrans* Say in Utah. J. Parasit. 40: 1-4.
4. ERICKSON, A. B. 1944. Helminths of Minnesota canidae in relation to food habits and a host list and key to the species reported from North America. Amer. Midland Nat. 32: 358-372.
5. GIER, H. T. and D. J. AMEEL. 1959. Parasites and diseases of Kansas coyotes. Kans. Ag. Exp. Sta. Tech. Bull. No. 91: 3-34.
6. HOLMES, J. C. and R. PODESTA. 1968. The helminths of wolves and coyotes from the forested regions of Alberta. Can. J. Zool. 46: 1193-1204.
7. KNOWLTON, F. F. 1972. Preliminary interpretations of coyote population mechanics with some management implications. J. Wildl. Mgt. 36: 369-382.
8. ROSS, J. N. and M. SUZUKI. 1973. Cardiovascular observations in coyotes. J. Amer. Vet. Med. Assoc. 163: 582-585.
9. SKINKER, M. S. 1931. Three new parasitic nematode worms. Proc. U.S. Nat. Mus 79: 1-9.
10. SMITH, J. P. 1967. A report on the incidence of intestinal parasites in coyotes from Zapata County, Texas. Southwestern Vet. 20: 209-210.
11. SMITH, J. P. 1971. Parasitic aortic aneurysms of coyotes. In *Pathology of Parasitic Diseases*. Purdue Univ. Press, Lafayette, Ind.
12. SOULSBY, E. J. L. 1965. *Textbook of Veterinary Clinical Parasitology. Vol. I. Helminths*. F. A. Davis Co., Philadelphia, Pa.

Received for publication 24 December 1973