

EPIZOOTIC OF CANINE DISTEMPER VIRUS INFECTION AMONG URBAN RACCOONS AND GRAY FOXES

Authors: HOFF, GERALD L., BIGLER, WILLIAM J., PROCTOR,
STANLEY J., and STALLINGS, LEWIS P.

Source: Journal of Wildlife Diseases, 10(4) : 423-428

Published By: Wildlife Disease Association

URL: <https://doi.org/10.7589/0090-3558-10.4.423>

BioOne Complete (complete.BioOne.org) is a full-text database of 200 subscribed and open-access titles in the biological, ecological, and environmental sciences published by nonprofit societies, associations, museums, institutions, and presses.

Your use of this PDF, the BioOne Complete website, and all posted and associated content indicates your acceptance of BioOne's Terms of Use, available at www.bioone.org/terms-of-use.

Usage of BioOne Complete content is strictly limited to personal, educational, and non - commercial use. Commercial inquiries or rights and permissions requests should be directed to the individual publisher as copyright holder.

BioOne sees sustainable scholarly publishing as an inherently collaborative enterprise connecting authors, nonprofit publishers, academic institutions, research libraries, and research funders in the common goal of maximizing access to critical research.

EPIZOOTIC OF CANINE DISTEMPER VIRUS INFECTION AMONG URBAN RACCOONS AND GRAY FOXES

GERALD L. HOFF and WILLIAM J. BIGLER, Veterinary Public Health Section,
Florida Division of Health, P.O. Box 210, Jacksonville, Florida 32201, USA.

STANLEY J. PROCTOR, Histopathology Unit, Veterinary Services Diagnostic Laboratory,
United States Department of Agriculture, P.O. Box 70, Ames, Iowa 50010, USA.

LEWIS P. STALLINGS, Director, Sarasota County Animal Control,
P.O. Box 8, Sarasota, Florida 33577, USA.

Abstract: An epizootic of canine distemper (CD) virus infection is described among raccoons and gray foxes in urban Sarasota County, Florida. The epizootic persisted for 2 years with a total of 114 raccoons and 8 gray foxes being handled by Sarasota County Animal Control. Virus was isolated from clinically ill raccoons on two separate occasions, 7 months apart. CD antibodies were detected in 54.5% of a sample comprising both clinically ill and apparently normal raccoons. The incidence of CD in dogs in the county did not increase during the 2 year period.

INTRODUCTION

The rapid reduction of wildlife habitat for land development in Florida has resulted in the intimate association of man and certain free-ranging wild animal species, including the raccoon (*Procyon lotor*) and gray fox (*Urocyon cinereo-argenteus*). This association tends to accentuate the importance of epizootic diseases observed in these wildlife species, such as outbreaks of rabies in urban raccoon populations.¹ When large numbers of sick or dead animals are encountered in urban areas, the burden for regulating the situation and for pacification of the citizenry usually lies with the local animal control agencies. These outbreaks may place undue strain upon the capabilities of such organizations. This situation occurred when an epizootic of canine distemper (CD) was diagnosed among raccoons and gray foxes in urban areas of Sarasota County, Florida, during 1972 and 1973.

Information concerning the epizootiology of CD virus among wildlife populations is limited, with available data being largely restricted to clinical signs of disease and to pathologic changes.² Virus

transmission presumably is via aerosol or direct contact. This report presents: (1) The epizootologic curve, based on clinical signs, of a CD outbreak in urban raccoons and foxes, (2) the confirmation of CD virus as the causative agent, as established by microscopic examination, animal inoculation and serology, (3) results of tests for other possible microbial and chemical etiologies, and (4) the status of CD in dogs during the epizootic.

MATERIALS AND METHODS

Sarasota County (1,612 km²) is located in southwestern peninsular Florida, bordered by Manatee, DeSoto, and Charlotte Counties and by the Gulf of Mexico. Approximately 81% of the 120,400 residents of the county live along the gulf coast on a 104 km² strip of the land stretching south from the Sarasota-Manatee County line to the community of South Venice. The epizootic among the raccoons and gray foxes was observed within this highly urbanized area. Clinically ill animals were captured by personnel of the Sarasota County Animal Control Unit in response to calls from alarmed citizens.

Several methods were employed for diagnosis. Since an outbreak of rabies had occurred among raccoons in the county in 1968,⁵ brains from 25 raccoons and three foxes captured early in the epizootic were submitted to the Florida Division of Health (FDH) Bureau of Laboratories in Tampa and Jacksonville for rabies examination by both the Negri body and fluorescent antibody (FA) techniques. Periodically, animals from later stages of the epizootic were also examined for rabies. Brains from some raccoons were also inoculated intracerebrally into suckling and weanling Swiss mice and the mice observed for morbidity and mortality over a 21 day period.

Portions of brains and viscera from five sick raccoons were placed on dry ice and in 10% buffered formalin and submitted to the Florida Division of Animal Industry (FDAI), Kissimmee Diagnostic laboratory, for microscopic examination and for bacterial culture. Blood samples from six other clinically ill animals were placed in thioglycollate broth vacuum bottles[□] and incubated for 3 weeks at 37 C at the FDH Bacteriology Section in Jacksonville. After initial identification, selected isolants from the blood were forwarded to the Clinical Bacteriology Unit of the Center for Disease Control (CDC), Atlanta, Georgia, for further identification.

Brain tissue from two clinically ill raccoons captured in September, 1972, was injected intramuscularly and intraperitoneally into a clinically healthy raccoon captured in Sarasota County. This procedure was repeated using brain and spleen samples from another clinically ill raccoon captured in April, 1973, and a raccoon from Duval County in northeast Florida. Raccoons were observed for 1 month post-inoculation.

Field material and specimens from the experimental raccoons were forwarded in 10% buffered formalin and on dry ice to the Histopathology Unit, Veterinary Services Laboratory, U.S. Department of Agriculture (VSL USDA), Ames, Iowa.

The formalized tissues were examined microscopically for lesions. The frozen tissues were inoculated into two beagles and three ferrets. One dog was injected subcutaneously with an inoculum of tissues from a field case while the other dog was given tissues from an experimental raccoon. A similar procedure was used with the ferrets, two were inoculated with field material and one with experimental raccoon samples. The dogs were observed for 2 months and the ferrets for 3 weeks. Pre-inoculation and post-inoculation sera were obtained from these animals. At termination of the observation periods, the animals were euthanized and their tissues examined microscopically.

Brains from 23 raccoons were submitted to (1) the Mycology Section of CDC for histologic examination and isolation attempts, and (2) School of Veterinary Medicine, University of Georgia for attempted isolation of *Listeria monocytogenes*. In addition, brain and visceral tissue from clinically ill and experimental animals were submitted to the Department of Veterinary Science, University of Wisconsin—Madison, for virus isolation attempts in primary raccoon kidney, primary ferret kidney and BHK-21 cell tissue culture.

Serum samples collected from clinically ill and apparently healthy raccoons were also tested for antibodies to various microbial agents. Serum neutralization tests for rabies and CD antibodies were conducted by the Rabies Control Unit, CDC and the Small Animal Viral Products Unit VSL USDA respectively. Hemagglutination-inhibiting antibody tests for eastern encephalitis, Venezuelan encephalitis and St. Louis encephalitis were done by the FDH Virology Section in Jacksonville. Agglutination tests for canine brucellosis, tularemia and leptospirosis were conducted by the FDH Veterinary Public Health Section, while indirect hemagglutination and methylene blue dye tests for toxoplasmosis were done by the Parasitic Diseases Branch, CDC.

[□] Becton-Dickinson, Rutherford, N.J.

The tissues for selected clinically ill raccoons were also tested for arsenic by FDIA, for lead and thallium by VSL USDA and for pesticides by FDH Chemistry Section.

RESULTS

The epizootic among raccoons and gray foxes (based on clinical signs) was first observed in January 1972 and continued through November 1973, with the peak number of cases (22 raccoons and a fox) occurring in September 1972 (Figure 1). During the course of the outbreak, Sarasota County Animal Control personnel handled 114 raccoons and 8 foxes with similar signs of illness: dyspnea, ataxia, clonic convulsions, spasms of the hind legs, ascending paralysis, progressive blindness, loss of appetite, emaciation, diarrhea and coma. Records were not maintained by various law enforcement agencies within the epizootic area on the number of animals

they handled, but it is believed that at least an equal number of clinically ill animals were encountered. No age or sex differences among the afflicted animals were observed and several ill female raccoons were known to have given birth. These sick animals were non-aggressive and the vast majority were found along Phillippi Creek, the main drainage basin of the county, and Little Sarasota and Blackburn Bays which receive waters from Phillippi Creek.

While most animals were killed and buried, 6 foxes and 37 raccoons were examined for rabies virus in their brains and were negative by direct microscopic, FA and mouse inoculation techniques. Large, stippled eosinophilic intranuclear inclusion bodies were observed in the brain cells of these animals. Serum samples from four clinically ill and from 18 apparently healthy raccoons captured in October 1972, were negative for rabies neutralizing antibodies. During the period 1972-1973, five cases of rabies were reported in the epizootic area, in two bats

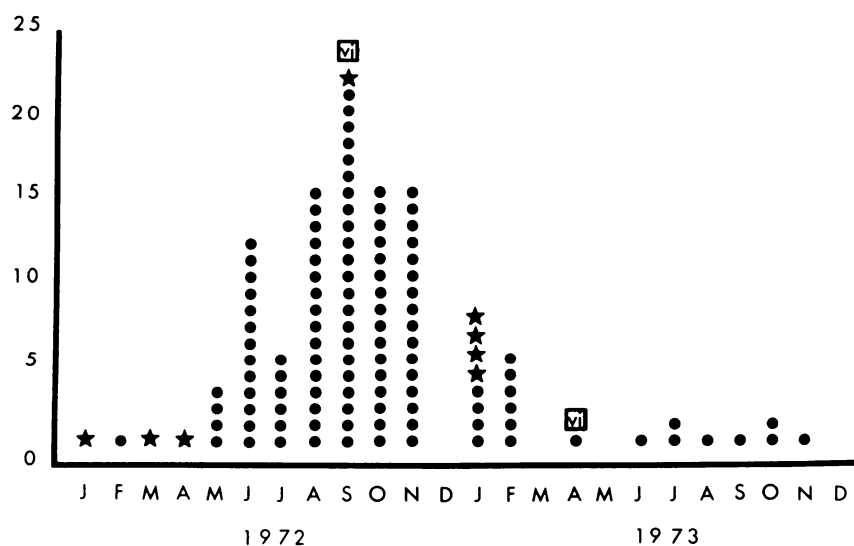


FIGURE 1. Epizootiologic curve of canine distemper outbreak among raccoons (dots) and gray foxes (stars) in Sarasota County, Florida. Curve is based on clinical signs. Virus isolations indicated by VI.

(*Lasiurus floridanus*), two raccoons and one fox. As opposed to the non-rabid animals, the rabid raccoons and fox had aggressive behavior.

Bacterial examination of the brains and viscera of five raccoons and the blood of six other animals yielded numerous isolations of bacteria. These isolants were of the genera *Escherichia*, *Proteus*, *Clostridium*, *Staphylococcus*, *Streptococcus*, *Pseudomonas* and *Bacillus*, however none were considered to be a possible etiologic agent of the outbreak. Neither *Listeria monocytogenes* nor fungi were isolated from the brains of 23 raccoons.

The two attempts at reproducing the disease in raccoons were successful, with incubation periods of 11 and 30 days. Signs of illness were identical to those observed in field cases, with the experimental animals surviving 5 and 9 days after onset of overt disease.

In the experimental raccoons as well as in field cases, gross lesions were lacking or confined to irregular areas of congestion in the lungs. Microscopic examination of tissues revealed focal areas of hemorrhage and edema in the lungs along with interstitial or bronchopneumonia. Large macrophages were observed in the lung alveoli of some raccoons. Eosinophilic cytoplasmic inclusion bodies were found in the epithelial cells of the bronchi and bile duct and in the transitional epithelium of the renal pelvis and urinary bladder. Germinal centers in the spleen were depleted of mature lymphocytes. Diffuse focal areas of demyelination and malacia were observed in sections of the cerebrum and midbrain. Large gitter cells were noted in some sections and multinucleated macrophages were seen in areas of malacia. Glial cells with eosinophilic intranuclear inclusion bodies were present around the foci of demyelination and malacia. Based on the microscopic findings, a diagnosis of CD virus infection was made.

Virus could not be recovered from the tissues of naturally or experimentally infected raccoons when inoculated into primary raccoon kidney, primary ferret

kidney or BHK-21 tissue culture systems. Clinical symptoms of CD infection were not observed in either of the inoculated beagle dogs, however, both animals developed CD specific neutralizing antibody titers of at least 1:20 and both had microscopic lesions of infection with CD virus.

Of the three CD free ferrets inoculated, one died before a post-inoculation serum was obtained. Clinical signs and microscopic lesions of CD were noted in this ferret. One of the remaining ferrets died after showing similar clinical signs and microscopic lesions of CD were observed. Serologic results in this ferret also indicated the presence of CD virus in the raccoon tissue inoculum. Although clinical or microscopic evidence of CD was not observed in the third ferret, pre-inoculation (less than 1:5) and post-inoculation (1:20) CD neutralizing antibody titers indicated that the virus was present in the inoculum.

Of 22 naturally infected and apparently healthy raccoons tested for CD neutralizing antibodies, 12 (54%) had significant (greater than 1:5) titers. Serologic reactions against other microbial agents were few, there being one reactor to eastern encephalitis, one to tularemia and one to leptospirosis.

The tissues of sick raccoons were negative for levels of arsenic, lead and thallium, and pesticide residue levels in omental fat were low.

DISCUSSION

Clinical signs of CD infection in the raccoons and foxes resembled the signs of rabies in these species during the 1968 rabies epizootic. A number of raccoons captured early in a subsequent outbreak in 1969 were not rabid but instead were suspected of being infected with CD virus. Therefore, when the CD epizootic began to develop in 1972. Animal Control personnel had to consider the possibility of another rabies outbreak. The financial expense to the county to keep abreast of the situation was estimated at approximately 700 man hours with a cost of \$17.50 per animal captured.

TABLE 1. Ten year summary of reported cases of canine distemper infection in dogs from Florida.^[1]

Year	Florida	Sarasota County
1964	1884	0
1965	3631	65
1966	4579	86
1967	4162	1
1968	4153	80
1969	3800	69
1970	3234	61
1971	3453	45
1972	2916	43
1973	3144	40
Total	34,956	490

[1] Source: Florida Animal Morbidity Report, annual summaries 1964-1973. Published by Veterinary Public Health Section, Florida Division of Health, Jacksonville, Florida 32201.

From the epizootiologic curve, it would appear that CD virus was introduced initially into the fox population and subsequently into the raccoons, among which 93% of the cases were observed. The source of the virus introduction is unknown. Most of the raccoon cases occurred between June and November 1972, while most of the fox cases were observed between January and April 1972 and in January 1973. In Florida, the greatest incidence of CD activity among dogs is between July and December. During the course of the outbreak there was no reported increase in the number of CD cases in dogs from Sarasota County (Table 1).

Of the raccoons tested 54% had CD neutralizing antibodies as compared to 22% and 84% in raccoons from non-epizootic situations in New York and Maryland respectively.^{3,6} While other studies suggest that CD antibodies would subsequently protect the raccoon from challenge with virulent virus,⁴ in the present study, the disease was reproduced

in a raccoon from Sarasota County with a CD neutralizing antibody titer of 1:9. The amount of virus in the inoculum, however, may have overwhelmed the animal's immunological capabilities.

The overall effect of the epizootic on the fox and raccoon populations is unknown, since estimates of the relative densities of the two populations at the time of the outbreak are lacking. Population estimates following the 1968 rabies outbreak for raccoons in the geographical area of the CD epizootic ranged from 0 to 17 animals/km² [2]. Higher densities did exist prior to the CD outbreak. Also, the number of nuisance calls involving raccoons received by Animal Control dropped sharply during the epizootic and did not increase until the middle of 1973.

The epizootic was not self-limiting, but spread into the neighboring counties of Manatee, DeSoto and Charlotte. By the fall of 1973, the virus had spread into Glades and southern Highland Counties, which abut the eastern borders of

[2] McLean, R. G. 1973. Personal Communication. Center for Disease Control, Fort Collins, Colorado.

Charlotte and DeSoto Counties respectively. In Glades County, the disease appeared to be affecting raccoons primarily, while in Highlands County foxes seemed to be the main species afflicted. The affects of CD on the fox and raccoon populations in Highlands County is being monitored by the Archbold Biological Station in conjunction with the FDH and the USDA.

The CD epizootic reported here illustrates the point that while certain disease agents capable of producing morbidity and mortality among wildlife spe-

cies are generally taken for granted, under certain conditions they cannot be lightly dismissed. Because 1) CD in wild carnivores closely resembles rabies, 2) CD may have preceded the rabies epizootic in 1969 and 3) the CD epizootic occurred in a highly urbanized area, considerable manpower and money was utilized to monitor the situation. As man further extends his communities into prime wildlife habitat, diseases in urban wildlife will become increasingly more important.

Acknowledgments

The authors would like to thank the following individuals for their assistance in this investigation: Dr. R. S. Wilhelm, Sarasota County; Dr. J. B. Nichols, Dr. A. Lewis, Ms. E. Lassing, Ms. M. Shriber, Ms. W. Hull, FDH; Dr. T. Bunn, USDA; Dr. D. E. Cooperrider, FDAI; Drs. R. G. McLean, L. Ajello, R. R. Facklam, G. F. Slonka, CDC; Dr. T. M. Yuill, University of Wisconsin; and Dr. E. Shotts, University of Georgia.

LITERATURE CITED

1. BIGLER, W. J., R. G. McLEAN and H. A. TREVINO. 1973. Epizootiologic aspects of raccoon rabies in Florida. *Am. J. Epidem.* 98: 326-335.
2. BUDD, J. 1970. Distemper. In *Infectious Diseases of Wild Mammals*, ed. by J. W. Davis et al. Iowa State University Press, Ames, Iowa. pp. 36-49.
3. JAMISON, R. K., E. C. LAZAR, L. N. BINN and A. D. ALEXANDER. 1973. Survey for antibodies to canine viruses in selected wild animals. *J. Wildl. Dis.* 9: 2-3.
4. KILHAM, L., R. T. HABERMANN and C. M. HERMAN. 1956. Jaundice and bilirubinemia as manifestations of canine distemper in raccoons and ferrets. *Am. J. vet. Res.* 17: 144-148.
5. McLEAN, R. G. and K. D. KAPPUS. 1969. Rabies infection and serology in wildlife from the Tampa Bay area. *Bull. Wildl. Dis. Ass.* 5: 372.
6. PARKER, R. L., V. J. CABASSO, D. J. DEAN and E. J. CHEATUM. 1961. Serologic evidence of certain virus infections in wild animals. *J. Am. vet. med. Ass.* 138: 437-440.

Received for publication 27 May 1974