



## **Capillaria hepatica IN A GROUNDHOG (Marmota monax)**

Authors: REYNOLDS, WILLIAM A., and GAVUTIS, GEORGE

Source: Journal of Wildlife Diseases, 11(1) : 13

Published By: Wildlife Disease Association

URL: <https://doi.org/10.7589/0090-3558-11.1.13>

---

BioOne Complete ([complete.BioOne.org](https://complete.BioOne.org)) is a full-text database of 200 subscribed and open-access titles in the biological, ecological, and environmental sciences published by nonprofit societies, associations, museums, institutions, and presses.

Your use of this PDF, the BioOne Complete website, and all posted and associated content indicates your acceptance of BioOne's Terms of Use, available at [www.bioone.org/terms-of-use](https://www.bioone.org/terms-of-use).

Usage of BioOne Complete content is strictly limited to personal, educational, and non - commercial use. Commercial inquiries or rights and permissions requests should be directed to the individual publisher as copyright holder.

---

BioOne sees sustainable scholarly publishing as an inherently collaborative enterprise connecting authors, nonprofit publishers, academic institutions, research libraries, and research funders in the common goal of maximizing access to critical research.

## *Capillaria hepatica* IN A GROUNDHOG (*Marmota monax*)

WILLIAM A. REYNOLDS, Box 194, Three Bridges, New Jersey 08887

GEORGE GAVUTIS, Jr., Great Swamp National Wildlife Refuge, R.D. 1, Box 148,  
Basking Ridge, New Jersey 07920

This note describes a natural *C. hepatica* infection in a groundhog shot at the Great Swamp National Wildlife Refuge. The only grossly observable lesions were in the liver. Thirteen, yellowish-white, slightly raised lesions approximately 2 to 4 mm in diameter and extending into the liver parenchyma approximately 4 mm,

were scattered over all lobes of the liver. Upon histological sectioning, the liver lesions revealed *C. hepatica* adults and their characteristic eggs trapped in the liver parenchyma (Fig. 1). Each adult was surrounded by macrophages, causing considerable damage to the hepatica parenchyma.

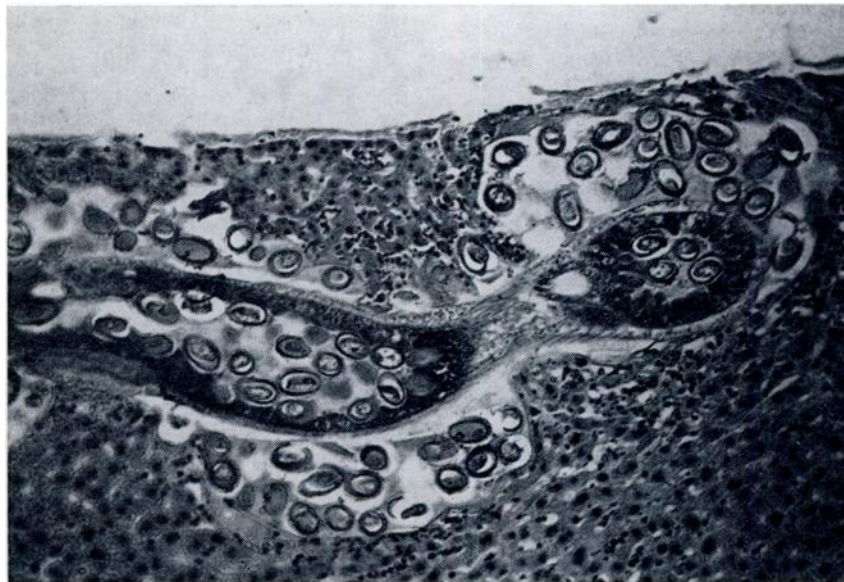


FIGURE 1. Section through a liver lesion containing *C. hepatica*. Notice the amount of tissue damage to the liver parenchyma surrounding the parasite. H & E stain; X 120.

Received for publication 27 August 1973