

## **INCLUSION BODY DISEASE (HERPESVIRUS INFECTION) OF FALCONS (IBDF)**

Authors: GRAHAM, DAVID L., MARE, C. JOHN, WARD, F. PRESCOTT, and PECKHAM, MALCOLM C.

Source: Journal of Wildlife Diseases, 11(1) : 83-91

Published By: Wildlife Disease Association

URL: <https://doi.org/10.7589/0090-3558-11.1.83>

---

BioOne Complete ([complete.BioOne.org](https://complete.BioOne.org)) is a full-text database of 200 subscribed and open-access titles in the biological, ecological, and environmental sciences published by nonprofit societies, associations, museums, institutions, and presses.

Your use of this PDF, the BioOne Complete website, and all posted and associated content indicates your acceptance of BioOne's Terms of Use, available at [www.bioone.org/terms-of-use](https://www.bioone.org/terms-of-use).

Usage of BioOne Complete content is strictly limited to personal, educational, and non - commercial use. Commercial inquiries or rights and permissions requests should be directed to the individual publisher as copyright holder.

---

BioOne sees sustainable scholarly publishing as an inherently collaborative enterprise connecting authors, nonprofit publishers, academic institutions, research libraries, and research funders in the common goal of maximizing access to critical research.

## INCLUSION BODY DISEASE (HERPESVIRUS INFECTION) OF FALCONS (IBDF)

DAVID L. GRAHAM,<sup>1</sup> C. JOHN MARE,<sup>2</sup> F. PRESCOTT WARD<sup>3</sup>  
and MALCOLM C. PECKHAM<sup>4</sup>

**Abstract:** Inclusion body disease of falcons (IBDF) is caused by a herpesvirus. The clinical course is short, 24 to 72 hours in duration, and is characterized by mild to severe depression and weakness often accompanied by anorexia. The disease is invariably fatal. The virus has a marked affinity for the reticuloendothelial system and hepatocytes, producing focal to diffuse necrosis of infected tissues accompanied by the formation of intranuclear inclusion bodies. The virus is pathogenic for American kestrels (*Falco sparverius*) and great horned owls (*Bubo virginianus*) in which typical lesions of IBDF are reproduced. The lesions of IBDF are similar to those produced by some herpesvirus infections in other avian species.

Necrosis of various components of the reticuloendothelial system and of the liver, in some instances accompanied by the development of intranuclear inclusion bodies has been recognized as a feature of certain diseases occurring in several avian species. Among these diseases are goose hepatitis, from which a parvovirus has been isolated,<sup>27,28,29</sup> owl hepatosplenitis<sup>4,5,6,7,25,26</sup> herpesvirus infection of pigeons,<sup>8,9,10,11,12</sup> and duck virus enteritis<sup>3,17,18</sup> for which herpesviruses are known to be etiological agents. Other examples are inclusion body hepatitis of chickens,<sup>14,15,23,30</sup> Pacheco's parrot disease<sup>1,13,21,22,24</sup> and a disease of muscovy ducks described by Kaschula,<sup>16</sup> all of presumed but unproven viral etiology.

In 1971 Ward and co-workers<sup>31</sup> described a previously unreported disease in a prairie falcon (*Falco mexicanus*). The clinical course was short, approximately 40 hours, and was characterized by anorexia and listlessness. Post-mortem findings were multiple necrotic foci in the liver, spleen, bone marrow, and intestinal wall. Intranuclear inclusions were found in cells adjacent to the necrotic

regions. A herpesvirus was suggested as the etiological agent. Lesion material from the prairie falcon was found to be infectious for embryonated chicken eggs and for American kestrels (*F. sparverius*) in which the lesions described above were reproduced.

Since the appearance of this first report eight other cases of the disease have been diagnosed in captive falcons. The purpose of the present report is to summarize the clinical and pathological findings in these cases and to describe the disease as it was experimentally reproduced in other raptorial species.

### CASE REPORTS OF FIELD CASES OF IBDF

The clinical, pathological and virological findings are summarized in Table 1.

#### Clinical Findings

##### Case 1

A 4- to 5-month old male prairie falcon died following a 72-hour period of anorexia, listlessness, and weight loss.

<sup>1</sup> Department of Veterinary Pathology, Iowa State University, Ames, Iowa 50010.

<sup>2</sup> Department of Veterinary Microbiology and Preventive Medicine, Iowa State University, Ames, Iowa.

<sup>3</sup> Veterinary Medicine Department, Medical Research Laboratory, Edgewood Arsenal, Maryland.

<sup>4</sup> Department of Avian Diseases, Cornell University, Ithaca, New York.

TABLE 1. Summary of the Clinical, Pathological, and Virological Aspects of Field Cases of IBDF.

Case	Species	Sex	Age	Clinical Signs										Lesions					concurrent disease
				anorexia	weakness and depression	regurgitation	diarrhea	weight loss	duration of illness (hours)	spleen	bone marrow	alimentary tract	liver	other	intranuclear inclusions	FHV isolated (strain)			
1	Prairie falcon ( <i>F. mexicanus</i> )	M	4-5 mo.	+	+	-	-	+	72	+	A*	+	+	+	-	A*	S-18	+	
2	Red headed falcon ( <i>F. chicquera</i> )	F	mature	-	+	-	-	-	72	-	+	+	+	+	+	A*	H-4	-	
3	Prairie falcon	M	14 wks.	+	+	-	-	-	48	-	+	+	+	-	-	+	H-5	-	
4	Peregrine falcon ( <i>F. peregrinus tundrius</i> )	F	4-5 mo.	+	+	-	-	+	? <sup>d</sup>	+	-	-	-	-	+	+	2-A	+	
5	Prairie falcon	NR	NR	+	+	-	-	-	24	+	-	-	-	-	+	+	none <sup>e</sup>	+	
6	Gyrfalcon ( <i>F. rusticolus</i> )	M	18 mo.	+	+	-	-	-	72	+	+	+	+	-	-	+	none <sup>e</sup>	-	
7	Prairie falcon	M	6-7 wks.	+	+	-	+	+	72+	+	+	+	+	+	-	+	H-48	-	
8	Prairie falcon	F	10 mo.	+	+	+	-	-	63	+	+	+	+	+	+	+	S-55	-	

<sup>a</sup> Autolysis precluded evaluation.

<sup>b</sup> Serratospiculiasis.

<sup>c</sup> Focal necrosis in ovarian stroma.

<sup>d</sup> Aspergillosis.

<sup>e</sup> Virus isolation not attempted.

<sup>f</sup> Intranuclear inclusions in adrenal gland.

NR = Not recorded.

**Case 2**

A mature female red-headed falcon (*F. chicquera*) became listless and depressed and was treated empirically for trichomoniasis with Emtryl® and Terramycin.® The bird died 72 hours after the onset of signs having maintained both its appetite and body weight.

**Case 3**

A 14-week old male prairie falcon in training for falconry was observed to be flying less vigorously than normal. Lethargy and depression progressed rapidly. Because of anorexia the bird was force-fed a small amount of meat and egg yolk but died within 48 hours of the onset of signs of illness.

**Case 4**

An immature female peregrine falcon (*F. pergrinus tundrius*) was banded on Assateague Island, Maryland, during fall migration and was released in an apparently healthy state. Sixteen days later the bird was again trapped 250 miles south of the original capture location. At recapture the bird was thin, appeared ill, and was taken into captivity. Three days later its appetite decreased and it began to lose weight. One week following recapture radiographs were taken and revealed intrathoracic nodules suggestive of a mycotic infection. The falcon was treated with Amphotericin-B on the basis of a presumptive diagnosis of pulmonary aspergillosis. The bird died about 2 hours later.

**Case 5**

A prairie falcon of unreported age and sex became suddenly depressed and anorexic and died within 24 hours of the onset of clinical illness.

**Case 6**

A male gyrfalcon (*F. rusticolus*), approximately 18 months old and trained for falconry, suddenly became listless and easily fatigued. Anorexia occurred and the bird died about 72 hours after the illness was first noted.

**Case 7**

A male prairie falcon was being flown at liberty with its 2 siblings, a male and a female. The birds routinely returned twice a day to feed on a ledge outside the nest box in which they had been reared. At 41 days of age the male in question was absent and was obviously ill upon his return and recapture 2 days later. He was anorexic, weak, had ruffled feathers, and watery green feces. The bird was fed pureed meat by gavage and was treated daily with an oral antibiotic but died 3 days after recapture. Its siblings remained healthy.

**Case 8**

A 10-month old female prairie falcon had a decreased appetite one evening. The next morning it ate a few small pieces of meat which were regurgitated within 2 hours. The bird was treated empirically with Emtryl.® On the second day of illness the falcon was treated with Fungizone® on the basis of a presumptive diagnosis of aspergillosis. The results of fecal examination were negative for parasites or their eggs. The bird died after 63 hours of clinical illness.

**POST-MORTEM EXAMINATION**

Necropsies were performed upon fresh cadavers (cases 3, 4, and 8), and upon cadavers that had been frozen and rapidly thawed (cases 1, 2, and 7). In 2 instances (cases 5 and 6) only histological material and necropsy reports were available to the authors; photographic records of the lesions and virus isolation attempts were thus precluded. A report on the parasitological diagnosis (serratospiculiasis) on case 5 has been published.<sup>2</sup>

**Post-mortem Findings****Gross Lesions**

The lesions in the livers and spleens of all 8 birds were similar. There was slight to marked hepatomegaly and splenomegaly. The normally concave visceral surfaces of the liver lobes were flat in some of the birds, or in some cases, con-

vex. Both organs were heavily studded with many pale tan, yellow, or yellow-grey punctate, spherical, and stellate foci ranging from pinpoint size to 1.5 mm in diameter (Fig. 1). Small focal lesions were visible in the immediately subcapsular parenchyma; the larger solitary foci as well as larger regions of apparent lesion coalescence produced dome-like elevations on the surfaces of the organs.

Gross examination of cut surfaces of the livers and spleens revealed that the focal lesions were heavily and evenly distributed throughout the parenchyma of both organs. The larger lesions contained friable, caseous material.

In cases 1, 2, and 8 the small intestines were reddened and there were several to many light tan puncta (Fig. 2) and short transverse streaks visible through the serosa.

Examination of the tibial bone marrow of cases 2, 3, 6, 7, and 8 revealed innumerable white to tan nodules or granules (0.5 to 1.0 mm) distributed throughout the light reddish brown to purple brown marrow matrix. The light granular foci were relatively more firm than, and thereby separable from the softer marrow tissue.

There were several adult air sac worms (*Serratospiculum amaculata*) in the abdominal and posterior thoracic air sacs of two of the prairie falcons (cases 1 and 5). These are considered by the authors to be incidental findings. In the peregrine falcon (case 4), plaque-like air sac lesions and focal caseous lung lesions of aspergillosis were found.

#### Microscopic Examinations

All tissues were fixed in 10% formalin and were processed by the standard




FIGURE 1. Multiple foci of necrosis in the spleen (held in forceps) and liver of a prairie falcon (case 8).

paraffin section technique. The sections were stained with hematoxylin and eosin (H and E).

The livers contained many discrete non-zonally distributed spherical foci of coagulation necrosis characterized by karyolysis and homogeneous eosinophilia of the granular to amorphous cell remnants. Occasional pycnotic nuclei and basophilic nuclear fragments were sparsely scattered through the necrotic areas; in the centers of some foci, particularly the larger ones, there was a dense accumulation of nuclear debris.

Intranuclear inclusion bodies were found in the hepatocytes and histiocytes adjacent to the periphery of the necrotic regions. There was a continuum of inclusion morphology and staining ranging from large pan-nuclear basophilic inclusions to centrally disposed eosinophilic bodies separated from the peripherally

condensed chromatin by a clear or at least hypochromatic halo (Fig. 3).

The splenic lesions were essentially identical to those of the livers described above. They were sometimes so numerous that the reticuloendothelial parenchyma, as well as the stromal and vascular scaffold of the organ were obliterated by the coalesced foci. Intranuclear inclusions, though present, were generally less numerous than in the livers.

In the bone marrows the grossly observed focal lesions were found to be islands of coagulative necrosis, often containing much nuclear debris, in a sea of degenerating erythroid and myeloid elements. The marrow sinusoids and vessels were intact except in the areas of coagulation necrosis. In the gyrfalcon (case 6) there was necrosis of the bone marrow in the myeloid spaces of the ossified tracheal rings. Inclusion bodies were present but not numerous.

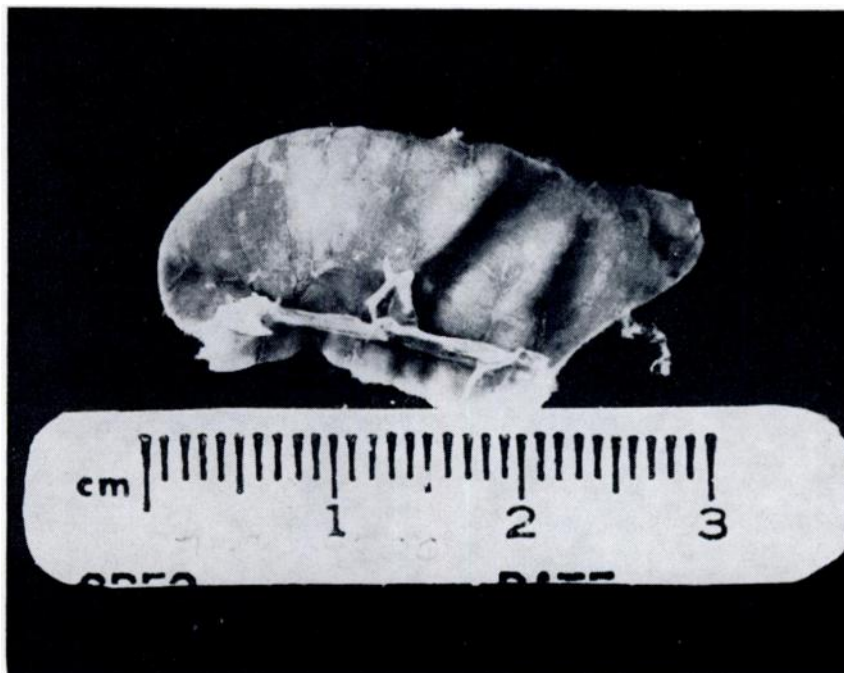

FIGURE 2. Pale tan foci in the submucosa are visible through the serosal surface of the intestine of a red-headed falcon (case 2).

In the intestinal tract the focal necrotic lesions were limited to the *lamina propria* and were poorly circumscribed. There were discrete foci of necrosis in the lymphoid cell accumulations of the vestigial ceca ("cecal tonsils") of cases 7 and 8. Inclusion bodies were not consistently found in the intestinal lesions.

The ovarian stroma of the red-headed falcon (case 2) contained one small focus of necrosis.

There were several areas of the adrenal glands of one prairie falcon (case 8) in which large pale magenta intranuclear inclusion bodies were locally numerous but were not accompanied by necrosis.

#### Microbiological Examinations

Lesion material suitable for microbiological examination was available from cases 1, 2, 3, 4, 7, and 8.

No bacteria or mycoplasmas were isolated from the liver, spleen and bone marrow lesions examined.

Tissue emulsions were prepared from liver and spleen (cases 1, 2, and 4), liver (cases 7 and 8), or bone marrow (case 3) and were used to inoculate the chorioallantoic membrane (CAM) of embryonated chicken eggs, or cell cultures of chicken embryo fibroblasts (CEF) or duck embryo fibroblasts (DEF). On primary inoculation or second passage in chicken embryos focal white thickenings of the CAM and multifocal necrotic lesions in the livers and spleens of the embryos were observed. Intranuclear inclusions occurred in and around the lesions. In cases 1 and 2 the initial virus isolations were performed by chicken embryo inoculation as described above. Suspensions of the CAM lesions were used to inoculate CEF and DEF cell cultures. In cases 3, 4, 7, and 8

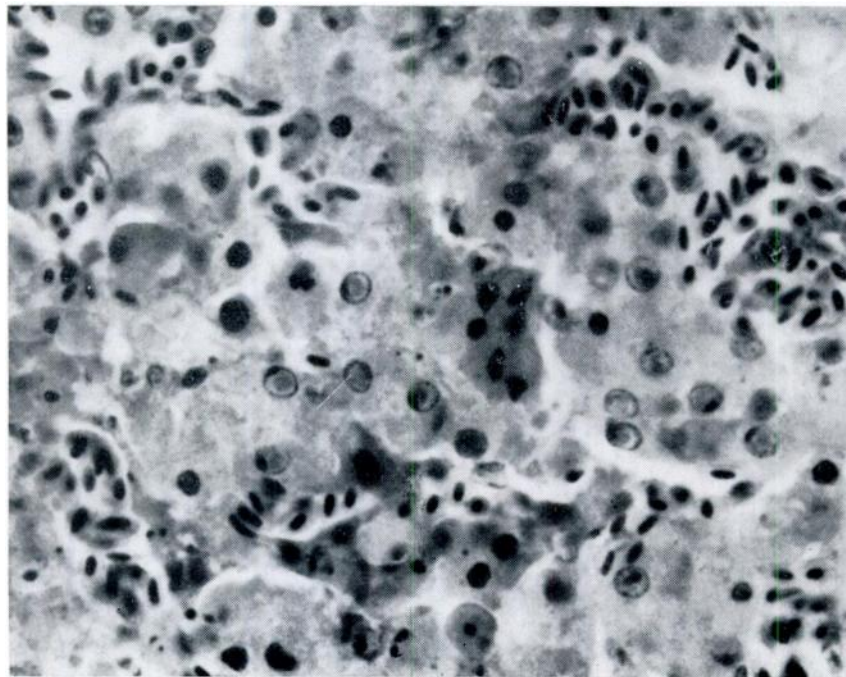


FIGURE 3. Intranuclear inclusion bodies in a liver lesion from a prairie falcon (case 3). H&E x 750.



primary isolations were accomplished on cell culture. All 6 isolates were maintained in cell culture in which they produced the typical cytopathic effect of herpesviruses consisting of cell rounding, syncytium formation, and the development of intranuclear inclusion bodies. Physical, chemical, and serological characterization studies have shown that these virus isolates are members of the herpesvirus group (20).

#### TRANSMISSION STUDIES

Cell-culture-propagated virus isolated from case 1 (FHV S-18) was inoculated into 8 kestrels, 3 great horned owls, and 3 pigeons (*Columba livia*). The dose of virus ranged from  $10^{3.0}$  TCID<sub>50</sub> to  $10^{4.5}$  TCID<sub>50</sub> per inoculum. A suspension of liver tissue from case 5 containing virus FHV 2-A was inoculated into a great horned owl and a suspension of CAM lesions from embryonated eggs infected with FHV 2-A was inoculated into a kestrel and 2 pigeons. All inoculations were administered intramuscularly.

#### Clinical Observations

The kestrels died 4 to 6 days post inoculation (PI). Clinical signs of illness were mild (anorexia and listlessness for 24 to 48 hours ante-mortem), or were altogether absent. One kestrel ate a full meal 5 hours before it died. The owls died 7 to 10 days PI having shown anorexia during their terminal 24 to 72 hours. The pigeons remained clinically normal until they were killed 60 to 90 days PI.

#### Hematological Studies

Blood samples were collected by jugular venipuncture from 3 of the kestrels from 1 to 6 hours ante-mortem. Total leukocyte (WBC) counts were made using the method of Rees-Ecker as described by Lucas and Jamroz.<sup>19</sup> Two of the birds had 350 WBC's/mm<sup>3</sup> and the third had 600 WBC's/mm<sup>3</sup>. Pre-inoculation blood samples contained from  $6.8 \times 10^3$  to  $22.5 \times 10^5$  WBC/mm<sup>3</sup>. There was no anemia.

#### Post-mortem Findings

The lesions observed in the kestrels and owls were similar. There were myriad focal tan to yellow-tan lesions in the livers, spleens and bone marrows. Histologically the lesions were qualitatively identical to those observed in the previously described field cases, i.e. foci of necrosis with the formation of intranuclear inclusion bodies in cells peripheral to the limits of necrosis. Similar lesions, which had apparently originated in accumulations of lymphoreticular cells, were found in a variety of other organs although no one bird had lesions in all sites. Lesions were found in the submucosa or *lamina propria* of the tongue, pharynx, esophagus, esophageal-proventricular junction, proventriculus, ventriculus, small intestine, cecum, bronchioles, the thymus gland, the subependymal connective tissue in the choroid plexus, and the interstitium of the kidney, pancreas, thyroid gland and gonads. Intranuclear inclusions but no necrosis were observed in some adrenal glands. Organs which were examined but in which no lesions were found were the parathyroid gland, heart, eye, and uropygial gland.

There were no lesions in the pigeons.

#### DISCUSSION

Herpesvirus infection of falcons is a disease with a short (24 to 72 hour) clinical course characterized by the relatively non-specific signs of partial or complete anorexia and listlessness. The mild nature of the signs belies the rapidly fatal course of the disease. In experimental cases the incubation period was likewise short, the PI interval to death ranging from 4 to 6 days for kestrels and 7 to 10 days for owls.

The lesion distribution in the field cases and experimental cases indicate a strong affinity of the virus for reticulo-endothelial tissues, particularly for the lymphoreticular elements, and also for hepatocytes. "Inclusion body disease (herpesvirus infection) of falcons" is suggested as a more appropriate name for the disease. Destruction of the bone marrow and of the various lymphoreticu-



lar cell foci throughout the body accounts for the severe terminal leukopenia and for the conspicuous absence of inflammatory cell response in the peripheral regions of the necrotic foci. Failure of the birds to evidence a terminal anemia in spite of necrosis of the erythropoietic tissue is a reflection of the relatively longer half-life of erythrocytes compared to that of leukocytes. That the birds which were experimentally inoculated with FHV undoubtedly received a far higher infecting dose by a more direct route than did the field cases presumably explains the wider distribution of lesions in the former group.

The sources and routes of infection

for the field cases are not known. We agree with the suggestion of Ward *et al.*<sup>81</sup> that certain of the falcon's prey species (or food species in the case of captive falcons) may be subject to mild or subclinical infection with the FHV and thus serve as sources of infection for the falcons.

The striking qualitative similarities between the lesions of falcon herpesvirus infection and those described in owl herpesvirus infection, pigeon herpesvirus infection, duck virus enteritis, and Pacheco's parrot disease indicate that comparative studies on the pathogenicity and serological interrelationships of these viruses are warranted.

#### Acknowledgments

The authors are indebted to Dr. C. H. Bigland, University of Saskatchewan, Saskatoon, Saskatchewan, and to Dr. M. Berthrong, Penrose Hospital, Colorado Springs, Colorado for providing histological material from cases 5 and 6, respectively.

#### LITERATURE CITED

1. ANDREWES, C. H. and H. G. PEREIRA. Viruses of Vertebrates. 2nd ed. The Williams and Wilkins Co., Baltimore, 1967.
2. BIGLAND, C. H., S. LIU and M. L. PERRY. Five cases of *Serratospiculum amaculata* (Nematoda: Filarioidea) infection in prairie falcons (*Falco mexicanus*). Avian Disease 8: 412-419. 1964.
3. BREESE, S. S. and A. H. DARDIRI. Electron microscopic characterization of duck plague virus. Virology 34: 160-169. 1968.
4. BURTSCHER, H. Die virusbedingte Hepatosplenitis infectiosa strigorum I. Mitteilung: Morphologische Untersuchungen. Pathologia Veterinaria 2: 227-255. 1965.
5. BURTSCHER, H. Über eine virusbedingte Einschlusskörperchen—Hepatitis und —Lienitis bei Eulenvögeln. Zentralblatt für Allgemeine Pathologie und Pathologisch Anatomie 107: 96. 1965.
6. BURTSCHER, H. Die virusbedingte Hepatosplenitis infectiosa strigum II. Mitteilung: Kultur-und Infektionsversuche. Zentralblatt für Veterinarmedizin Reihe B 14: 540-554. 1968.
7. BURTSCHER, H. and A. SCHUMACHER. Morphologische Untersuchungen zur Virusätiologie der Hepatosplenitis infectiosa strigum. Pathologia Veterinaria 3: 506-528. 1966.
8. CORNWELL, H. J. C. and A. R. WEIR. Herpesvirus infection of pigeons III. Use of embryonated eggs for the growth and characterization of the virus. Journal of Comparative Pathology 80: 509-515. 1970.
9. CORNWELL, H. I. C. and A. R. WEIR. Herpesvirus infection of pigeons IV. Growth of the virus in tissue culture and comparison of its cytopathogenicity with that of the viruses of laryngo-tracheitis and pigeon-pox. Journal of Comparative Pathology 80: 517-522. 1970.

10. CORNWELL, H. J. C. and N. G. WRIGHT. Herpesvirus infection of pigeons I. Pathology and virus isolation. *Journal of Comparative Pathology* 80: 221-227. 1970.
11. CORNWELL, H. J. C., A. R. WEIR and E. A. C. FOLLETT. A herpesvirus infection of pigeons *The Veterinary Record* 81: 267-268. 1967.
12. CORNWELL, H. J. C., N. G. WRIGHT and H. B. McCUSKER. Herpesvirus infection of pigeons II. Experimental infection of pigeons and chicks. *Journal of Comparative Pathology* 80: 229-232. 1970.
13. FINDLAY, G. M. Pacheco's parrot disease. *The Veterinary Journal* 89: 12. 1933.
14. HELMBOLDT, C. F. and M. N. FRAZIER. Avian hepatic inclusion bodies of unknown significance. *Avian Diseases* 7: 446-450. 1963.
15. HOWELL, J., D. W. MacDONALD and R. G. CHRISTIAN. Inclusion body hepatitis in chickens. *Canadian Veterinary Journal* 11: 99-101. 1970.
16. KASCHULA, V. R. A new virus disease of the muscovy duck (*Cairina moschata* L.) present in Natal. *Journal of the South African Veterinary Medical Association* 21: 18. 1950.
17. LEIBOVITZ, L. Gross and histopathologic changes of duck plague (duck virus enteritis). *American Journal of Veterinary Research* 32: 275-290. 1971.
18. LEIBOVITZ, L. Duck plague (duck virus enteritis). Page 732 in M. S. Hofstad, ed. *Diseases of Poultry*. 6th ed. The Iowa State University Press, Ames, Iowa. 1972.
19. LUCAS, A. M. and C. JAMROZ. Atlas of avian hematology. U.S. Department of Agriculture, Agriculture Monograph 25. 1961.
20. MARE, C. J. and D. L. GRAHAM. Falcon Herpesvirus, the Etiologic Agent of Inclusion Body Disease of Falcons. *Infection and Immunity* 8: 118-126. 1973.
21. PACHECO, G. Nouvelles recherches sur la psittacose des perroquets. *Comptes Rendus Société de Biologie* 106: 372-374. 1931.
22. PACHECO, G. and O. BIER. Epizootie chez les perroquets du Brésil. Relations avec la psittacose. *Comptes Rendus Société de Biologie* 105: 109-111. 1930.
23. PETTIT, J. R. and H. C. CARLSON. Inclusion body hepatitis in broiler chickens. *Avian Diseases* 16: 858-863. 1973.
24. RIVERS, T. M. and F. F. SCHWENTKER. A virus disease of parrots and parakeets differing from psittacosis. *The Journal of Experimental Medicine* 55: 911-924. 1932.
25. SCHESSLER, C. H. Eine infektiöse Leberentzündung (Hepatitis) der Eulen. *Tierärztliche Umschau* 163: 1-6. 1969.
26. SCHESSLER, C. H. *In vitro* Untersuchungen über die Eigenschaften des Virus der Hepatitis et Splenitis Infectiosa Strigum. Proc. XII Internationalen Symposiums über die Erkrankungen der Zootiere, Budapest. 205-209. 1970.
27. SCHESSLER, C. H. Isolation of a highly pathogenic virus from geese with hepatitis. *Avian Dis.* 15: 323-325. 1971.
28. SCHESSLER, C. H. Virus hepatitis of geese II. Host range of goose hepatitis virus. *Avian Dis.* 15: 809-823. 1971.
29. SCHESSLER, C. H. Goose virus hepatitis in the Canada goose and snow goose. *Journal of Wildlife Diseases* 7: 147-148. 1971.
30. SENEVIRATNA, P. *Diseases of Poultry*. 2nd ed. John Wright and Sons Ltd., Bristol. 1969.
31. WARD, F. P., D. G. FAIRCHILD and J. V. VUICICH. Inclusion body hepatitis in a prairie falcon. *Journal of Wildlife Diseases* 7: 120-124. 1971.

Received for publication 9 August 1973