

ORAL FIBROMA IN A CAPTIVE PYTHON

Authors: IDOWU, A. L., GOLDING, R. R., IKEDE, B. O., HILL, D. H., CUNNINGHAM, J. H., et al.

Source: Journal of Wildlife Diseases, 11(2) : 201-204

Published By: Wildlife Disease Association

URL: <https://doi.org/10.7589/0090-3558-11.2.201>

BioOne Complete (complete.BioOne.org) is a full-text database of 200 subscribed and open-access titles in the biological, ecological, and environmental sciences published by nonprofit societies, associations, museums, institutions, and presses.

Your use of this PDF, the BioOne Complete website, and all posted and associated content indicates your acceptance of BioOne's Terms of Use, available at www.bioone.org/terms-of-use.

Usage of BioOne Complete content is strictly limited to personal, educational, and non - commercial use. Commercial inquiries or rights and permissions requests should be directed to the individual publisher as copyright holder.

BioOne sees sustainable scholarly publishing as an inherently collaborative enterprise connecting authors, nonprofit publishers, academic institutions, research libraries, and research funders in the common goal of maximizing access to critical research.

ORAL FIBROMA IN A CAPTIVE PYTHON

A. L. IDOWU, R. R. GOLDING, B. O. IKEDE, D. H. HILL, J. H. CUNNINGHAM*,

S. B. AKERELE,** Department of Veterinary Medicine and Surgery, Department of Zoology and Veterinary Pathology, University of Ibadan, Nigeria.

Abstract: A massive growth in the lower jaw of an Indian python (*Python molurus*) was diagnosed from biopsy samples as a fibroma. Moderately satisfactory treatment was achieved by surgical excision.

INTRODUCTION

Although snakes in captivity may live for several years, there are few reports of neoplasms. Wadsworth¹ described an ovarian adenocarcinoma and a cystadenoma of the stomach, respectively, in two pythons. Cowan¹ reported eleven tumors in captive reptiles, seven of which were snakes. These were classified as bile duct adenoma, adenocarcinoma of the colon, abdominal sarcoma, leiomyosarcoma and lymphosarcoma. Fuinie² reported a case of lymphoid leucosis in an Indian python. Exuberant granulation tissues which might be confused with neoplasms have been reported more frequently.³

This paper records the clinical features, surgical excision and histopathology of a growth in the mouth of a captive python in the University Zoo, Department of Zoology, University of Ibadan.

CASE HISTORY

The subject was a 10-year-old Indian Python (*Python molurus*), 4.0 m long and weighing about 60 kg. It was imported into Nigeria in 1965 at 3 years of age, and was kept during the next 5 years and before transfer to a suitably modified car garage, in a wooden box 1.5 x 1.0 x 1.0 m fitted with glass panels

on one side. It was fed weekly on rats or whole chickens, and later at twice weekly intervals on whole, young dwarf goats weighing about 4-6 kg. It was observed that on these occasions when the python was hungry, and for some reason there was a delay in obtaining food of perhaps a day or so, the snake moved slowly around the cage, rubbing its mouth at regular intervals on the glass panels.

In May, 1971, a small swelling was observed in the anterior part of the lower jaw, around the frenulum of the tongue sheath. Chronic stomatitis was diagnosed and the snake was treated intramuscularly with procaine penicillin at 10,000 I.U./kg body weight for 4 days, followed by chloramphenicol at 50 mg/kg every other day for 2 weeks. Chloramphenicol with hyaluronidase solution was then given for a further 3 weeks. The latter was added to facilitate the absorption of the intramuscularly injected antibiotic into the body circulation, as it has been experienced that snakes build fibrotic tissue walls around injected solutions, which prevents absorption. As no marked improvement was apparent, the last treatment was repeated in combination with ascorbic acid at 1 mg/kg for another period of 2 weeks. Ascorbic acid, in therapeutic dose, has been found to be very effective in the treatment of oral lesions in snakes.

* University of Davis, California, while visiting Nigeria.

**Veterinary Division and The Ministry of Agriculture and Natural Resources, Western State, Nigeria.

By December, 1971, the growth had become massive, completely covering the lower arcades of the teeth and causing the lower lip to protrude about 5 cm anterior and 2 cm lateral to the facial outline. The surface of the growth was covered by oral mucosa. There was no ulceration or suppuration, although grayish necrotic areas were visible adjacent to the teeth. It was decided to take a biopsy sample. The python was placed in a deepfreezer at -20°C for 45 min, followed by light inhalation anaesthesia with ether. Biopsy specimens were taken aseptically for histopathological and microbiological examination. The previous treatment with antibiotics and ascorbic acid was continued for a further 3 weeks.

On 30th December, 1971, there was infection and necrosis of the tissue around the biopsy site. The mass continued to grow and by April, 1972, it partially occluded the pharynx. Because of the separation of the lower jaw bones and teeth and the protrusion of the lower lip, the animal had difficulty in grasping food. However, once the food item had reached the throat region, swallowing continued normally. At no time did the appetite become diminished, although the feeding frequency was deliberately reduced about 10 weeks before surgery. The general appearance of the snake always appeared excellent.

Lateral and dorsoventral radiographs of the head showed that the growth did not affect any bony structure. Consequently, the snake was prepared for surgery and the growth was removed on 1st May, 1972.

Surgical Procedure:

General anaesthesia was induced in 45 min by confining the python in a closed box with ether soaked pads. The snake was intubated with a No. 7.5 gauge endotracheal tube to facilitate respiration. The posterior part of the mouth was packed with cotton gauze. The surgical site was prepared for aseptic surgery. A horseshoe shaped incision following the outline of the lower jaw was made in the oral mucous membrane covering the growth. This membrane was reflected

backwards and the growth bluntly dissected from the surrounding connective tissues. Particular care was taken to avoid damage to the tongue and its sheath. The growth was found to be fixed in position outwardly and posteriorly by two fibrous bands. These were doubly ligated and severed. Haemorrhage was minimal and controlled by compression.

The tissues around the biopsy wound were debrided and closed with 5 x "0" catgut. The large pocket between the oral mucosa and the floor of the jaw, created by the removal of the mass, was closed by suturing the submucosa to the subcutaneous tissues with through-and-through patterns of catgut inserted at random. The edge of the flap of oral mucosa was trimmed and affixed to the edge of the mucosa of the lip with interrupted catgut sutures. Recovery from anaesthesia was uneventful.

Postoperative care included daily intramuscular injections of 200-300 mg ascorbic acid on alternate days for 5 weeks. The mouth was alternatively flushed with hydrogen peroxide and dusted with nystatinchlorotetracycline powder for 3 weeks to prevent infection.

Six weeks after the operation the snake was fed a chicken. Four months later it could take a small whole goat. The incision wounds healed completely without complications. The snake continued in apparent good health, but in September, 1973, there were signs of recurrence of the tumor. By May, 1974, 2 years from the first operation, it was decided to operate again, although at this time the animal was still in good condition. The only modification of the previous operative procedure was the use of the closed method of anaesthesia with Boyle's Mark II anaesthetic equipment, ether and oxygen. Recovery has been uneventful to date (12.6.74).

LABORATORY EXAMINATION

Microbiology:

No pathogen was isolated from the original biopsy and the excised growth after routine culture for 72 h in blood agar and Sabouraud's media.

Histopathology:

The growth consisted of interlacing bundles of elongated cells with spindle-shaped vesicular nuclei and prominent single nucleoli. A few binucleated syncytial cells were present (Fig. 1). The cells were widely separated by abundant eosinophilic fibrillar ground substance which stained positive for collagen with

Masson's trichrome stain (Fig. 2). In some areas the surface of the mass was ulcerated and the blood vessels beneath the ulcers contained fibrin thrombi. The mass was for the most part poorly vascularized and mitoses were not common. On the basis of its biological and histological features, the growth was diagnosed as an ulcerated fibroma.

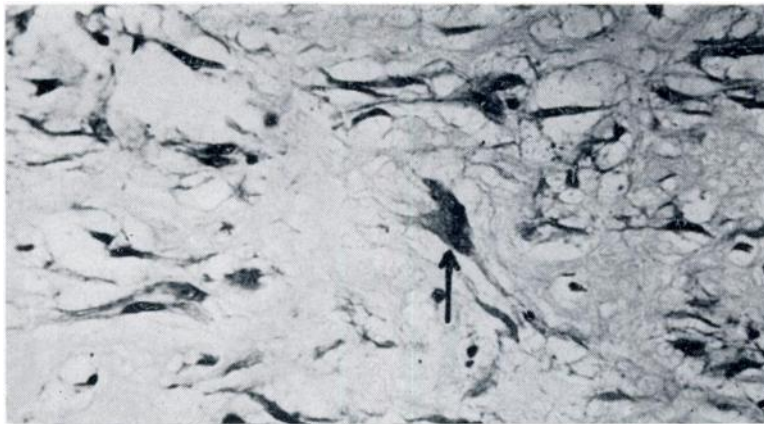


FIGURE 1. Python fibroma; binucleated syncytial cells (Arrow) H & E, x 750

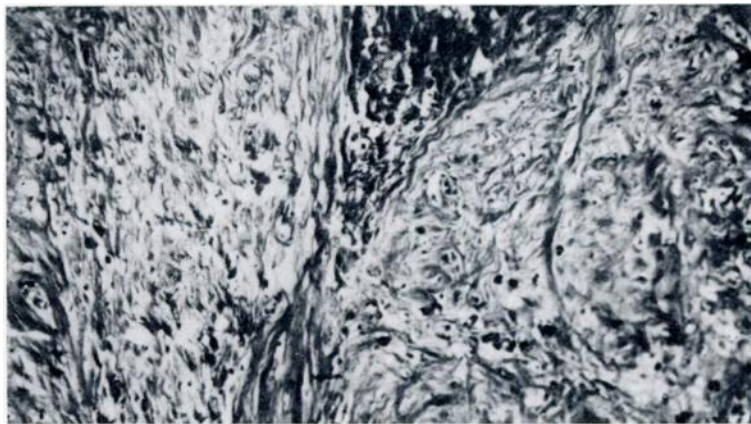


FIGURE 2. Masson's trichrome positive collagen ground substance. Masson's trichrome stain. X360

DISCUSSION

The surgical technique was simple and effective. In 14 months after the operation there was no apparent recurrence of the growth. However, smaller size goats were fed to the snake, as there seemed to be reduction in the elasticity of the tissues of the mouth. As stated earlier, however, regrowth was later observed and the operation was repeated 24 months after the first operation. Because of the reported frequency of exuberant granulation in cold blooded animals the growth in this python was initially attributed to chronic proliferative inflammation. Treatments with antibiotics and with other chemotherapeutic agents and

hyaluronidase for several months were without effect, and no infectious agent was isolated from the growth. Nevertheless, chronic irritation was a most likely predisposing factor in the genesis of the mass. The growth was poorly vascularized and the few blood vessels present lacked any orderly arrangement as would be the case in granulation tissue. Infection and ulceration were observed only as a complication of the previous biopsy.

It would appear that the condition was predisposed by the rubbing of the lower lip against the glass front of the box during periods of hunger. Management procedures to reduce this habit are indicated, also the use of larger enclosures.

LITERATURE CITED

1. COWAN, D. F. 1968. Diseases of captive reptiles. *J. Am. vet. med. Ass.* 153: 848-859.
2. FUINIE, E. P. 1972. Lymphoid leucosis in an Indian python (*Python molurus*). *J. Path.* 107: 295-297.
3. LUCKE, B. and SCHUMBERGER, H. G. 1949. Neoplasia in cold-blooded vertebrates. *Phys. Rev.* 29: 91-126.
4. WADSWORTH, J. R. 1956. Serpentine tumours. *Vet. Med.* 51: 326.

Received for publication 25 July 1974