

ON THE OCCURRENCE OF GANGLIONEUROMA AND CYSTS OF *Henneguya ophiocephali* CHAKRAVARTY 1938 IN A FISH

Author: GILL, B. S.

Source: Journal of Wildlife Diseases, 11(3) : 314-317

Published By: Wildlife Disease Association

URL: <https://doi.org/10.7589/0090-3558-11.3.314>

BioOne Complete (complete.BioOne.org) is a full-text database of 200 subscribed and open-access titles in the biological, ecological, and environmental sciences published by nonprofit societies, associations, museums, institutions, and presses.

Your use of this PDF, the BioOne Complete website, and all posted and associated content indicates your acceptance of BioOne's Terms of Use, available at www.bioone.org/terms-of-use.

Usage of BioOne Complete content is strictly limited to personal, educational, and non - commercial use. Commercial inquiries or rights and permissions requests should be directed to the individual publisher as copyright holder.

BioOne sees sustainable scholarly publishing as an inherently collaborative enterprise connecting authors, nonprofit publishers, academic institutions, research libraries, and research funders in the common goal of maximizing access to critical research.

ON THE OCCURRENCE OF GANGLIONEUROMA AND CYSTS OF *Henneguya ophiocephali* CHAKRAVARTY 1938 IN A FISH

B. S. GILL, College of Veterinary Science, Punjab Agricultural University, Ludhiana, Punjab, India

Abstract: A ganglioneuroma is described on the integument of a fish, *Tengra tengra*, together with intense parasitization of its gill filaments with the protozoon, *Henneguya ophiocephali*.

INTRODUCTION

Ganglioneuroma is a rare tumour of fishes. The authenticated records of its occurrence have been those by Thomas⁷ from a whiting, *Gadus aeglefinus*, Takahashi⁸ in a flat fish, *Limandi yokohami*, Thomas⁹ in a gilt fish, *Sparas auratus*, and Haddow and Blake³ in a megrin, *Lepidorhombus (Zeugopterus) megastoma*.

The present author received a fish, *Tengra tengra*, bearing an outgrowth at the root of the tail fin, and numerous small knobs occurring on the ends of the gill filaments. The outgrowth was diagnosed as ganglioneuroma and the knobs at the ends of gill filaments as cysts of a myxosporidian protozoon, *Henneguya ophiocephali* Chakravarty.^{2,1} Their occurrence in the *T. tengra* and histological details are recorded in this paper.

MATERIALS AND METHODS

The fish was caught from a rivulet near Bareilly, U.P., India. It was preserved in 10% formalin.

Pieces of the outgrowth on the integument and the entire cysts on the gill filaments were dehydrated, cleared and embedded in paraffin. Sections 5-8 μm thick were cut and stained with Heidenhain's iron-alum haematoxylin and haematoxylin-eosin.

Cysts on gill filaments were also

crushed between two microslides; the material thus smeared on their surface was fixed in Schaudinn's fluid and stained with Heidenhain's iron-alum haematoxylin.

RESULTS AND DISCUSSION

1. *Henneguya ophiocephali*

The cysts appeared as knobs, all at the ends of gill filaments (Fig. 1). They occurred either singly as oval or spherical structures 1-2 mm in diameter, or up to eight cysts enclosed in a common layer of the tissue extending from the gill filament, the multilobed structure then attained size up to 5 mm in diameter. The infection was very heavy as a majority of the filaments in all gills was found ending in the protozoon cysts.

Histologically, the cysts consisted of a thick (25-55 μm) outer fibrous layer beneath which lay a densely nucleated syncytial germinal layer from which spores developed. The maturity of cells (pansporoblasts) of the germinal layer increased from without inwards. Below the germinal layer were present sheaves of tightly packed spores. Young cysts consisted solely of a heavily nucleated syncytial mass beneath the fibrous capsule. With development, thickness of the germinal layer decreased progressively with corresponding increase in the space occupied by the fully formed spores.

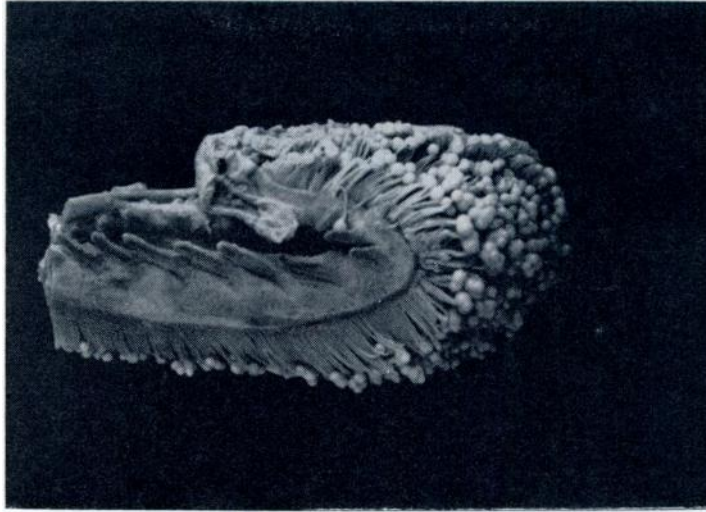
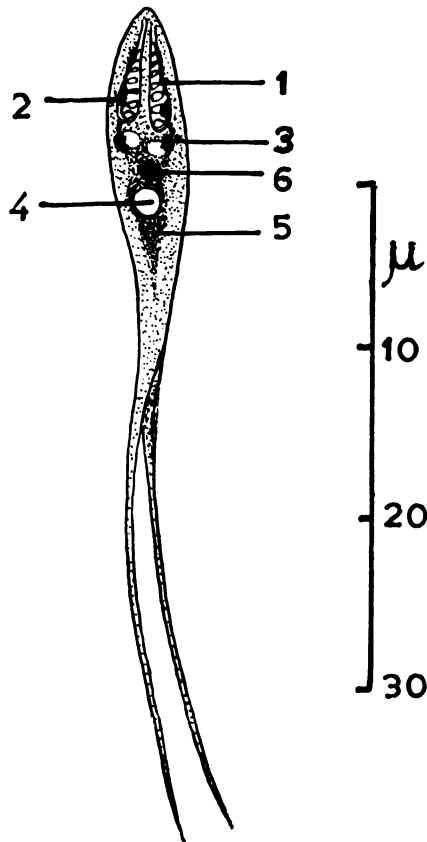


FIGURE 1. Photograph of the infected gill showing cysts of the protozoan, *Henneguya ophiocephali*, at the ends of filaments. Actual size.



Junction of the fibrous capsule and the protozoan tissue was marked by deeply stained layer of tissue which appeared as a heavy line between the two.

Spores examined in crushed preparations revealed detailed structure (Fig. 2). The main body of the spore was ovoidal. The anterior end was more or less rounded and the posterior tapering into a bifurcated tail, the bifurcation extending all along the length of the tail. Total length of the spores was 40 (30-50) μm of which about two-thirds was the length of the bifurcated tail; spore body was 12 (10-16) μm in length. The greatest width of the spores was 3 to 6 μm . Two piri-

FIGURE 2. Camera lucida drawing of spores of *Henneguya ophiocephali*. Heidenhain's haematoxylin.

1. Polar capsule showing coiled filament
2. Nucleus of the polar capsule
3. Shell valve nucleus
4. Vacuole
5. Sporoplasm
6. Nucleus of the sporoplasm

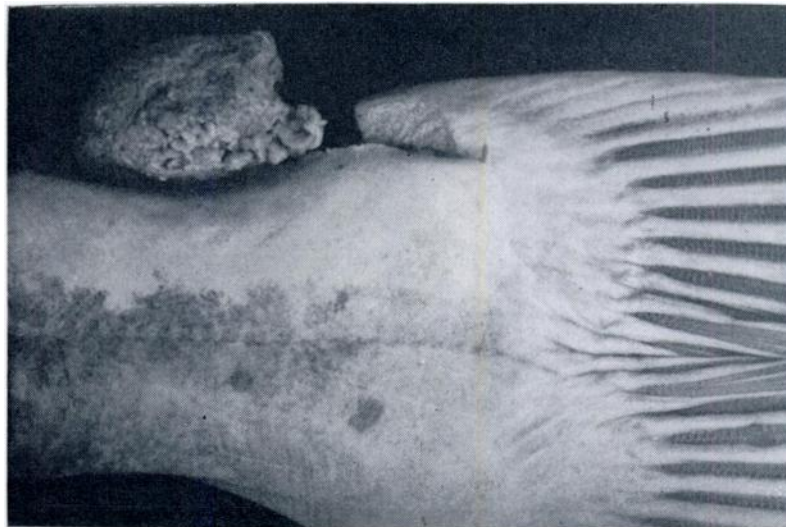


FIGURE 3. Photograph of the tumour—ganglioneuroma. Actual size. (A portion of the tumour at right side has been cut away).

form polar capsules of slightly unequal length were present anteriorly. The capsule was 4.5 (4-6) x 1.25 (1-2) μ m. The capsules were pointed anteriorly. Within the capsule was present a coiled filament, and a nucleus at its base or towards one side. Below the capsules was present the sporoplasm which with Heidenhain's haematoxylin, appeared as a rather darkly staining mass of about the size of the capsules. Within the sporoplasm was seen an oval or circular vacuole 2-3 μ m in diameter. The vacuole occupied no fixed position in the sporoplasm as it occurred near the polar capsules in some specimens, and was seen lying away from them in others. Occasionally, two vacuoles were seen in place of one. The vacuole corresponded to the iodophilous vacuole described by other authors.

The above-noted description corresponded with that of *H. ophiocephali* Chakravarty.³

2. Ganglioneuroma

The tumour was whitish, pedunculate, 3.5 x 3 x 2 cm in size, and was attached to the integument at the base of the tail fin (Fig. 3). It was lobulated and possessed a fine capsule of fibrous tissue.

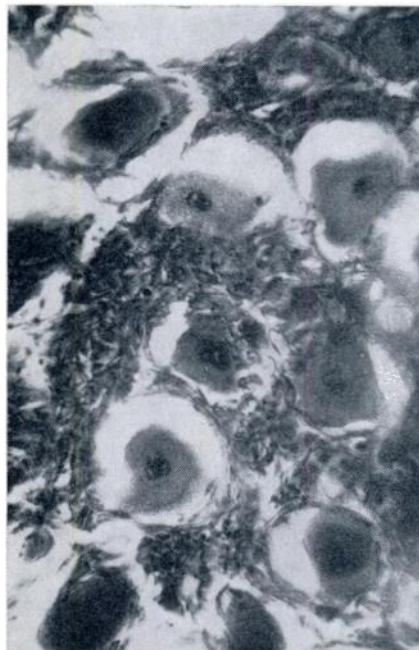


FIGURE 4. Photomicrograph of the tumour showing ganglion cells lying scattered between bundles of nerve fibres. Most of the cells were binucleate. Haematoxylin and eosin, x 450.

Microscopic examination revealed a typical ganglionic neuroma consisting of ganglion cells lying often singly, or as groups scattered among bundles of nerve fibres. The ganglion cells were usually binucleate (Fig. 4). The nuclei were vesicular, each vested with a well-defined nuclear membrane and a single large nucleolus.

Schlumberger and Lucke⁵ and Mawdesley-Thomas⁴ have reviewed neoplasia in fishes. There appear to be few records of tumours of the central nervous system, but peripheral nerve tumours are more common and ganglioneuroma have been reported in three other instances. The present report is an addition to the scarce records of this tumour in fishes.

Acknowledgement

The author expresses his gratitude to Professor E. Cotchin, Royal Veterinary College, London, for his assistance with the diagnosis of the tumour.

LITERATURE CITED

1. BHATIA, B. L. 1938. *The Fauna of British India Including Ceylon and Burma*. Taylor and Francis Ltd., Red Lion Court, Fleet Street, London, E.C. 4.
2. CHAKRAVARTY, M. 1938. Studies on Myxosporidia from fresh-water fishes of Bengal. Proc. Indian Sci. Congr. p. 156 (Abst.)
3. HADDOW, A. and J. BLAKE. 1933. Neoplasms in fish: A report of six cases with summary of the literature. J. Path. Bact. 36: 41-47.
4. MAWDESLEY-THOMAS, L. E. 1972. Some tumours of fish. In *Diseases of Fish*. Edited by Lionel E. Mawdesley-Thomas. Symp. Zoo. Soc. Lond. 30: 247.
5. SCHLUMBERGER, H. G. and B. LUCKE. 1958. Tumours of fishes, amphibians and reptiles. Cancer Res. 8: 657-754.
6. TAKAHASHI, K. 1929. Studie uber die Fischtumoren. Zeits. Krebsforsch. 29: 1-73.
7. THOMAS, L. 1927. Sur un cas de ganglioneuroma abdominal chez la morue. Bull. Ass. Etude Cancer. 16: 282-286.
8. THOMAS, L. 1932. Sur un cas de stiboneuroepithelioblastome chez une durade. Bull. Ass. fr. Etude Cancer. 21: 385-396.

Received for publication 23 September 1974