

NODULAR SUPPURATIVE CUTANEOUS CELLULITIS IN A GALAPAGOS SEA LION

Author: RAND, CHARLES S.

Source: Journal of Wildlife Diseases, 11(3) : 325-329

Published By: Wildlife Disease Association

URL: <https://doi.org/10.7589/0090-3558-11.3.325>

BioOne Complete (complete.BioOne.org) is a full-text database of 200 subscribed and open-access titles in the biological, ecological, and environmental sciences published by nonprofit societies, associations, museums, institutions, and presses.

Your use of this PDF, the BioOne Complete website, and all posted and associated content indicates your acceptance of BioOne's Terms of Use, available at www.bioone.org/terms-of-use.

Usage of BioOne Complete content is strictly limited to personal, educational, and non - commercial use. Commercial inquiries or rights and permissions requests should be directed to the individual publisher as copyright holder.

BioOne sees sustainable scholarly publishing as an inherently collaborative enterprise connecting authors, nonprofit publishers, academic institutions, research libraries, and research funders in the common goal of maximizing access to critical research.

NODULAR SUPPURATIVE CUTANEOUS CELLULITIS IN A GALAPAGOS SEA LION

CHARLES S. RAND*

Abstract: Necropsy was performed on a sea lion (*Zalophus californianus wollebaeki*), sacrificed in an advanced (pre-terminal) stage of disease, possibly representative of the Galapagos epizootic of 1970-71. Predominant features of the disease were non-umbilicated multiple suppurative cutaneous nodules, debilitation and loss of motor power. Histopathological studies of the skin lesions disclosed suppurative cellulitis, with leucocytic invasion extending, in some instances, to all layers of the epidermis. *Pseudomonas aeruginosa* was recovered from cultures of blood and pus.

INTRODUCTION

In June of 1971 it was reported that an epizootic had been destroying hundreds or thousands of Galapagos sea lions (*Zalophus californianus wollebaeki*), during the previous 12 to 18 months. The disease, according to park rangers and other eye witnesses, was manifested by multiple skin nodules, progressive wasting and debilitation, apparent motor paralysis, with ultimate death of the animals.

On July 2, 1971 on Gardner-by-Hood Island, a young male sea lion (estimated weight, about 70 kg) was found lying on the lava rocks a few meters from the water's edge. It appeared listless and apathetic until closely approached, when it grunted, turned its head from side to side, but was unable to move its body. An accompanying park ranger identified the animal's condition and appearance as typical of other sea lions stricken by the epizootic.

MATERIALS AND METHODS

The animal was killed by a rifle shot to the left parietal region of the head. Blood spurting from the wound was collected in sterile tubes for subsequent

hematological study and culture. Necropsy was performed nearby. Pus from an incised fluctuating skin lesion was collected in sterile tubes for culture. Sections of this lesion and of various organs were placed in 10% neutral formalin for subsequent processing. Histological slides were stained with hematoxylin and eosin and studied by light microscopy.

RESULTS

Gross Necropsy Findings

The surface of the body had numerous (60 or more) raised nodular lesions, 1 to 5 cm in diameter (Fig. 1). These were predominantly on the dorsal and lateral aspects of the body and were dark brown in color. Incision of the smaller firm nodules showed them to be non-suppurative indurated masses in the subcutis. The larger lesions showed moderate to pronounced fluctuation and contained thick greenish-blue pus. A 10 x 15 cm ulcer on the left hind flipper had attracted numerous large muscoid flies. Similar flies were clustered over many of the lesions. None of the nodules showed any umbilication.

* Professor of Comparative Hematology, Department of Biology, Long Island University, Zeckendorf Campus, Brooklyn, New York 11201 U.S.A.

Small quantities of clear, straw-colored fluid were found in the pleural, pericardial and peritoneal cavities. Adhesions were absent. The presence of a non-involuted thymus confirmed the immaturity of the animal.

The weights of organs were as follows: lungs—670 g; heart—310 g; liver—1400 g; pancreas—55 g; each kidney—150 g. These organs, as also the thymus, testes, and mediastinal and mesenteric lymph nodes, all appeared grossly normal. The spleen weighed 240 g and was of moderately soft consistency. A wrinkled capsule indicated recent shrinkage of the organ. Weight comparison with spleens of equally heavy normal sea lions (data provided in personal communication by D. van Dyke) indicated splenomegaly to be present. Incision into the spleen caused the pulp to bulge slightly above the capsule.

The animal had apparently not eaten, possibly for days. The entire gastrointestinal tract was pale and contracted,

and when opened, completely free of ingesta. Nonetheless the animal did not appear malnourished. A panniculus adiposus measuring up to 5 cm in some regions was found.

The skin and subcutaneous tissues presented the major pathological changes. Multiple pyogenic lesions, varying in diameter from a few mm to about 5 cm were found. Some showed only induration, others were suppurative and still others were beginning to ulcerate.

On completion of the autopsy it took several hours to return to our ship. In this relatively short time the blood specimens had undergone total hemolysis and neither cell counts nor differential smears were possible. Aspects of this development are discussed further on in this paper.

Cultures

Cultures of blood and pus, carried out 3 weeks later (during which interval re-



FIGURE 1. Stricken Galapagos sea lion with multiple cutaneous nodules, some with clusters of muscid flies.

frigeration of the specimens was not possible) were reported as follows: blood—*Klebsiella* sp., *Enterobacter* sp., *Pseudomonas aeruginosa* and beta-hemolytic streptococci; pus — *Pseudomonas aeruginosa* only.

Microscopic Findings

Histologic study of sections of thymus, heart, liver, pancreas, lymph nodes, kidney and testis revealed no lesions. The lungs had small amounts of aspirated

material in the smaller bronchial branches. No evidence of pneumonia was noted. The spleen showed marked lymphoid depletion in the Malpighian corpuscles, some of which were reduced to two or three layers of lymphocytes around their sheathed arterioles. Megakaryocytosis was prominent.

Sections through skin nodules and abscess wall (Figs. 2, 3) showed normal or reduced thickness of the stratum spinosum. Neither hypertrophy nor hyperplasia of the epidermal epithelium was

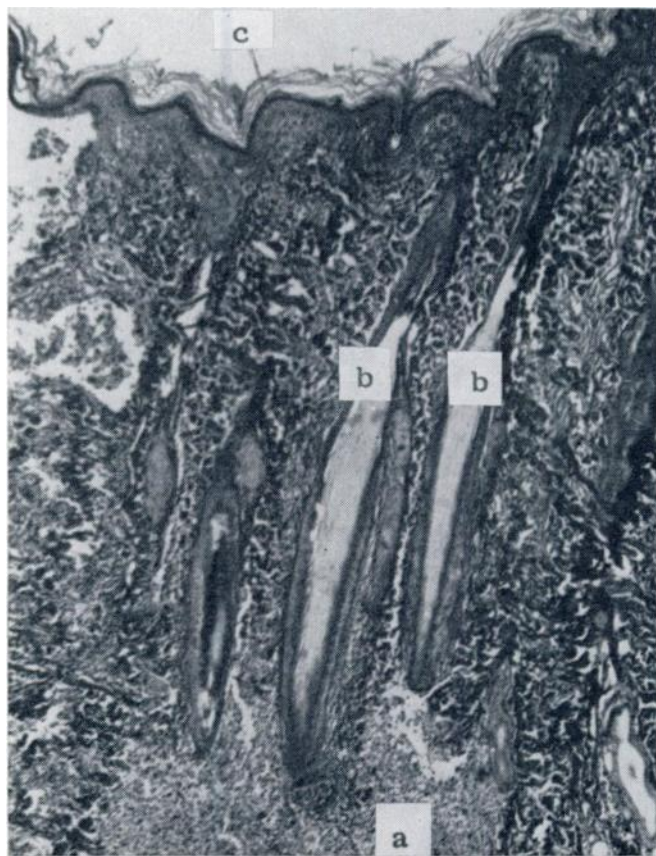

FIGURE 2. Section through smaller skin nodule with leucocytic invasion restricted to subcutis (a). Suppuration is advancing to hair follicles (b). The epidermal layers (c) are still intact. Hypertrophy, hyperplasia and cell inclusions are absent.

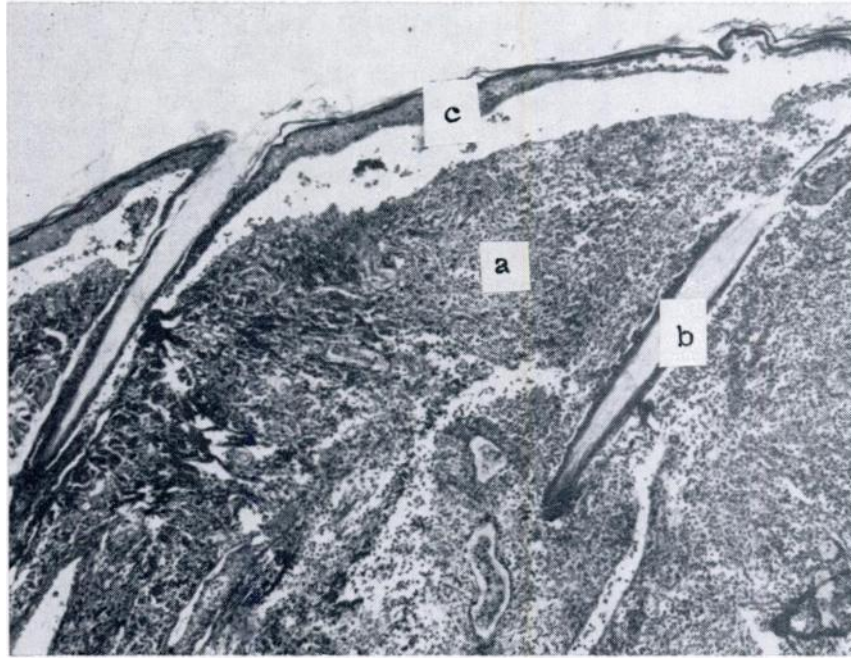


FIGURE 3. Section through suppurative skin nodule with leucocytic invasion of subcutis (a) encompassing a hair follicle and root (b) and extending to epidermis (c). The stratum corneum is separating from the necrotizing strata spinosa et germinativa.

found. Cells in this layer contained no intracytoplasmic eosinophilic or basophilic inclusions. Extensive cellulitis was observed in the subcutis, with leucocytic infiltration extending to the stratified squamous epithelium, occasionally separating the stratum corneum from the destroyed underlying stratum spinosum. Dense masses of leucocytes were also found infiltrating the subcutaneous fat and striped muscle, the fibers of which frequently showed extensive loss of striation and fragmentation. An occasional small blood vessel was obstructed by a thrombotic cluster of pus cells and necrotic cellular debris.

DISCUSSION

With regard to techniques employed and some attendant circumstances as they affected some results obtained, a few

comments are relevant. Blood from the gun-shot wound was collected under less than optimal conditions of sterility. Since beta-hemolytic streptococcus is a common intruder in many cultures, its presence in the blood culture may have been due to contamination from the skin. Admixture of tissue juices with the blood collected was unavoidable. The equatorial heat was great and refrigeration unavailable. Agitation of the specimens was inevitable during transport over jagged lava terrain. Any combination of these circumstances could have contributed to hemolysis of the blood specimens.

Superficially similar skin nodules, diagnosed as seal pox, have been described in South American sea lions,^{4,7} in harbor seals,^{4,6} and in captive^{3,4} and free-living California sea lions.⁵ Common to all of the above were histological findings of

hypertrophy and hyperplasia of cells of the stratum spinosum, with intracytoplasmic round or ovoid eosinophilic or basophilic inclusions. None of the aforementioned features—pathognomonic of seal pox—was seen in slides of the cutaneous lesions in the propositus of the necropsy reported here.

The sole finding of *P. aeruginosa* in the culture of nodular pus, and its occurrence also in the blood culture may represent fortuitous coincidence, but may also be interpreted as due to hematogenous invasion of the bloodstream by *Pseudomonas*.

Only because of the chronological coincidence of an outbreak of disease in the very closely related California species of sea lion, is reference made here to that epizootic during 1970-71. As in the case here reported, the California pinnipeds "showed a disinclination to use the rear limbs and back".^{1,2} No cutaneous lesions were reported there. The predominant lesion was severe interstitial nephritis with *Leptospira pomona* recovered from cultures of urine and renal homogenates. The circumstances of the necropsy reported here precluded investigation of the cerebro-spinal tract or detailed renal studies.

Acknowledgements

The author expresses appreciation to Dr. B. Gordon, pathologist of Hillcrest General Hospital for review of histological slides; to P. Higgins, graduate student, for assistance at necropsy; to Dr. A. W. Smith of the Naval Biomedical Research Laboratory for valuable comments and for providing data supplied by Dr. D. van Dyke; and to Dr. P. Kramer, former director of the Charles Darwin Research Station, for suggesting this investigation and authorizing the sacrifice of a terminally-diseased sea lion.

LITERATURE CITED

1. McILHATTAN, T. J., J. W. MARTIN, R. J. WAGNER and J. O. IVERSON. 1971. Isolation of *Leptospira pomona* from a naturally infected California sea lion, Sonoma County, California. *J. Wildl. Dis.* 7: 195-197.
2. VEDROS, N. A. A. W. SMITH, J. SCHONEWALD, G. MIGAKI and R. C. HUBBARD. 1971. Leptospirosis epizootic among California sea lions. *Science* 172: 1250-1251.
3. WILSON, T. M., N. F. CHEVILLE and L. KARSTAD. 1969. Seal pox. *Bull. Wildl. Dis. Ass.* 5: 412-418.
4. WILSON, T. M., N. F. CHEVILLE and A. D. BOOTHE. 1972. Sealpox questionnaire survey. *J. Wildl. Dis.* 8: 155-157.
5. WILSON, T. M., A. D. BOOTHE and N. F. CHEVILLE. 1972. Sealpox field survey. *J. Wildl. Dis.* 8: 158-160.
6. WILSON, T. M., R. W. DYKES and K. S. TSAI. 1972. Pox in young, captive harbor seals. *J. Amer. vet. med. Ass.* 161: 611-617.
7. WILSON, T. M. and I. POGLAYEN-NEUWALL. 1971. Pox in South American sea lions (*Otaria byronia*). *Canad. J. Comp. Med.* 35: 174-177.

Received for publication 16 October 1974