



## **AN EPORNIC OF DUCK PLAGUE ON A WISCONSIN GAME FARM**

Authors: JACOBSEN, GIFFORD S., PEARSON, JAMES E., and YUILL, THOMAS M.

Source: Journal of Wildlife Diseases, 12(1) : 20-26

Published By: Wildlife Disease Association

URL: <https://doi.org/10.7589/0090-3558-12.1.20>

---

BioOne Complete ([complete.BioOne.org](https://complete.BioOne.org)) is a full-text database of 200 subscribed and open-access titles in the biological, ecological, and environmental sciences published by nonprofit societies, associations, museums, institutions, and presses.

Your use of this PDF, the BioOne Complete website, and all posted and associated content indicates your acceptance of BioOne's Terms of Use, available at [www.bioone.org/terms-of-use](https://www.bioone.org/terms-of-use).

Usage of BioOne Complete content is strictly limited to personal, educational, and non - commercial use. Commercial inquiries or rights and permissions requests should be directed to the individual publisher as copyright holder.

---

BioOne sees sustainable scholarly publishing as an inherently collaborative enterprise connecting authors, nonprofit publishers, academic institutions, research libraries, and research funders in the common goal of maximizing access to critical research.

## AN EPORNITIC OF DUCK PLAGUE ON A WISCONSIN GAME FARM

GIFFORD S. JACOBSEN<sup>1</sup>, JAMES E. PEARSON<sup>2</sup> and THOMAS M. YUILL<sup>3</sup>

**Abstract:** In April, 1973, an acute disease with a high rate of mortality appeared in a flock of 233 ducks and geese at a private game farm. Most of the flock (220) were black ducks (*Anas rubripes*) and mortality was restricted to them. In May, the remaining live birds were placed in isolation but mortality continued in black ducks and occurred in other species. The overall rate of mortality for black ducks was 93% and the case fatality rate was 97%. No hemorrhaging from either the bill or vent was observed. The most commonly observed gross lesions were extensive fibrino-necrotic plaques covering the mucosal surface of the esophagus, posterior colon and cloaca. Petechial and ecchymotic hemorrhages on visceral organs, particularly the heart, were also common. Virus isolation was attempted from tissues of three black ducks. Duck plague virus was isolated from liver, kidney, spleen and intestine of each. Sixteen black ducks survived the outbreak. Seven of these birds had significant levels of neutralizing antibody to duck plague virus.

### INTRODUCTION

Recent epizootics of an acutely fatal disease in North American waterfowl have been attributed to duck plague (DP) (duck virus enteritis). This disease was first described in Europe.<sup>1</sup> An epornitic occurred in the domesticated duck industry of Long Island in 1967-68.<sup>2</sup> The disease then spread to wild ducks in the Long Island Sound area and subsequently to other locations along the Atlantic Coast.<sup>3</sup> No widespread mortality was reported at that time, and DP continued to be classified as an exotic disease by the U.S. Department of Agriculture. A focal epornitic occurred in San Francisco in a small lagoon in 1972.<sup>4</sup> The first major epornitic, with massive waterfowl mortality, occurred at Lake Andes, South Dakota, in January through March, 1973. An estimated 43,000 ducks and geese of a total population of 100,000 waterfowl

died in that two-month period.<sup>5</sup> The connection between these widely separated outbreaks, if any, is not clear.

A highly focal, species-specific epizootic of DP occurred on a game farm in Wisconsin in April and May, 1973. This communication reports that epornitic.

### FLOCK AND EPORNITIC HISTORY

The outbreak occurred on a large privately owned game farm specializing in waterfowl. The farm had seven major enclosures (Figure 1). The population by species in each enclosure is presented in Table 1. The affected flock, held in Pond 2, was comprised mainly of 220 black ducks (*Anas rubripes*). Thirty of the black ducks had come from the U.S. Fish and Wildlife Service Northern Prairie Waterfowl Research Center at Jamestown, N.D. two years previously

<sup>1</sup> Diagnostician APHIS, USDA at the Wisconsin Central Animal Health Laboratory, 6101 Mineral Point Rd., Madison, Wisconsin 53705, USA.

<sup>2</sup> Diagnostic Virology, Veterinary Services Diagnostic Laboratories, APHIS, USDA National Animal Health Laboratory, P.O. Box 70, Ames, Iowa 50010, USA.

<sup>3</sup> Department of Veterinary Science, University of Wisconsin, Madison, Wisconsin 53706, USA.

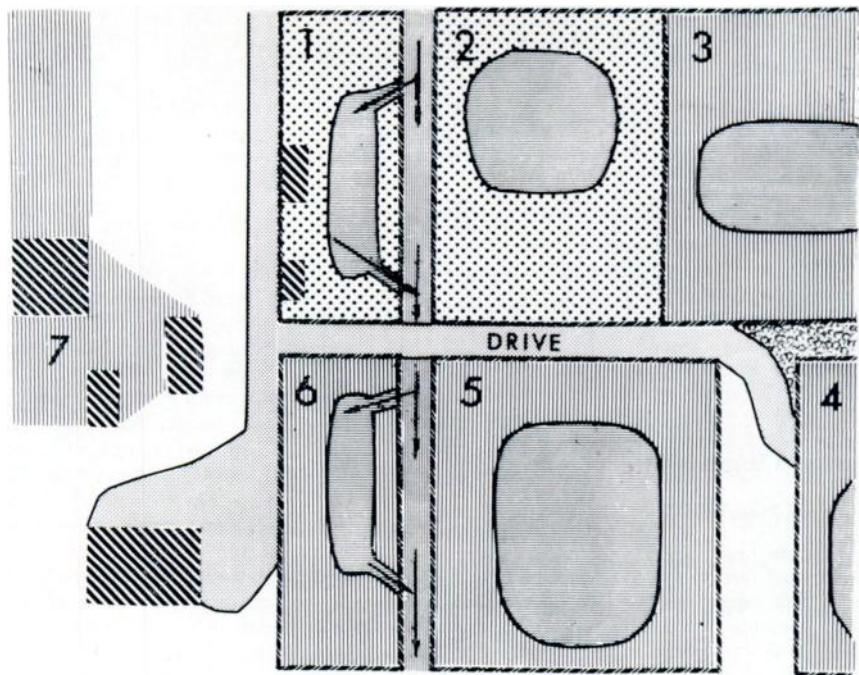


FIGURE 1. Diagram of the game farm. See Table 1 for explanation. Arrows indicate stream flow.

TABLE 1. Waterfowl present at the onset of the duck virus enteritis (duck plague) outbreak.

Area	Species	Number
Pond 1	Vacant	
Pond 2	Black ducks	220
	Various species including ring-necked, scaup, green-winged teal, cackling goose, blue goose	13
Pond 3	Various species including redhead, pintail, blue-winged teal, gadwall, American widgeon, shoveler	90
Pond 4	Canada goose	285
Pond 5	Wood duck	150
	Blue-winged teal	2
Pond 6	Various species including canvasback, ring-necked, dusky goose, mandarin	9
Area 7	Mallards	12,000

Scientific names, respectively: *Anas rubripes*, *Aythya collaris*, *Aythya affinis*, *Anas crecca*, *Branta canadensis minima*, *Chen caerulencens*, *Aythya americana*, *Anas acuta*, *Anas discors*, *Anas strepera*, *Mareca americana*, *Spatula clypeata*, *Branta canadensis*, *Aix sponsa*, *Anas discors*, *Aythya valisineria*, *Aythya collaris*, *Branta canadensis occidentalis*, *Aix galericulata*, and *Anas platyrhynchos*.

and 119 were progeny of these birds. Seventy-one additional black ducks had been obtained in the fall of 1972 at the Crab Orchard National Wildlife Refuge.

The owner first noted black duck mortality during the third week of April. The birds died suddenly without preceding conspicuous signs of illness. The flock was moved from pen 2 to pen 1. The mortality continued steadily into May. By the time the affected flock was removed from the premises on May 17, 102 of the 220 black ducks had died. DP deaths were essentially over by May 30, however, one death — apparently from DP — occurred as late as July 25.

#### MATERIALS AND METHODS

##### Necropsy Procedures

Routine necropsy procedures were performed on the dead ducks. Liver, heart and lung tissue was cultured aerobically in blood agar, Sabouraud's, and eosin and methylene blue (EMB) for isolation of bacteria. Intestinal tract scrapings were examined for coccidia. Liver, kidney, spleen and intestine tissue from the first three cases were frozen on dry ice and submitted to the Veterinary Services Diagnostic Laboratory, Ames, Iowa, for virus isolation.

##### Virus Isolation Procedures

A 20% suspension of the tissues was prepared with antibiotics and inoculated onto the chorio-allantoic membrane (CAM) of 9- to 14-day old embryonated pekin duck eggs and into primary pekin duck embryo fibroblast (DEF) cell cultures.<sup>6</sup> Two serial passages were made in duck eggs. The CAMs from dead embryos were suspended and inoculated into DEF cultures. Cultures developing viral cytopathogenic effect (CPE) were tested by fluorescent antibody (FA) for DP virus antigen. Specific duck anti-DP virus antisera was prepared in chickens hyperimmunized with the DP virus vaccine and conjugated with fluorescein isothiocyanate. Standard controls were used in all FA tests.

##### Serology

Antibody was quantified in the plaque reduction neutralization test. Vaccine DP virus and DEF cell cultures were used. Serum endpoints were calculated to determine the dilution producing 90% plaque reduction.

#### RESULTS

Species other than black ducks in the affected flock in adjoining pens did not die. On the 14th and 15th of May, four recently dead black ducks were submitted to the Wisconsin Animal Health Laboratory for diagnosis. An additional five ducks (3 hens and 2 drakes) were submitted to Dr. Louis Leibovitz at the Cornell University Duck Research Laboratory. At necropsy, lesions consistent with those reported for DP<sup>1,2</sup> were observed in both laboratories. The affected flock was moved into two rooms of the tight isolation unit of the Veterinary Science Department of the University of Wisconsin.

In the isolation units the birds continued to die through May. Mortality also occurred among species other than black ducks. All individuals of the other duck species died including five lesser scaup (*Aythya affinis*), two ringnecked ducks (*Aythya collaris*), one greenwinged teal (*Anas crecca*), and one blackbellied tree duck (*Dendrocygna autumnalis*). The geese, including two greater snow geese (*Chen caerulescens atlanticus*) and two cackling geese (*Branta canadensis minima*) survived and did not develop neutralizing antibody.

Of the original 220 black ducks, 102 died at the game farm and an additional 102 died in the isolation unit for an overall mortality rate of 93%. Seven ducks survived the infection and developed neutralizing antibody. Nine surviving ducks did not have neutralizing antibody. The case fatality rate among black ducks was 97%. Although other species became infected and died in the isolation unit, their numbers are too small to permit meaningful calculation of mortality rates.

Eleven black ducks which died at the farm and 44 black ducks which died in the isolation unit were necropsied. The most consistent lesions observed were fibrino-necrotic plaques on the mucosa of the esophagus, colon and cloaca (Figures 2 and 3) and ecchymoses and petechial hemorrhages on the heart (Figure 4). Shrunken and congested spleens, prolapsed penes, linear hemorrhages and necrosis at the esophageal-proventricular junction, and inflamed intestinal tracts were occasionally observed. No annular intestinal hemorrhages occurred. Histologically, focal necrosis of the liver with a mononuclear infiltrate surrounding large vessels and necrotic esophageal mucosa with mucus glands containing a few inflammatory cells were seen. No evidence of leukocytozoon infection was seen.<sup>4</sup> No pathogenic bacteria or fungi were isolated on the three types of media utilized.

Virus was isolated from liver, kidney, spleen and intestines of each of the three black ducks. The CAMs of inoculated eggs were thickened. CAM suspensions

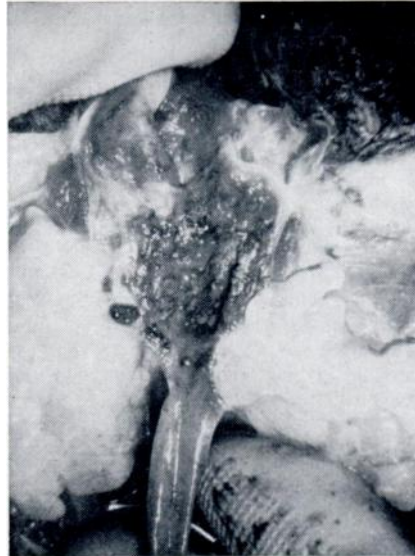

FIGURE 3. Duck virus enteritis (duck plague) in a black duck. Fibro-necrotic plaques in the cloaca.



FIGURE 2. Duck virus enteritis (duck plague) in a black duck. Fibro-necrotic plaques in the esophagus.

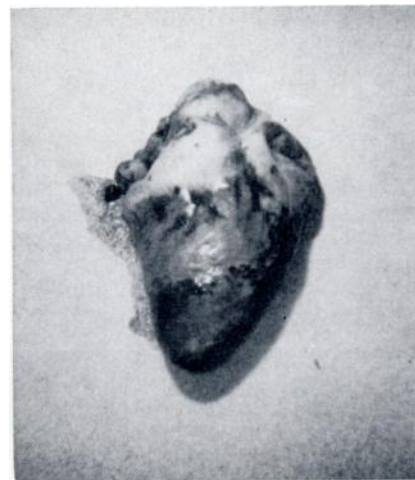

FIGURE 4. Duck virus enteritis (duck plague) in a black duck. Hemorrhages in the heart.

<sup>4</sup> Histologic studies by Dr. J. C. Hruska.

produced herpesvirus-like CPE in DEF cultures. DP virus antigen was detected in these cultures by means of FA staining. Coccidia were not observed in intestinal scrapings. Pathogenic bacteria were not isolated from tissues by the Wisconsin or the Cornell Laboratories.

To test the transmissibility of the disease, a pool of liver and spleen tissue was made from birds with characteristic lesions. Three one-day-old pekin ducklings were inoculated intramuscularly with a 10% suspension of the pooled tissue. Two of the three ducklings died six days post-inoculation with lesions compatible with DP.

To determine if virus transmission was occurring in the isolation unit, 10 adult pekin ducks were placed in the isolation unit with the remaining ducks on May

25. Two of the birds developed significant neutralizing antibody titers (1:16 and 1:4) by July 14 when all 10 were removed and necropsied. No gross lesions or signs of disease were observed.

Six black ducks had 1:64 titers when first bled on May 25, and maintained detectable but lower titers when tested on July 15 and December 5 (Table 2). One black duck developed antibody between May 25 and July 15. A seventh black duck lost its identifying band after the July 15 sampling. This bird also had neutralizing antibody on December 5. One duck showed a 1:64 titer on May 25 and died on June 25 with cloacal and esophageal lesions suggestive of DP. A swollen cirrhotic liver and free fibrin clots in the abdominal cavity suggested the presence of another disease condition occurring concurrently with DP.

TABLE 2. Duck virus enteritis neutralizing antibody titers in black ducks held in isolation following an epornitic.

Duck No.	25 May	15 July	5 Dec.
119	0	16 <sup>1</sup>	64
2021-9	64	128	16
1658-9	64	16	4
320	64	16	4
321	64	4	4
489	64	4	4

<sup>1</sup> Reciprocal of serum dilution producing 90% plaque reduction neutralization.

## DISCUSSION

DP appears to have been the etiological agent responsible for the mortality among these game farm ducks. Gross lesions characteristic of DP were observed by diagnosticians in two laboratories. A virus was isolated from each of three ducks which produced characteristic herpesvirus CPE in cell culture and was identified as DP virus by FA. The transmissibility of the agent was demonstrated by the death of two of three ducklings inoculated with tissues from dead

black ducks and by the development of DP neutralizing antibody in two sentinel adult pekin and one black duck during the time they were held in the isolation unit. Lesions compatible with DP were found in the two dead ducklings.

There are some sharp contrasts between this DP epornitic and the outbreak among free living waterfowl at Lake Andes, S.D. (M. Friend, personal communication.) The outbreak in Wisconsin was highly species specific in the field; only black ducks were affected. Mortality occurred among a variety of species at

Lake Andes. In the Wisconsin epornitic, no mortality of waterfowl in adjacent or downstream pens occurred. In South Dakota, DP mortality occurred not only in birds frequenting Owen's Bay, but dead birds were also found along drainage ditches, marsh areas, open fields and along the Missouri River 9.6 km from Lake Andes refuge. Because virologic and serologic testing of all the birds remaining on the game farm was not done, the possibility of subclinical infections in birds in the other pens can not be ruled out. Thirty of 90 black duck ducklings housed in a brooder shed adjacent to the affected pen (pen 1) were tested serologically. No DP antibodies were found.

A number of the lesions described as typical in birds dying of DP at Lake Andes (M. Friend, personal communication) were not observed among the black ducks dying in Wisconsin. Bloody discharge from the bill and vent and hemorrhagic intestinal annular bands did not occur in the Wisconsin ducks. The absence of annular bands in the black ducks possibly due to the diffuse distribution of lymphoid tissue in the gastrointestinal tract of this species (L. Leibovitz, personal communication). The fibrino-necrotic plaques of the esophagus and cloaca were the most prominent and consistent findings among the black ducks. These

lesions were not a consistent feature of the Lake Andes epizootic; they were observed in some of the birds dying late in the course of the outbreak (M. Friend, personal communication).

The origin of the epizootic is not clear. The game farm birds were held in large, outdoor pens. Free living waterfowl frequently visited these pens, especially in the spring, and could have carried the virus to the resident black ducks. The outbreak might also have originated from a resident carrier black duck, or one of the black ducks that had been captured from the wild at Crab Orchard, Illinois. Black ducks from the Atlantic Flyway occasionally visit the Crab Orchard Refuge. DP appears to be enzootic in limited focal areas along the Atlantic coast (L. N. Locke, personal communication). It is conceivable that one of the Crab Orchard birds was a DP convalescent carrier, perhaps from the Atlantic flyway. Seven birds had neutralizing antibody at the end of the epizootic, indicating that survival of DP virus infection occurred. Since DP is a herpesvirus, and this group generally produces long-term chronic infections, the carrier state is entirely possible. If the DP carrier state does exist, this disease could have a serious impact on North American waterfowl populations.

#### Acknowledgements

Mr. Richard Hunt, Wisconsin Department of Natural Resources, and Mr. Baxter Newton, Wisconsin Department of Agriculture, played important roles in early detection of the outbreak. The Microbiology Section, Central Animal Health Laboratory, Wisconsin State Department of Agriculture, conducted the routine tests for bacterial and parasitic agents and prepared tissue suspensions. Personnel of the Avian-Ovine Unit, Diagnostic Virology, Veterinary Services Laboratories, U.S. Department of Agriculture, Ames, Iowa assisted in virus isolation. Drs. L. Locke, M. Friend and L. Leibovitz reviewed the manuscript and offered helpful suggestions.

#### LITERATURE CITED

1. LEIBOVITZ, L. 1971. Duck plague. In: *Infectious and Parasitic Diseases of Wild Birds*, Davis, J. W., Anderson, R. C., Karstad, L. H. and Trainer, D. O., Eds. Iowa State Press, Ames, pp. 22-33.
2. ——— and J. HWANG. 1968. Duck plague on the American continent. *Avian Dis.* 12: 361-378.
3. ———. 1968. Progress report: duck plague surveillance of American anseriformes. *Bull. Wildl. Dis. Ass.* 4: 87-90.

4. SNYDER, S. B., J. G. FOX, L. H. CAMPBELL, K. F. TAMM and A. O. SOAVE. 1973. An epornitic of duck virus enteritis (duck plague) in California. *J. Am. vet. med. Ass.* 163: 647-652.
5. ERICKSON, G. A., S. J. PROCTOR, J. E. PEARSON and G. A. GUSTAFSON. 1974. Diagnosis of duck virus enteritis (duck plague). *Proc. 17th Annual Meeting of the Am. Ass. Vet. Lab. Diag.* In Press.
6. FRIEND, M. and G. L. PEARSON. 1973. Duck plague (Duck Virus Enteritis) in wild waterfowl. Bureau of Sport Fisheries and Wildlife U.S. Gov. Print. Office 2410-00372.

*Received for publication 19 March 1975*

---