

REOVIRUS-LIKE AGENT ASSOCIATED WITH NEONATAL DIARRHEA IN PRONGHORN ANTELOPE 1

Authors: REED, DAVID E., DALEY, CHARLES A., and SHAVE, HAZEL J.

Source: Journal of Wildlife Diseases, 12(4) : 488-491

Published By: Wildlife Disease Association

URL: <https://doi.org/10.7589/0090-3558-12.4.488>

BioOne Complete (complete.BioOne.org) is a full-text database of 200 subscribed and open-access titles in the biological, ecological, and environmental sciences published by nonprofit societies, associations, museums, institutions, and presses.

Your use of this PDF, the BioOne Complete website, and all posted and associated content indicates your acceptance of BioOne's Terms of Use, available at www.bioone.org/terms-of-use.

Usage of BioOne Complete content is strictly limited to personal, educational, and non - commercial use. Commercial inquiries or rights and permissions requests should be directed to the individual publisher as copyright holder.

BioOne sees sustainable scholarly publishing as an inherently collaborative enterprise connecting authors, nonprofit publishers, academic institutions, research libraries, and research funders in the common goal of maximizing access to critical research.

REOVIRUS-LIKE AGENT ASSOCIATED WITH NEONATAL DIARRHEA IN PRONGHORN ANTELOPE¹

DAVID E. REED, CHARLES A. DALEY and HAZEL J. SHAVE, Department of Veterinary Science, South Dakota State University, Brookings, South Dakota 57006, USA

Abstract: Reovirus-like particles were demonstrated by negative stain electron microscopic examination of the feces from antelope fawns with diarrhea. Fluorescent antibody tests on frozen sections of ileum from one dead antelope fawn and immunoelectron microscopy tests on feces from two live fawns provided evidence that the antelope agent was serologically related to the neonatal calf diarrhea reovirus-like agent.

INTRODUCTION

Viral agents morphologically resembling reoviruses have been found associated with neonatal diarrhea in calves in the United States,^{2,7} Great Britain,⁸ and Canada.⁵ An isolate of the agent designated as the neonatal calf diarrhea (NCD) virus was shown to cause diarrhea in neonatal gnotobiotic calves.⁴ Reovirus-like agents serologically identical to the NCD virus also have been demonstrated in enzootic diarrhea in infant mice and human infant diarrhea.³ The present paper reports demonstration of the NCD reovirus-like agent in neonatal pronghorn antelope (*Antilocapra americana*).

CASE HISTORY

In connection with a research project utilizing the pronghorn antelope, six 1 to 3 day-old fawns were captured on two cattle ranches in Butte county, South Dakota, and an additional tame fawn, several weeks old, was obtained from a rancher in Meade county. These seven fawns were kept together for 1 to 2 days before being shipped in separate crates to the South Dakota Cooperative Wildlife Research Unit facilities. They were

then released into a common pen and remained together for 5 days. Two days after arriving at the facility, one 5 to 6 day-old fawn (#102) died of apparent starvation. On the following day three 5 to 7 day-old fawns had clinical signs of diarrhea and on day 4 after arriving at Brookings one of these (#107) died. The remaining fawns were then moved to individual pens and no further mortalities occurred.

MATERIALS AND METHODS

Tissues (liver, spleen, kidney, lung, large and small intestine, and brain) from the two dead fawns were collected at necropsy. Tissues for microscopic examination were fixed in 10% neutral formalin and embedded in paraffin. Sections were cut 6 μ m thick and were stained with hematoxylin and eosin. Portions of intestine for examination by fluorescent antibody (FA) technique were frozen on sectioning blocks in a -70 C freezer. Frozen sections were cut 8 μ m thick on a refrigerated microtome, mounted on glass slides and fixed in acetone (-20 C). Slides were stained at 37 C for 20 min with fluorescein isothiocyanate-labelled rabbit antiserum against the NCD reovirus-like agent.²

¹ Approved for publication by the Director, Agriculture Experiment Station, South Dakota State University, as Journal Series No. 1382.

² Norden Laboratories, Lincoln, Nebraska, USA.

Slides were given two 5 min rinses with 0.01M phosphate buffered saline (pH 7.2), one 5 min rinses with distilled water, and mounted in buffered glycerol (pH 9). Specimens were examined with an ultra-violet illuminated microscope using appropriate filters.

Electron Microscopy

Contents of the ileum from the two dead fawns and fecal specimens from the five live fawns were suspended at approximately 20% W/V in Hanks basal salt solution^[3] and homogenized with a TenBroeck glass grinder.^[4] The homogenates were centrifuged at 1,100 x G for 15 min to clarify and the supernate was centrifuged at 27,000 x G for 20 min to pellet clumps of virus. The pellet from high speed centrifugation was resuspended in 0.1-0.5 ml distilled water. For negative stain,⁵ one drop of the slightly turbid suspension was mixed with 20 drops of water, two drops of 4% potassium phosphotungstate (pH 6.8) and one drop 0.1% bovine serum albumin. The mixture was sprayed with an atomizer^[5] onto a 200 mesh collodion backed, carbon coated grid and examined immediately with a Hitachi HU-12 electron microscope.

Immuno-Electron Microscopy

Serologic identification of the virus was by immuno-electron microscopy (IEM) performed on virus pelleted from the feces. Procedures as modified from those previously published^{1,6} were as follows: One drop of virus suspension was mixed with two drops of rabbit anti-reovirus antibody^[2] and the mixture allowed to incubate overnight at 4 C. After incubation the mixture was diluted to 3 ml with distilled water and centrifuged at 27,000 x G for 20 min. The pellet from this centrifugation was resuspended in two drops distilled water and a negative stain preparation made as described. Specimens were examined

with the electron microscope to determine if virions were agglutinated or coated with antibody.

RESULTS

Necropsy and Histopathology

Gross examination of fawn #107 revealed a moderate dehydration indicated by sunken eyes. Tail hair was pasted with feces suggesting recent diarrhea. The small intestine was flaccid and dilated, and contained a yellowish, watery fluid. The colon and rectum contained a small quantity of dry fecal material in the lumen. Microscopic examination of the jejunum revealed cellular debris in the lumen and detachment of epithelium from the villi. Bacteria morphologically resembling *Escherichia coli* were seen on the villus epithelium. The epithelial cells at the tips of villi tended to be cuboidal. Bacteriologic examination resulted in isolation of *E. coli* from lung, liver, kidney and intestine of the fawn.

Virology

Fecal samples from three diarrheic fawns examined by negative stain electron microscopy all contained a large number of reovirus-like particles. Reovirus-like particles were also observed in 2 of 3 fecal samples obtained from antelopes with normal feces. Based on the number of virions per electron microscope field, the concentration of virus in non-diarrheal feces was estimated to be 2 to 3 logs less than in diarrheal feces. FA examination of a frozen section of jejunum from the dead fawn (#107) revealed positive reovirus fluorescence in villus epithelial cells. No FA positive cells were observed in a serial section stained with coronavirus conjugate.^[2] Electron microscopic examination of the intestinal contents of fawn #107 revealed numerous reovirus-like particles (Fig. 1). Incubation of virus with antibody against the neonatal Calf Diarrhea

[3] Grand Island Biological Co., Grand Island, New York.

[4] Curtin Scientific Co., Houston, Texas.

[5] Nebulizer. Ted Pella Company, Tustin, California.

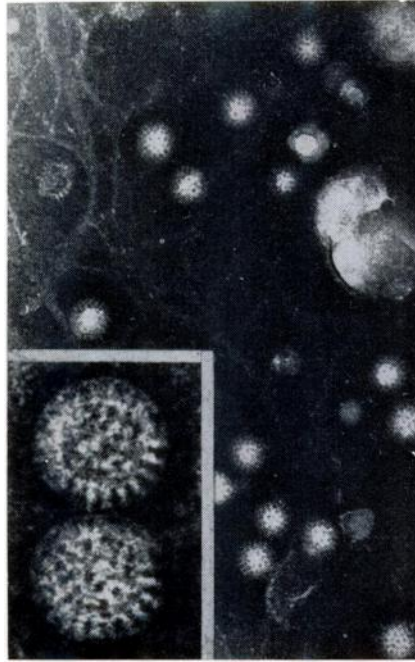


FIGURE 1. Electron micrograph of virus particles from antelope feces. Phosphotungstic acid negative stain. $\times 90,000$ (insert $\times 250,000$).

reovirus-like agent resulted in agglutination of virus and coating of the virions with antibody (Fig. 2). No viral agents were detected by FA or electron microscopic examinations of feces and intestinal contents from fawn #102.

DISCUSSION

The significance of finding the calf diarrhea reovirus-like agent in pronghorn antelope fawns is somewhat difficult to assess. The histopathologic changes seen in fawn #107 which died of enteric disease were not striking but were similar to those reported in calves with reoviral enteritis.⁴ This finding was strengthened by the positive FA results which demonstrated reoviral antigen in epithelial cells of the intestinal mucosa. Demonstration of a few virus particles in two antelope fawns with normal feces may indicate a

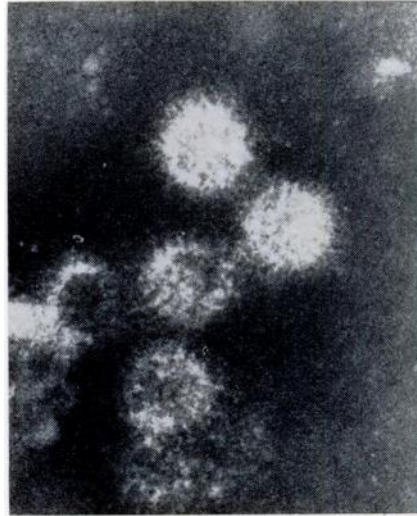


FIGURE 2. Immuno-electron microscopy. Antelope virus after incubation with rabbit antiserum against the neonatal calf diarrhea reovirus-like agent. Note agglutination of virus and coating of virions with antibody. Phosphotungstic acid negative stain. $\times 175,000$.

subclinical infection in those fawns. This finding is not surprising since all fawns were housed together at the start of the outbreak.

The epidemiologic significance of the presence of the NCD reovirus in captive fawns is open to speculation. Certainly in this case one might postulate that the older tame fawn carried the infection from cattle to the freshly captured neonatal fawns. Further work is planned to determine if free-living pronghorn antelope can carry the NCD reovirus.

Full evaluation of the pathogenicity of the NCD reovirus-like agent in antelope would require inoculation of gnotobiotic antelope fawns. No information is available on the presence of the reovirus-like agent in the field. Although a vaccine would be of little help in field outbreaks, the NCD reovirus vaccine^[2] may prove efficacious in preventing reoviral enteritis in pronghorn antelope fawns raised in captivity.

Acknowledgements

Sincere appreciation is expressed to David Hamm, Department of Wildlife and Fisheries Science, South Dakota State University for submission of specimens.

LITERATURE CITED

1. BAYER, M. E. and E. MANNWEILER. 1963. Antigen-antibody reactions of influenza virus as seen in the electron microscope. Arch. ges. Virusforsch. 5: 541-547.
2. FERNELIUS, A. L., A. E. RITCHIE, L. G. CLASSICK, J. O. NORMAN and C. A. MEBUS. 1972. Cell culture adaptation and propagation of a Reovirus-like agent of calf diarrhea from a field outbreak in Nebraska. Arch. ges. Virusforsch. 37: 114-130.
3. KAPIKIAN, A. A., H. W. KIM, B. G. WYATT, W. J. RODRIGUEZ, S. ROSS, W. L. CLINE, R. H. PARROT and R. M. CHANOCK. 1974. Reovirus-like agent in stools: association with infantile diarrhea and development of serologic tests. Science 185: 1049-1053.
4. MEBUS, C. A., E. L. STAIR, N. R. UNDERDAHL and M. J. TWIEHAUS. 1971. Pathology of neonatal calf diarrhea induced by a reo-like virus. Vet. Path. 8: 490-505.
5. MORIN, M., P. LAMOTHE, A. GAGNON and R. MALO. 1974. A case of viral neonatal calf diarrhea in a Quebec dairy herd. Can. J. comp. Med. 38: 236-242.
6. RITCHIE, A. E. and A. L. FERNELIUS. 1969. Characterization of bovine viral diarrhea viruses V. morphology of characteristic particles studied by electron microscopy. Arch. ges. Virusforsch. 28: 369-389.
7. WELSH, A. B. 1971. Purification, morphology and partial characterization of a Reoviruslike agent associated with neonatal calf diarrhea. Can. J. comp. Med. 35: 195-202.
8. WOODE, G. N., J. C. BRIDGER, G. HALL and M. J. DENNIS. 1974. The isolation of reoviruslike agent associated with diarrhea in colostrum-deprived calves in Great Britain. Res. vet. Sci. 16: 102-105.

Received for publication 28 August 1975
