

THE HELMINTH FAUNA OF CHILE: IV. NEMATODES OF THE GENERA *Anisakis* DUJARDIN, 1845 AND *Phocanema* MYERS, 1954 IN RELATION WITH GASTRIC ULCERS IN A SOUTH AMERICAN SEA LION, *Otaria byronia* 1

Authors: CATTAN, PEDRO E., BABERO, BERT B., and TORRES N., DANIEL

Source: *Journal of Wildlife Diseases*, 12(4) : 511-515

Published By: Wildlife Disease Association

URL: <https://doi.org/10.7589/0090-3558-12.4.511>

BioOne Complete (complete.BioOne.org) is a full-text database of 200 subscribed and open-access titles in the biological, ecological, and environmental sciences published by nonprofit societies, associations, museums, institutions, and presses.

Your use of this PDF, the BioOne Complete website, and all posted and associated content indicates your acceptance of BioOne's Terms of Use, available at www.bioone.org/terms-of-use.

Usage of BioOne Complete content is strictly limited to personal, educational, and non - commercial use. Commercial inquiries or rights and permissions requests should be directed to the individual publisher as copyright holder.

BioOne sees sustainable scholarly publishing as an inherently collaborative enterprise connecting authors, nonprofit publishers, academic institutions, research libraries, and research funders in the common goal of maximizing access to critical research.

THE HELMINTH FAUNA OF CHILE: IV. NEMATODES OF THE GENERA *Anisakis* DUJARDIN, 1845 AND *Phocanema* MYERS, 1954 IN RELATION WITH GASTRIC ULCERS IN A SOUTH AMERICAN SEA LION, *Otaria byronia*¹

PEDRO E. CATTAN,² BERT B. BABERO³ and DANIEL TORRES N.⁴

Abstract: A gastric ulcer was diagnosed in a South American Sea Lion, *Otaria byronia*, captured along the northern coast of Chile. Species of *Anisakis* and *Phocanema* were found to be associated with the lesions. A discussion of the histopathologic damage observed is presented, along with probable etiology of the ulcer.

INTRODUCTION

The South American Sea Lion, *Otaria byronia* (*O. flavescens*), is distributed along the entire coast of Chile. In the past century their numbers were practically decimated. Their population, however, is now increasing. Except for a few studies on population and distribution,¹ the only investigation underway in Chile is limited investigations on the trophodynamics of this mammal along the coast.¹⁰

Comparatively few studies on the helminth fauna of marine mammals have been undertaken in Chile. Alvarez and Pefaur² reported *Lecithodesmus spinous* Margolis and Pike, 1955 in the liver of a Chilean cetacean, *Balaenoptera borealis*, and Dailey and Brownell³ present a check-list of helminths and parasitic arthropods in numerous marine mammals, including *O. byronia*. Because of the limited studies on the helminths of the South African Sea Lion in Chile, the present investigation was initiated.

MATERIAL AND METHODS

Case report

In May, 1975, a female and two male South American Sea Lions were shot from a boat and dragged to the beach on Isla los lobos, an island near Los Vilos (Lat. 31°55' S., Long. 71°37' W.) north of Santiago, Coquimbo Province Region IV, Chile. The animals were captured in relation to a population control study and were of nearly adult size and maturity. No external lesions were observed. During necropsy, the stomachs and intestines were removed and preserved in 10% formalin. Upon examination of these organs, numerous nematodes were recovered from the stomachs. The larger worms were free in the lumen, but most of the smaller ones were embedded within the intestinal mucosa. A total number of 150 worms were recovered from the female and 500 and 923 from the males, respectively. Small stones, whose total aggregate weights were 400 and 475 grams, respectively, were collected from the stomach contents

¹ This study was supported in part by Grant No. 15151, Oficina Technica de Desarrollo Científico y Creación Artística. Universidad de Chile.

² Departamento de Ciencias Pecuarias Básicas. Facultad de Medicina Veterinaria, Universidad de Chile, Santiago, Chile.

³ Department of Biological Sciences, University of Nevada, Las Vegas, Nevada 89154, USA.

⁴ Ecología, Departamento de Ciencias Naturales y Exactas, Sed Santiago Sur. Universidad de Chile. Clasificado 1144, Santiago, Chile.

of both the female and the male that had the greater number of nematodes. Stones were absent in the other male animal; however, upon examination of the stomach mucosa a lesion of regular shape was observed which had the characteristics of a chronic ulcer. A portion of the lesion was excised for histopathological study, and the worms were removed to AFA (alcohol-formalin-acetic acid) solution for later identification.

RESULTS

Parasitology

Through the courtesy of Dr. Betty June Myers, Southwest Foundation for Research and Education, San Antonio, Texas, USA, the nematodes were identified—the larger were *Phocanema* sp. and the smaller were larval stages of *Anisakis* sp.

Pathology

Macroscopically, the ulcerous lesion was circular in shape, measuring 40 mm in diameter, with a central crater of 20 mm in diameter. The lesion was situated in the fundal wall of the stomach where it projected outwardly above the plicae of the mucosa and contained a distinct thickened border around a crater. The depth of the crater was between 6.0-10.0 mm. Within the crater was a caseous purulent material, along with some necrotic tissue. Numerous specimens of *Anisakis* sp. also were embedded within the crater of the lesion, as well as within scattered portions throughout the stomach. The mucosa, except near the cardiac zone, contained numerous diffused petechiae.

Histopathology

Histopathology diagnoses of lesions were graciously made by Dr. Paul Hebel, Departamento de Salud y Higiene Animal, Facultad de Medicina Veterinaria, Universidad de Chile. Microscopically, the gastric ulcer involved the mucosal and submucosal layers but did not penetrate the muscularis propria. From the surface of the lesion to its depth the

entire epithelium was lost, being replaced by a necrotic material containing epithelial cells, mucus and fibrin. Necrosis of the mucosa, proliferation of blood vessels, histocytic and lymphocytic infiltration, and a vast amount of disorganized cellular and fibrous bands were observed below this tissue. Proliferating fibroblasts were adjacent to this layer. Also observed were histiocytes, angioblasts, connective tissue cells and collagenous fibers.

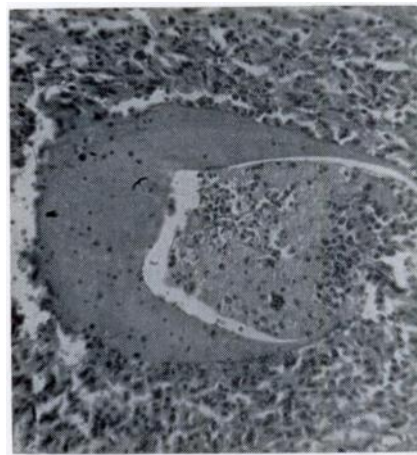


FIGURE 1. Hyaline mold associated with cellular response and necrosis.

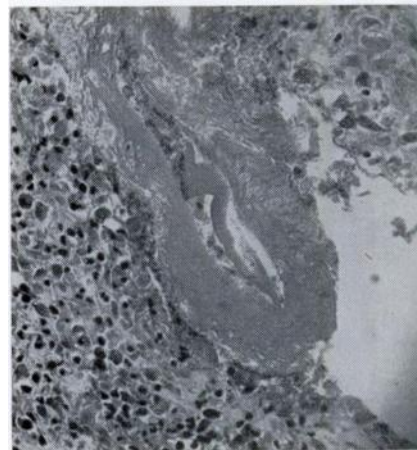


FIGURE 2. Fibrillar eosinophilic mantle with hyalinization.

No gland cells appeared to be present in the lesion, although some sections showed polyhedral cells which somewhat resembled the secretory cells of the epithelium. Observed also were hyalinized areas surrounded by foreign body giant cells, this probably representing a reaction to remnants of the worm.

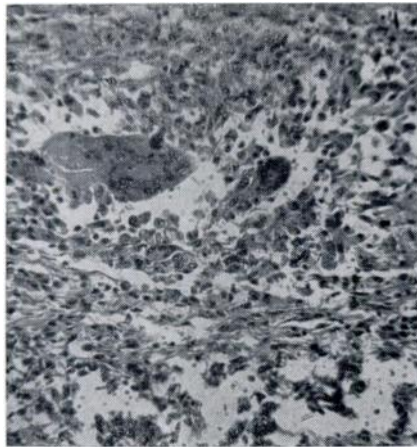


FIGURE 3. Areas of necrosis showing some hyalinization and prominent foreign body giant cells.

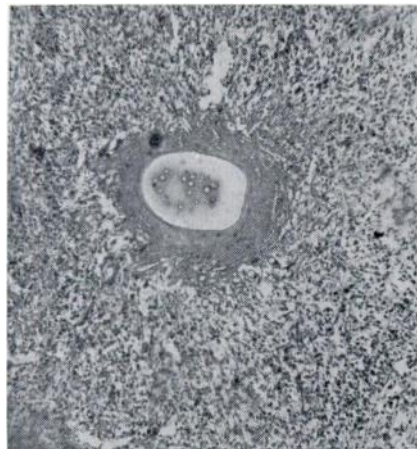


FIGURE 4. Portion of the mucosa showing hyalinized area surrounding point where head of nematode was vacated.

Sections of nematodes were present in the crater of the lesion and one area showed the head of a nematode embedded within necrotic epithelial tissue (Figure 5). Hyaline molds, which represented tracts where heads of nematodes disappeared, were present in mucosal and submucosal layers (Figures 1-4). These hyaline molds were frequently accompanied by masses of bacteria, and large giant

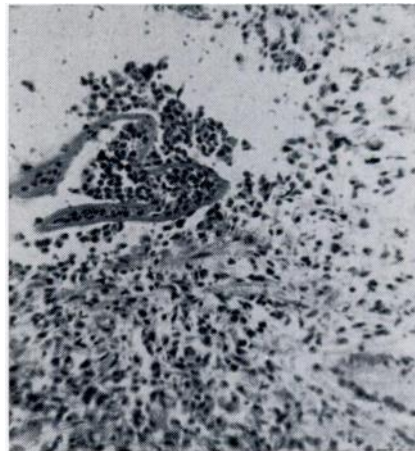


FIGURE 5. Cuticula of worm surrounded by heavy leucocytic infiltration.

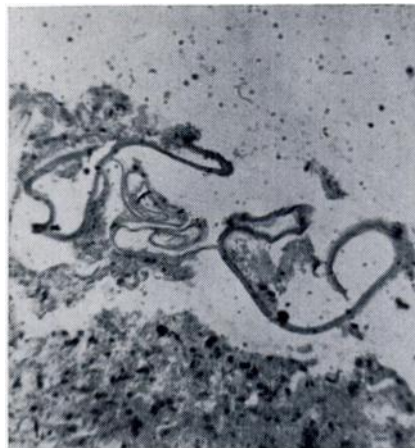

FIGURE 6. Shows the cuticula of worms, along with some necrosis of tissue.

cells containing foreign bodies were present along the periphery (Figure 3). Liu and Edward⁴ also observed and discussed similar hyaline molds in gastric ulcers associated with *Contracaecum* infections of the Stellar Sea Lion. In focal areas of the mucosa portions of the cuticula surrounded by heavy leucocytic infiltration were observed (Figure 6).

DISCUSSION

The exact etiology of the ulcer was not clearly established. The presence of nematodes, especially *Contracaecum osculatatum* Rudolphi, 1902, frequently has been reported in relation to gastric ulcers in the California Sea Lion, *Zalophus californianus*^{7,8,9,12} and the Stellar Sea Lion, *Eumetopias jubata*.⁶ Grines¹² cites 29 ulcerous stomachs in 56 California Sea Lions that died at the San Diego zoo between 1965-1972. Twenty-one of the 29 animals contained nematodes. In the Harp Seal, *Pagophilus groenlandicus*, a *Contracaecum* sp. was observed associated with gastric lesions accompanied by gastritis, edema, hemorrhage and necrosis.¹¹ Nematodes of the genus, *Anisakis*, associated with ulcerous processes in marine mammals have been reported by other investigators.^{7,12,14} Ulcers in the proventriculus of the Fulmar, *Fulmarus*

glacialis, caused by a cluster of larval *Anisakis* sp. has been reported.¹³

We suggest that the gastric ulcers in this South American Sea Lion were predisposed by larval nematodes penetrating the mucosa. Once embedded the mechanical and destructive action by the worms triggers an intense gastritis followed by an ulcer. Such ulceration would be complicated by an accumulation of excretory debris by the parasites, as well as by the invasion of bacteria into the depths of the lesions. The migratory activity of the worms further enhance bacterial invasion.

The significance of the presence or absence of stones in the stomach is not known, but the possibility exists that they could be another etiological factor in bringing about the ulcerous condition. Several hypotheses have been put forth to explain the presence of stones,⁹ one of which is that they serve to expel the parasites. It is interesting to note that lesions were found only in the animal without stones. Schroeder and Wegeforth¹⁴ theorized that the ulcers are brought about by abrasions from rough stones which are swallowed by sea lions to aid trituration. They also state that the ulcers are the result of gastric auto-digestion encouraged by the destroyed or abraded surfaces. Obviously, further investigation in this regard is warranted.

Acknowledgments

The writers extend their thanks to Mr. Patricio Osorio, Captain of Police and his riflemen in the locality of Los Vilos for their assistance in the capture of sea lions.

LITERATURE CITED

1. AGUAYO, A. and R. MATURANA. 1973. Presencia del lobo marino comun (*Otaria flavescens*) en el litoral chileno. I. Arica (18°20' S) a Punta Maiquillahue (39°27' S). Biol. Pesq. Chile. 6: 45-75.
2. ALVAREZ, V. and J. PEFAUR. 1970. Parasitismo hepatica por trematodos en "Rorcual de Rudolphis" (Cetacea) capturados en Chile. Bol. Chile. Parasit. 25: 1-5.
3. DAILEY, M. D. and R. L. BROWNELL, JR. 1972. A checklist of marine mammal parasites. In: *Mammals of the Sea (Biology and Medicine)*. 1st ed. Charles C. Thomas, Springfield.
4. LIU, S. and A. G. EDWARD. 1971. Gastric ulcers associated with *Contracaecum* sp. (Nematoda: Ascaroidea) in a stellar sea lion and a white pelican. J. Wildl. Manage. 7: 266-271.
5. JOHNSTON, D. G. and S. A. RIDGWAY. 1969. Parasitism in some marine mammals. J. Am. vet. med. Ass. 155: 1064-1072.

6. KING, J. E. 1964. *Seals of the world*. Trustees of the British Museum Natural History. London.
7. MIGAKI, G., D. VAN DYKE and R. C. HUBBARD. 1971. Some histopathological lesions caused by helminths in marine mammals. *J. Wildl. Dis.* 7: 281-289.
8. SWEENEY, J. C. 1974. Common diseases of Pinnipeds. *J. Am. vet. med. Ass.* 165: 805-810.
9. ——— and W. G. GILMARTIN. 1974. Survey of diseases in free-living California Sea Lions. *J. Wildl. Dis.* 10: 370-376.
10. TORRES, N. D. 1974. Relaciones troficas del lobo marino comun, *Otaria flavescens*, en el litoral central Proyecto N°1515 Of. Tech. Des. Cientif. & Creac. Artist. Univ. de Chile. Santiago.
11. WILSON, T. M. and P. H. STOCKDALE. 1970. The harp seal, *Pagophilus groenlandicus* (Erxleben, 1777). XI. *Contracaecum* spp. infestation in a harp seal. *J. Wildl. Dis.* 6: 152-154.
12. GRINER, L. A. 1974. Some diseases of zoo animals. In: *Advances in veterinary and comparative medicine*. Ed. by C. A. Brandley and C. E. Cornelius, Acad. Press, N.Y.
13. RILEY, J. 1972. The pathology of *Anisakis* nematode infections of the Fulmar *Fulmarus glacialis*. *Ibis.* 114: 102-104.
14. SCHROEDER, C. R. and H. M. WEGAFORTH. 1935. The occurrence of gastric ulcers in sea mammals of the California coast—their etiology and pathology. *J. Am. vet. med. Ass.* 87: 33-342.

Received for publication 13 February 1976
