

AN OUTBREAK OF MYXOBACTERIAL DISEASE IN COHO SALMON (*Oncorhynchus kisutch*) REARED IN A MAINE ESTUARY

Author: SAWYER, EVELYN S.

Source: Journal of Wildlife Diseases, 12(4) : 575-578

Published By: Wildlife Disease Association

URL: <https://doi.org/10.7589/0090-3558-12.4.575>

BioOne Complete (complete.BioOne.org) is a full-text database of 200 subscribed and open-access titles in the biological, ecological, and environmental sciences published by nonprofit societies, associations, museums, institutions, and presses.

Your use of this PDF, the BioOne Complete website, and all posted and associated content indicates your acceptance of BioOne's Terms of Use, available at www.bioone.org/terms-of-use.

Usage of BioOne Complete content is strictly limited to personal, educational, and non - commercial use. Commercial inquiries or rights and permissions requests should be directed to the individual publisher as copyright holder.

BioOne sees sustainable scholarly publishing as an inherently collaborative enterprise connecting authors, nonprofit publishers, academic institutions, research libraries, and research funders in the common goal of maximizing access to critical research.

AN OUTBREAK OF MYXOBACTERIAL DISEASE IN COHO SALMON (*Oncorhynchus kisutch*) REARED IN A MAINE ESTUARY

EVELYN S. SAWYER, Center for Research, University of Maine at Portland-Gorham,
246 Deering Avenue, Portland, Maine 04102, USA

Abstract: An epizootic of a myxobacterial infection in coho salmon (*Oncorhynchus kisutch*) was responsible for the death of 50,000 fish, 30% of the population. Cartilage in the nose, mouth and lower jaw was eroded, and yellow sheets of bacterial growth were observed in the mouth, pharynx and pneumatic duct. The severity of the disease increased with increasing water temperature. Pathogenicity trials were inconclusive; only two of 18 experimentally infected fish succumbed to the disease. However, the lesions, and the absence of other known pathogens suggests the myxobacterium was responsible.

INTRODUCTION

Myxobacterial disease in freshwater fish is widespread and occurs in many species.¹ The bacteria involved are long, thin, gliding, gram-negative rods *Chondrococcus* (now *Flexibacter*) *columnaris* and *Cytophaga psychrophila*, the etiological agents of columnaris, and cold-water disease. Other unclassified myxobacteria are associated with fin rot, tail rot and gill disease.

The seawater myxobacteria are less well known. Borg² described an undetermined genus of myxobacterium from diseased pink salmon (*Oncorhynchus gorbuscha*) held in seawater. Wood³ reported *Sporocytophaga* from Washington State hatcheries having a seawater supply, and a similar but distinct organism was isolated from an epizootic in seawater-reared rainbow trout (*Salmo gairdneri*) in Scotland.² In Pacific commercial salmon pen-culture, marine myxobacteria are considered minor pathogens, and have not been associated with significant mortality (A. J. Novotny, personal communication). This report describes an epizootic at a similar commercial seawater salmon culture operation in Maine where circumstantial evidence indicates a species of myxobacteria as the causative agent.

MATERIALS AND METHODS

Maine Salmon Farms is a commercial salmon producer located on the Sheepscot River in Wiscasset, Maine. Coho salmon (*Oncorhynchus kisutch*) eggs are imported from Washington and Oregon and reared in freshwater pools until early June. They are then moved to net pens in the estuary and held at a maximum density of 16 kg/m³ for growth to market size (225 g). Diet consists of one-half dry pellets and one-half a frozen mixture of ground shrimp and alewives.

On 7 July 1975, Maine Salmon Farms transferred 150,000 coho smolts (avg. wt. 7.5 g) from freshwater rearing pools to seawater net pens. Salinity was 26 ppt and water temperature 14 C. Two weeks later, as water temperature increased to 17 C, mortalities climbed from 3 fish/1000 fish/week to 20 fish/1000 fish/week (Fig. 1). Affected fish had extensive loss of scales; fecal casts; frayed, hemorrhagic fins; a white haze over the entire head; and severe erosion of cartilage in the nose, mouth and lower jaw. Large numbers of fish were vertical and motionless in the water column. Yellow sheets of bacterial growth were observed in the base of the mouth and pharynx, and, occasionally, filling the

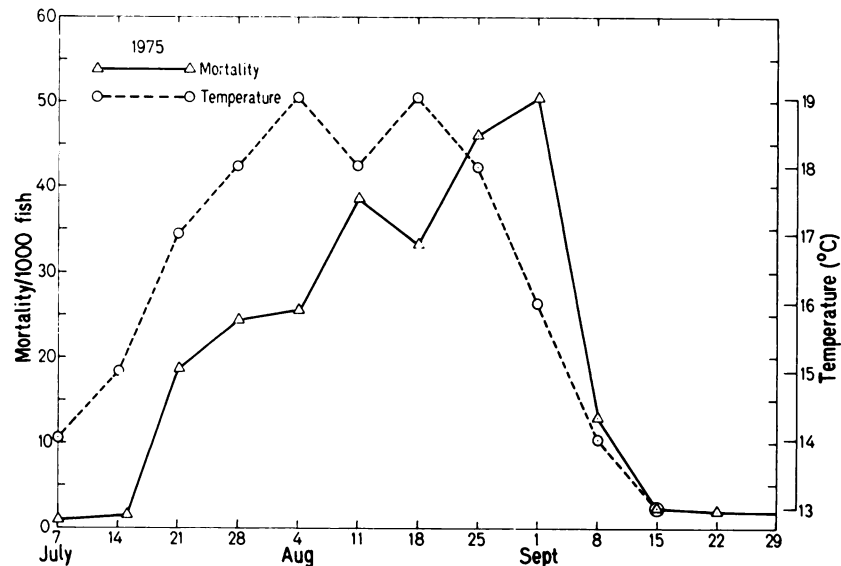


FIGURE 1. Weekly mortality and maximum water temperature during an outbreak of myxobacterial disease in seawater reared coho salmon.

pneumatic duct. Death occurred approximately one week after signs appeared, and probably was caused by osmotic stress resulting from the extensive loss of scales and tissue damage in the nose and mouth.

Therapeutic levels of Furox, Tylosin, Terramycin, and Sulfamerazine introduced into the feed were ineffective. Copper sulfate dips (1:2000 for 2 min) as recommended by Anderson and Conroy² were attempted on affected fish, but by the time fish showed signs, the disease was too far advanced for successful external treatment. Prophylactic dips or baths for the several hundred thousand fish in the net pens were impractical, and handling the fish at high water temperatures seemed unwise; therefore, the company could only wait out the problem.

Mortalities continued to increase throughout August, reaching 50 fish/1000 fish/week, and then dropped sharply as water temperatures fell below 15°C in September (Fig. 1). The total loss was approximately 50,000 fish (30%).

Tissue samples from mouth, jaw, kidney and liver of 38 moribund fish were collected during the outbreak. These were examined microscopically, and cultures were attempted on Tryptic Soy Agar TSA with 1.5% NaCl (Difco Inc.) and Ordal's medium with 50% seawater, and incubated at 20°C. The predominant organism in all cultures appeared to be the same on the basis of colony and cell morphology. Of 31 viable isolates obtained, six were designated 553-A, B, C etc., and maintained for further study.

Three methods were used to test pathogenicity. Organisms from a 72 hr culture were injected into the dorsal sinus of juvenile coho, scarified into mouth or flank tissue, or added to the aquarium water. Kidney tissue from fish that died was cultured on TSA with 1.5% NaCl and Ordal's medium with 50% seawater for reisolation of the organism.

Morphological and biochemical characteristics of all 553 isolates were determined using the methods of Hendrie *et al.*⁷ and Bullock.⁸ Sensitivity disks (Difco

Inc.) and the pteridine compound 0/129[□] were used to test drug sensitivity. All media was prepared with 1.5% NaCl or 50% seawater.

RESULTS

Scrapings of lesions in the jaw and mouth, including deep layers of cartilage, showed dense masses of myxobacteria. The organism also was abundant in scrapings from fins and from the skin, especially the head. Gills appeared normal grossly and microscopically. An occasional myxobacterium was seen in wet mounts of kidney.

There was no growth from samples of liver and kidney streaked on Ordal's medium or on TSA. Of the 38 mouth and jaw samples streaked on Ordal's medium, 31 produced yellow, spreading colonies that adhered firmly to the medium and formed macroscopic strings of bacteria. Of these 31, the six isolates maintained reacted similarly to all tests.

The organism was a gram-negative, gliding rod measuring 0.5 μm x 4-10 μm , and was cytochrome oxidase and catalase positive. It did not utilize agar, cellulose or chitin. Gelatin was liquified and nitrate reduced; glucose was not oxidized or fermented. There was no anaerobic growth, and no growth on Ordal's medium prepared without seawater or less than 1.0% NaCl. No fruiting bodies or microcysts were produced. The organism was sensitive to furozolidone, and resistant to tetracycline, streptomycin, novobiocin and the pteridine compound 0/129. Slide agglutination tests with *F. columnaris* antiserum supplied by the Eastern Fish Disease Laboratory in Lee-town, West Virginia were negative for all isolates. Dr. G. L. Bullock (personal communication) of that laboratory reported that one of these isolates sent to him failed to agglutinate with antiserum prepared against a marine myxobacterium causing eroded mouth in rainbow trout.⁹

Results of the pathogenicity tests were inconclusive. Death occurred in two of the 18 injected fish, and pure cultures of the organism were reisolated from the kidney. However, these reisolates did not kill fish upon reinjection. No mortalities occurred in two weeks among fish scarified with the bacterium, or those exposed to the organism in the water.

DISCUSSION

The epizootic closely resembled a columnaris outbreak that had occurred a month earlier in the company's freshwater facilities. Like columnaris, the seawater disease produced severe erosion of the nose, mouth and jaw that became more severe with increasing water temperatures. However, failure of the bacterium to grow without seawater or NaCl, or to agglutinate with *F. columnaris* antiserum indicates that it was not a "holdover" from a freshwater infection.

Biochemically, the organism was similar to pathogenic estuarine bacteria described by Bullock.⁹ According to Buchanan and Gibbons,⁴ a long, thin, gram-negative rod that shows gliding movement and does not attack agar, chitin and cellulose, or produce fruiting bodies or microcysts, is classified as *Flexibacter*.

The inconclusive pathogenicity tests are not surprising. Only two myxobacteria, *F. columnaris*⁸ and *C. psychrophila*³ have been transmitted from cultures. Bullock⁹ found it necessary to first stress the test fish, and then expose them to live infected fish to transmit myxobacterial gill disease. Probably the failure to prove pathogenicity with the Maine Salmon Farms' organism was related to the testing conditions. Thus, evidence for pathogenicity is, as yet, circumstantial. However, the characteristic signs of myxobacterial infection, the consistent presence of large numbers of myxobacteria in mouth and jaw lesions, and the absence of other bacteria from internal organs, point to this organism as the cause of the mortality.

[□] Gallard-Schlesinger Chemical Mfgs., Carle Place, Long Island, New York.

The role of stress in myxobacterial disease is well documented,^{8,9} yet commercial salmon growers, for economic reasons, frequently expose their stock to some degree of stress. They must transfer fish to seawater at as small a size as possible, hold them at high density, and risk abnormally high summer water temperatures. Osmotic and temperature stress almost certainly contributed to the high mortality at Maine Salmon Farms. This outbreak indicates that myxobacterial disease, like vibriosis, can be a major limiting factor to finfish mariculture.

Acknowledgements

I wish to thank Dr. P. K. Holmes, Biology Department, University of Maine, Portland-Gorham, and Dr. R. G. Strout, Animal Science Department, University of New Hampshire, for providing laboratory facilities, and for their advice, and assistance. I also thank Dr. G. L. Bullock of the Eastern Fish Disease Laboratory USFWS for supplying antisera, and Dr. R. E. Wolke, Agricultural Experiment Station, University of Rhode Island for his constructive criticism of the manuscript. This work was partially supported by Sea Grant, Project Numbr 04-3-158-38.

LITERATURE CITED

1. ANACKER, R. L. and E. J. ORDAL. 1955. Studies on the myxobacterium *Chondrococcus columnaris*. I. Serological typing. *J. Bacteriol.* 78: 25-32.
2. ANDERSON, J. I. W. and D. A. CONROY. 1969. The pathogenic myxobacteria with special reference to fish disease. *J. Appl. Bacteriol.* 32: 30-39.
3. BORG, A. 1960. Studies on myxobacteria associated with diseases in salmonid fishes. *Wildl. Dis. (microfiche)* 8: 1-85 (2 microcards).
4. BUCHANAN, R. E. and N. E. GIBBONS. 1974. *Bergey's manual of determinative bacteriology*. 8th ed. Williams and Wilkins Co., Baltimore, Maryland.
5. BULLOCK, G. L., D. A. CONROY and S. F. SNIESZKO. 1971. Bacterial diseases of fish. Book 2A. Pages 1-151. In: *Diseases of Fishes*, S. F. Snieszko and H. R. Axelrod, eds. T. F. H. Publications Inc., Neptune City, New Jersey.
6. ————. 1972. Studies on selected myxobacteria pathogenic to fishes, and on bacterial gill disease in hatchery reared salmonids. U.S. Bur. Sport Fish. and Wildl. Tech. Paper 60. 30 p.
7. HENDRIE, M. S., T. G. MITCHELL and J. M. SHEWAN. 1968. The identification of yellow-pigmented rods. In: *Identification methods for microbiologists*, B. M. Gibbs and D. A. Shapeton, eds. Part B. Academic Press, London.
8. HOLT, R. A., J. E. SANDERS, J. L. ZINN, J. L. FRYER and K. S. PILCHER. 1975. Relation of water temperature to *Flexibacter columnaris* infection in steelhead trout (*Salmo gairdneri*), Coho (*Oncorhynchus kisutch*) and Chinook (*O. tshawytscha*) salmon. *J. Fish Res. Board Can.*, 32: 1553-1559.
9. WOOD, J. W. 1968. Diseases of Pacific salmon. Their prevention and treatment. Dept. Fish., Hatchery Div., State of Washington. C-9.1.

Received for publication 12 April 1976