

## **STUDIES ON ENDOPARASITES OF THE MOURNING DOVE (*Zenaida macroura*) IN THE SOUTHEAST UNITED STATES 1**

Authors: BARROWS, PAUL L., and HAYES, FRANK A.

Source: Journal of Wildlife Diseases, 13(1) : 24-28

Published By: Wildlife Disease Association

URL: <https://doi.org/10.7589/0090-3558-13.1.24>

---

BioOne Complete ([complete.BioOne.org](https://complete.BioOne.org)) is a full-text database of 200 subscribed and open-access titles in the biological, ecological, and environmental sciences published by nonprofit societies, associations, museums, institutions, and presses.

Your use of this PDF, the BioOne Complete website, and all posted and associated content indicates your acceptance of BioOne's Terms of Use, available at [www.bioone.org/terms-of-use](https://www.bioone.org/terms-of-use).

Usage of BioOne Complete content is strictly limited to personal, educational, and non - commercial use. Commercial inquiries or rights and permissions requests should be directed to the individual publisher as copyright holder.

---

BioOne sees sustainable scholarly publishing as an inherently collaborative enterprise connecting authors, nonprofit publishers, academic institutions, research libraries, and research funders in the common goal of maximizing access to critical research.

## STUDIES ON ENDOPARASITES OF THE MOURNING DOVE (*Zenaida macroura*) IN THE SOUTHEAST UNITED STATES<sup>1</sup>

PAUL L. BARROWS<sup>2</sup> and FRANK A. HAYES, Southeastern Cooperative Wildlife Disease Study, Department of Parasitology, College of Veterinary Medicine, University of Georgia, Athens, Georgia 30602, USA

**Abstract:** From September, 1973, through November, 1974, 255 mourning doves (*Zenaida macroura*) were collected in the southeastern United States and examined for endoparasites. Thirteen species of endoparasites were found and included six species of protozoans, one trematode, two cestodes, and four nematodes. New host records included *Sarcocystis* sp., *Echinostoma revolutum*, *Hymenolepis* sp., *Aproc-tella stoddardi*, *Ascaridia columbae*, and *Dispharynx nasuta*.

### INTRODUCTION

Few detailed investigations on the endoparasitic fauna of mourning doves (*Zenaida macroura*) have been conducted. Although studies dealing with protozoan parasites of mourning doves are relatively numerous, only isolated accounts of helminth parasitism in these birds have been published. Only one previous study involved a search for both protozoan and helminth parasites.<sup>9</sup>

This report represents an extensive study on the distribution, intensity of infection, and pathologic effects of endoparasites among mourning doves collected in the southeastern United States.

### MATERIALS AND METHODS

A total of 255 birds was obtained from 25 locations in 12 southeastern states between September, 1973, and November, 1974 (Fig. 1). Ten doves were collected from each site except Clarke County, Alabama (8), Suwannee County, Florida (8), Morgan County, Georgia

(20), and Gibson County, Tennessee (9). Methods of collection included both shooting and live-trapping. Doves from 15 collections were refrigerated and processed within 18 hr in field laboratories. Doves from 11 collections were frozen for subsequent necropsy.

When feasible, two thin blood films were prepared immediately after collection. These were fixed in 100% methanol, stained with Giemsa, and examined for microfilariae and hematozoans. Mouth and throat scrapings and swabs were taken from birds from 14 collection sites. Scrapings were mixed with 0.85% saline and examined microscopically (100-450X) for trichomonads. Swabs were placed in Locke's solution, maintained at room temperature, and examined similarly. Bone marrow samples were taken from doves at nine sites, mixed with Ringer's solution, and examined for trypanosomes.

Birds were skinned and representative tissue samples for histopathologic examination were placed in 10% buffered formalin. The remaining portions of major

<sup>1</sup> This study was supported by an appropriation from the Congress of the United States. Funds were administered and research coordinated under the Federal Aid in Wildlife Restoration Act (50 Stat. 917) and through Contract No. 14-16-0008-676, Fish and Wildlife Service, U.S. Department of Interior.

<sup>2</sup> Captain, U.S. Army Veterinary Corps, Academy of Health Sciences, U.S. Army, Veterinary Science Division, Fort Sam Houston, Texas 78234, USA. The opinion or assertions contained herein are the private views of the author and are not to be construed as official or as reflecting the views of the Department of the Army or the Department of Defense.

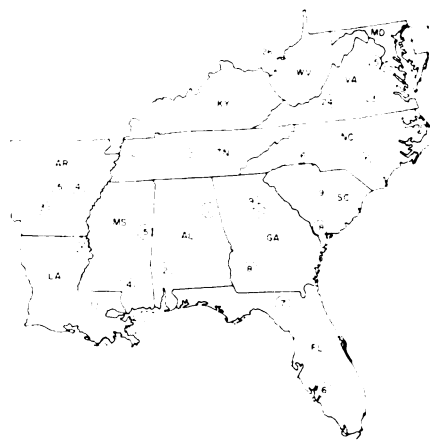


FIGURE 1. Location of mourning dove collection sites within the southeastern United States. (1) Calhoun Co.\*; (2) Clarke Co.\*; (3) Clark Co.; (4) Prairie Co.; (5) Pulaski Co.; (6) Charlotte Co.; (7) Suwannee Co.\*; (8) Dougherty Co.\*; (9-10) Morgan Co.; (11) East Baton Rouge Par.; (12) East Carroll Par.; (13) Kent Co.\*; (14) Lamar Co.\*; (15) Noxubee Co.\*; (16) Cleveland Co.\*; (17) Cumberland Co.; (18) Hampton Co.; (19) Richland Co.; (20) Gibson Co.\*; (21) Rutherford Co.; (22) King George Co.; (23) Nottoway Co.; (24) Roanoke Co.; (25) Stafford Co.; and (26) Mason Co.\*  
\*Birds frozen

organs were examined under a dissecting microscope for helminths. The gastrointestinal tract was separated into anatomical divisions, opened, scraped, and the contents of each portion washed separately through 100 mesh screens. The retained material was preserved in formalin (5%)-acetic acid (2.5%) solution. Helminth parasites were later counted and identified. Examination for intestinal protozoans was made by direct saline smears.

Following fixation, tissue samples were embedded in paraffin, sectioned, and stained with hematoxylin and eosin according to standard procedures. These samples were examined for microscopic lesions associated with parasitism.

## RESULTS AND DISCUSSION

Examination of 255 mourning doves revealed 6 species of protozoans (Table 1) and 7 helminths (Table 2). Parasites reported for the first time from mourning doves include *Sarcocystis* sp., *Echinostoma revolutum*, *Hymenolepis* sp., *Aproctella stoddardi*, *Ascaridia columbae*, and *Dispharynx nasuta*.

*Eimeria* spp. oocysts were encountered infrequently. A thickened duodenal mucosa occurred in two doves harboring numerous tissue stages of this parasite. *Eimeria* sp. has been reported from mourning doves on one previous occasion,<sup>1</sup> the infection having been described as non-pathogenic. Although the distribution of *Eimeria* spp. infections encountered during the current study was widespread, it is likely that coccidian parasites are of only incidental importance in free-flying doves.

Gametocytes of *Haemoproteus maccallumi* were readily detected in infected birds. Lung schizonts, resembling those previously described from mourning doves,<sup>8</sup> were observed histologically in three doves with monoinfections of *H. maccallumi*. *Haemoproteus sacharovi* was observed less frequently than *H. maccallumi* and asexual stages were not seen. Dual infections of *H. maccallumi* and *H. sacharovi* occurred in six (4%) birds. The prevalence of infection by members of the genus *Haemoproteus* was similar to that reported from other studies.<sup>10</sup> Neither *H. maccallumi* nor *H. sacharovi* is considered to cause significant pathologic effects in mourning doves.<sup>4</sup>

*Sarcocystis* sp. was detected by microscopic examination of tissue sections of striated muscle from 32 doves. All infected birds had cysts in breast muscle although seven doves also harbored cysts in cardiac musculature. Multiple cysts per tissue section were encountered frequently. Recent studies<sup>7</sup> have shown that *Sarcocystis* undergoes a coccidian life cycle and that there are closely related genera which can be differentiated only by experimental transmission. During the current study, however, all sporozoan cysts detected in striated muscle were

TABLE 1. Protozoan parasites recovered from mourning doves collected in the Southeast.

Parasite	No. Birds Examined	Sites Examined†	Percent Prevalence	Distribution†
<i>Eimeria</i> spp.	254	1-26	7	1-5,8,9,11,14,18,19,22
<i>Haemoproteus maccallumi</i>	140	3-6,9-12,17-19,21-23	33	3-6,9-12,17-19
<i>Haemoproteus sacharovi</i>	140	3-6,9-12,17-19,21-23	18	3,10,11,17-19,21-23
<i>Sarcocystis</i> sp.	255	1-26	13	4-5,12,13,17-22,24-26
<i>Trichomonas gallinae</i>	140	4-6,9-12,17-19,21-24	16	5,9,19,22,23
<i>Trypanosoma</i> sp.	90	3-5,11-12,17,22-24	3	3,12

† Numbers refer to Fig. 1; frozen birds were not examined for all protozoans.

TABLE 2. Helminth parasites recovered from 255 mourning doves collected in the Southeast.

Parasite	Percent Prevalence	Number per Infection		Distribution‡
		Mean	Range	
<b>TREMATODA</b>				
<i>Echinostoma revolutum</i>	<1	3	1-3	8,9
<b>CESTODA</b>				
<i>Hymenolepis</i> sp.	5	1	1-4	4,6,7,9,10,13,14,17,20,22,23,26
<i>Killigrewia delafondi</i>	4	2	1-8	4,5,7,10,17,23,26
<b>NEMATODA</b>				
<i>Aproctella stoddardi</i>	8	9	1-62	2,7,8,14,17,19,23
<i>Ascaridia columbae</i>	2	48	4-127	6,19
<i>Dispharynx nasuta</i>	2	3	1-5	1,11,14,25
<i>Ornithostrongylus quadriradiatus</i>	51	9	1-58	1-7,9,11-18,20-26

‡ Numbers refer to Figure 1.

designated as *Sarcocystis* sp. The prevalence of *Sarcocystis* may well have been higher had additional tissue sections been examined.

*Trichomonas gallinae* occurred in 23 (16.4%) of 140 doves, but gross lesions attributable to this organism were not observed. The prevalence of *T. gallinae*, although comparable with figures previously reported,<sup>3,6</sup> may have been higher had culture methods been employed. Although certain strains of this parasite are known to be extremely pathogenic,<sup>11,14</sup> infected birds frequently do not exhibit gross lesions.<sup>3,6</sup>

*Trypanosoma* sp. were observed in three (3.3%) of 90 doves. Two of these doves were from the same collection site. The actual prevalence of *Trypanosoma* sp. probably was higher than the observed value since methods utilized were not as efficient as culture techniques. Infected birds did not appear to be detrimentally affected by this parasite. Avian trypanosomes are generally considered to be non-pathogenic.<sup>15</sup>

One specimen of *Echinostoma revolutum* was found in an adult male dove and three specimens in an immature female. Although mourning doves have been experimentally infected with other trematodes,<sup>2,13</sup> the occurrence of *E. revolutum* represents the first report of a naturally occurring trematode infection in mourning doves. The low prevalence of this helminth suggests that it is rare in this host.

Cestodes were represented by only two species, both of which occurred infrequently and with low intensity. The maximum burden per bird of *Hymenolepis* sp. was four. Eleven of 14 (78.6%) infected doves harbored only one specimen. Of doves infected with *Killigrewia* (= *Aporina*) *delafondi*, eight of nine (88.9%) harbored either one or two specimens of this helminth. *K. delafondi* has been reported from doves on several

previous occasions.<sup>9,10,12,17</sup> The genus *Hymenolepis* is reported herein for the first time in the mourning dove.

*Aproctella stoddardi* usually was found free in the body cavity; however, in two doves this filarial worm was found in the pericardial sac. Lesions associated with *A. stoddardi* were a granulomatous pericarditis in one dove and adhesions of the liver and small intestine to the body wall in another. Three of six infected doves for which blood films were available had a microfilaremia.

Infections with *Ascaridia columbae* generally involved fewer than 30 worms per bird. Two doves, harboring 127 and 108 *A. columbae* respectively, exhibited distention of portions of the duodenum, accompanied by localized mucosal hyperemia.

*Dispharynx nasuta* occurred in the proventriculi of six doves from four collection sites. Lesions were not observed in infected birds.

Although *A. stoddardi*, *A. columbae*, and *D. nasuta* may occasionally be associated with pathologic lesions, their infrequent occurrences suggests limited effects in doves.

*Ornithostrongylus quadriradiatus* was the most prevalent and widely distributed endoparasite encountered during this study. This parasite has been reported previously from doves.<sup>18,19</sup> The pathologic effects of large numbers of this parasite have been described in pigeons<sup>5</sup> and include catarrhal enteritis and anemia. The majority of infected doves (75.8%) harbored fewer than 10 specimens and significant lesions were not associated with infection with *O. quadriradiatus*.

This study revealed that doves harbor a larger variety of endoparasites than was previously known; however, the prevalence and intensity of endoparasites among mourning doves were low, and pathologic lesions were minimal.

#### Acknowledgments

Special thanks are extended to personnel of the game and fish agencies of Alabama, Arkansas, Florida, Georgia, Louisiana, Maryland, Mississippi, North Carolina, South Carolina, Tennessee, Virginia and West Virginia and personnel from Sandhills National Wildlife Refuge, Camp Pickett, Camp Robinson, Fort Bragg, and the Quantico Marine Corps Base for aid in collecting and for use of laboratory facilities in examining doves. The senior author is indebted to members of the U.S. Army Veterinary Corps for continued encouragement and support.

## LITERATURE CITED

1. BOUGHTON, D. C. and J. J. VOLK. 1938. Avian hosts of Eimerian coccidia. *Bird-banding* 9: 139-153.
2. CAMPBELL, R. A. 1972. New experimental hosts for *Posthodiplostomum minimum* (Trematoda: Diplostomatidae). *J. Parasit.* 58: 501.
3. CARPENTER, J. W., J. C. LEWIS and J. A. MORRISON, 1972. *Trichomonas gallinae* (Rivolta, 1878) Stabler, 1938, in mourning doves, *Zenaidura macroura*, in northwest Oklahoma. *Proc. Okla. Acad. Sci.* 52: 39-40.
4. COOK, R. S. 1971. *Haemoproteus* Kruse, 1890. In: *Infectious and Parasitic Diseases of Wild Birds*. Davis, J. W., R. C. Anderson, L. Karstad, and D. O. Trainer, eds. Iowa State Univ. Press, Ames. p. 300-308.
5. CUVILLIER, E. 1937. The nematode, *Ornithostrongylus quadriradiatus*, a parasite of the domesticated pigeon. U.S. Dept. of Agric. Tech. Bull. No. 569. 36 pp.
6. DONNELLY, J. A. 1962. Trichomoniasis in the mourning dove. *W. Va. Conserv.* 26: 13-14.
7. FRENKEL, J. K. 1974. Advances in the biology of sporozoa. *Z. Parasitenk.* 45: 125-162.
8. GREINER, E. C. 1971. The comparative life histories of *Haemoproteus sacharovi* and *Haemoproteus maccallumi* in the mourning dove (*Zenaidura macroura*). Ph.D. Dissertation, Univ. of Nebraska, Lincoln. 81 pp.
9. HANSON, H. C., N. D. LEVINE, C. W. KOSSACK, S. KANTOR and L. J. STANNARD. 1957. Parasites of the mourning dove (*Zenaidura macroura carolinensis*) in Illinois. *J. Parasit.* 43: 186-193.
10. HARKEMA, R. 1942. The mourning dove, a new host of the anoplocephalid tapeworm, *Aporina delafondi* (Railliet). *J. Parasit.* 28: 495.
11. HAUGEN, A. O. 1952. Trichomoniasis in Alabama mourning doves. *J. Wildl. Manage.* 16: 164-169.
12. HERMAN, C. M. 1955. Removal of tapeworms from a live dove. *Proc. Helm. Soc. Wash.* 22: 129.
13. HOFFMAN, G. L. and J. B. HUNDLEY. 1957. The life-cycle of *Diplostomum baeri eucaliae* n. subsp. (Trematoda: Strigeida). *J. Parasit.* 43: 613-625.
14. KOCAN, R. M. and C. M. HERMAN. 1971. Trichomoniasis. In: *Infectious and Parasitic Diseases of Wild Birds*. Davis, J. W., R. C. Anderson, L. Karstad and D. O. Trainer, eds. Iowa State Univ. Press, Ames. p. 282-290.
15. LEVINE, N. D. 1973. *Protozoan Parasites of Domestic Animals and of Man*. Burgess Publ. Co., Minneapolis, Minn. 406 pp.
16. ——— and S. KANTOR. 1959. Check-list of blood parasites of birds of the order Columbiformes. *Wild. Dis.* 1: 1.
17. THOMPSON, C. S. 1901. Further tapeworm observations. *Condor* 3: 15.
18. VIGUERAS, I. P. 1934. *Ornithostrongylus crami* n. sp. (Nematoda) parasito de *Zenaidura macroura macroura*. *Mem. Soc. Cubana Hist. Nat.* 8: 53-54.
19. WEHR, E. E. 1930. The occurrence of *Ornithostrongylus quadriradiatus* in the mourning dove. *J. Parasit.* 16: 167.

Received for publication 28 July 1976