



THE GROSS AND HISTOPATHOLOGIC LESIONS OF MALIGNANT CATARRHAL FEVER IN THREE CAPTIVE SIKA DEER (*Cervus nippon*) IN SOUTHERN ONTARIO

Authors: SANFORD, S. E., LITTLE, P. B., and RAPLEY, W. A.

Source: Journal of Wildlife Diseases, 13(1) : 29-32

Published By: Wildlife Disease Association

URL: <https://doi.org/10.7589/0090-3558-13.1.29>

BioOne Complete (complete.BioOne.org) is a full-text database of 200 subscribed and open-access titles in the biological, ecological, and environmental sciences published by nonprofit societies, associations, museums, institutions, and presses.

Your use of this PDF, the BioOne Complete website, and all posted and associated content indicates your acceptance of BioOne's Terms of Use, available at www.bioone.org/terms-of-use.

Usage of BioOne Complete content is strictly limited to personal, educational, and non - commercial use. Commercial inquiries or rights and permissions requests should be directed to the individual publisher as copyright holder.

BioOne sees sustainable scholarly publishing as an inherently collaborative enterprise connecting authors, nonprofit publishers, academic institutions, research libraries, and research funders in the common goal of maximizing access to critical research.

THE GROSS AND HISTOPATHOLOGIC LESIONS OF MALIGNANT CATARRHAL FEVER IN THREE CAPTIVE SIKA DEER (*Cervus nippon*) IN SOUTHERN ONTARIO

S. E. SANFORD and P. B. LITTLE, Department of Pathology, Ontario Veterinary College,
University of Guelph, Guelph, Ontario, Canada

W. A. RAPLEY, Metro Toronto Zoo, Toronto, Ontario, Canada

Abstract: The gross and histopathologic lesions of three captive sika deer (*Cervus nippon*) with malignant catarrhal fever are described. Lesions included those of the head and eye form and the more commonly described peracute form. One deer had been exposed to a wildebeeste (*Connochaetes gnou*) and the other two to domestic sheep.

INTRODUCTION

Malignant catarrhal fever (MCF) is a well-documented viral disease of cattle and other domestic ruminants around the world.⁷ The first report among cervids in North America was made by Clark *et al.*¹ in axis deer (*Axis axis*) in Texas in 1970. Later, Wyand *et al.*¹¹ documented the disease in captive white-tailed deer (*Odocoileus virginianus*) in New Jersey in 1971. The most recent report was by Pierson *et al.*⁶ in captive mule deer (*Odocoileus hemionus*) in Colorado in 1974.

CASE HISTORIES

Case 1

On 28 March, 1973, three Dybowski sika deer (*Cervus nippon hortulorum*) were shipped from a zoo in Frankfurt, Germany and placed in quarantine facilities in Quebec, Canada. A South African wildebeeste (*Connochaetes gnou*) accompanied the deer on the aircraft from Germany. At the quarantine station they were housed in separate pens of the same barn and all had the same attendant. On 28 April, a 1-year-old female was observed to be thin, shivering and anorectic. The next day she was administered 400 mg. oxytetracycline[□] intramuscularly

(I.M.). Although she remained anorectic, shivering ceased in 24 hrs. All deer were released from quarantine and shipped to the Metro Toronto Zoo, arriving the night of 30 April. She appeared depressed and had red urine, but her stool was firm and she would eat periodically. On 1 May, she died, 24 hrs after arrival. The remaining two deer died with similar clinical signs within 8 weeks.

Cases 2 and 3

Four Japanese sika deer (*Cervus nippon*) were placed on an 8 ha. wooded area surrounded by chain-link fence on a hobby farm near London, Ontario in September, 1974. A 2-year-old male was observed lethargic on 18 January, 1975. If disturbed, the animal would tremble and fall. His condition did not improve and he was found dead on the morning of 22 January. Another 2-year-old male Japanese sika deer was found dead on the same morning, but no sign of illness was observed prior to death. The remaining two deer appeared to be unaffected.

Lambs had been on this farm since the spring of 1974. Sheep had been on the adjoining farm for several years. Direct contact with both flocks of sheep was possible.

□ Oxytetracycline as Liquamycin. Pfizer Company, Montreal, Canada.

MATERIALS AND METHODS

At necropsy, tissue specimens were fixed in 10% neutral buffered formalin, embedded in paraffin, sectioned at 5 μ m and stained with hematoxylin and eosin. Tissues from deer 2 and 3 were collected for bacteriologic examination. Samples of spleen, lymph node and brain from the same were frozen and stored at -20 C. Virus isolation in bovine thyroid cell cultures^{7,8} was attempted using ground spleen from deer 3. In addition, the ground spleen from deer 3 was diluted in Hank's balanced salt solution⁹ and 10 ml of a 10% suspension was injected I.M. into a captive white-tailed deer. Every day for a month, rectal temperatures were taken and the deer was observed for signs of clinical illness.

RESULTS

Microbiologic and Experimental Transmissions

No pathogenic bacteria was cultured and no virus was isolated using the techniques described. The experimental deer appeared clinically unaffected and rectal temperatures were within normal limits throughout the period of observation.

Necropsy Findings

Numerous erosions were present on the outer and inner surfaces of the lip and gingiva of deer 1. The hard and soft palates had 5-10 mm ulcers. Peripheral lymph nodes were enlarged, soft and hemorrhagic and mesenteric lymph nodes were enlarged. The urinary bladder mucosa contained numerous 1-3 mm hemorrhagic foci. The gastrointestinal (G.I.) tract contained no grossly visible lesions.

No oral lesions were present in deer 2 and 3. In deer 2, a generalized lymphadenopathy and hemorrhages were present in the conjunctiva, submucosa of the small and large intestines and in the parenchyma of both testicles. In deer 3, submucosal and/or subserosal hemorrhages were present in rumen, reticulum, small and large intestines and liver. Spleens were extremely congested in deer 2 and 3.

Histopathological Findings

Microscopic lesions were most pronounced in deer 1. A widely disseminated vasculitis involved small- and medium-sized arteries and veins throughout the brain, leptomeninges, lung, spleen, lymph nodes, urinary bladder, hard and soft palates and skin. Vasculitis with associated thrombi-involved vessels was in the lamina propria of the hard and soft palates and skin. Overlying epithelia often was necrotic. Necrosis also was observed in the germinal centers of the lymph nodes and focally in the adrenal cortex. The vasculitis was characterized by infiltration of lymphoid cells into tunica muscularis and adventitia (Figure 1). Perivascular cuffs of lymphoid cells were common.

A necrotizing vasculitis, generally involving the full thickness of vessel walls of the lung and lymph nodes and fibrinoid degeneration of vessel walls of the

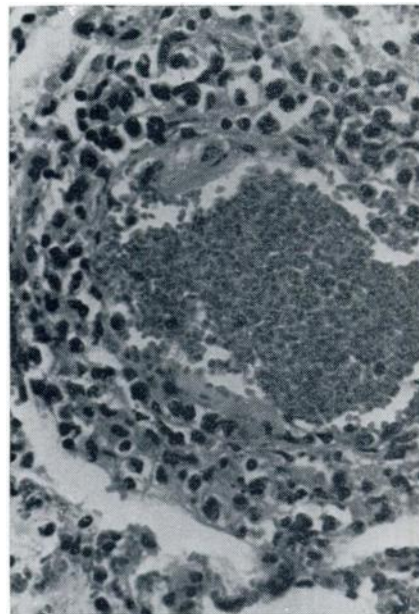


FIGURE 1. Arteriole in lung of case 1 demonstrating infiltration of lymphoid cells in tunica muscularis and adventitia. H&E stain X 252.

abomasum and brain were the most prominent lesions observed in deer 2. Perivascular lymphoid cell infiltration was evident in the leptomeninges. There were also massive hemorrhages into the intratubular spaces of both testicles.

Deer 1 and 2 also had multi-focal, mononuclear cell accumulations in the cortices of the kidneys and in the portal triads of the liver as well as a bilateral, non-suppurative, panophthalmitis. The ophthalmitis was characterized by lymphoid cell cuffs surrounding vessels of the episclera, ciliary body, choroid and retina. Ocular involvement in deer 1 appeared more severe and included perivascular lymphoid cell cuffs of optic nerve vessels and a modest lymphoid cell infiltrate into the substantia propria of the cornea.

Lesions in deer 3 were characterized by diffuse hemorrhages in the lamina propria, submucosa and tunica muscularis of the rumen, reticulum, omasum, small and large intestines, and in the parenchyma of the lung and liver. In addition, there was an acute vasculitis with fibrinoid changes in the muscularis of small- and medium-sized arterioles of the brain and leptomeninges. Focal lymphoid cell accumulations were observed around arterioles of the renal cortices. Lymph nodes had extensive hyperplasia of lymphoid elements. Vascular thrombosis was not observed in any of the tissues examined, nor were any ocular lesions seen.

The spleens of deer 2 and 3 were engorged with erythrocytes and splenic follicles were depleted of lymphocytes.

DISCUSSION

The gross and histopathologic lesions described in cases 1 and 2 are comparable with those reported previously for MCF in deer.^{1,2,4,10} In case 3, although the disease was characterized by generalized hemorrhages, the prominent lesion was hemorrhages of the G.I. tract, lung and liver, and the presence of vasculitis and fibrinoid changes of arterioles of the brain and leptomeninges. The absence of vascular thrombosis in any tissue was considered to be more indicative of per-

acute MCF than any of the other known viral diseases of deer. In addition, the presence of severe vasculitis and/or fibrinoid necrosis of arterioles of several tissues including brain are considered by some to be pathognomonic for the histopathologic diagnosis of MCF.⁵

The differential diagnosis of MCF in other cervids has been reviewed.^{1,4,11} However, the history of recent importation and the grossly visible oral lesion in case 1, and the hemorrhagic nature of the disease in the other two cases suggested that foot and mouth disease (FMD), epizootic hemorrhagic disease (EHD) and bluetongue (BT) should be considered.

Ulceration and necrosis of the mouth, feet and rumen have been reported in deer with FMD,^{4,6} but vasculitis is not a feature of FMD.^{3,5}

The gross and histopathologic lesions of EHD and BT are nearly identical in deer and consist grossly of diffuse hemorrhages, and microscopically, of endothelial swelling and hyperplasia, accompanied by thrombosis of small blood vessels.^{2,9} Perivascular cuffing is also described in the central nervous system.^{2,9} The generalized vasculitis of MCF is more pronounced and fibrinoid changes of arteriolar walls is not a feature of EHD and BT.^{2,9}

Grossly visible ocular lesions were not seen in deer 1, but the distribution of other lesions and the microscopically visible ocular, oral and cutaneous lesions were similar to those seen by Huck *et al.*⁴ who characterized their cases as the head and eye form of MCF. The hemorrhages seen throughout the G.I. tract in deer 3 resembled changes seen in deer and cattle in the peracute form of the disease.^{5,11} Gross and histopathologic lesions described for deer 2 are intermediate in both severity and distribution.

MCF has been successfully transmitted from deer to experimental animals by parenteral inoculation of infected blood or tissue homogenates.⁴ Freezing tissues from these deer would certainly have destroyed the fragile, cell-associated, herpesvirus,^{4,6,7} and would have accounted for our failure to culture or transmit

this agent. Even so, freezing would not have destroyed the viruses of EHD or BT,^{2,9} or prevented transmission of either of these two diseases. This was not conclusive evidence of their absence but was contributory to their exclusion as the etiology of the subject disease.

Wildebееste have been shown to be inapparent carriers of the MCF virus in

Africa.^{5,7,9} It has been postulated that nasal shedding of MCF virus from wildebееste, under stress, may be the method of natural transmission of virus between wildebееste and from wildebееste to cattle.^{7,8} Circumstantial evidence of a similar role for sheep often has been presented, but conclusive experimental proof has consistently evaded workers.^{5,7}

Acknowledgements

The cooperation and advice of Drs. Lars Karstad, J. Hopkins and Mr. T. J. Berry of the Department of Pathology, Ontario Veterinary College are gratefully acknowledged. We also thank Dr. M. Savan of the Department of Veterinary Microbiology and Immunology, Ontario Veterinary College for his attempts at virus isolation.

Support for this work was made in part, by grants from the Pan-American Health Organization and the Ontario Ministry of Natural Resources.

LITERATURE CITED

1. CLARK, K. A., R. M. ROBINSON, R. G. MARBURGER, L. J. JONES and J. H. ORCHARD. 1970. Malignant catarrhal fever in Texas cervids. *J. Wildl. Dis.* 6: 376-383.
2. FLETCH, A. L. and L. H. KARSTAD. 1971. Studies on the pathogenesis of experimental epizootic hemorrhagic diseases of white-tailed deer. *Can. J. Comp. Med.* 35: 224-229.
3. ————. 1970. Foot-and-mouth disease. pp. 68-75. In: *Infectious Diseases of Wild Mammals*. J. W. Davis *et al.* (eds.) Iowa State Univ. Press, Ames, Iowa.
4. HUCK, R. A., A. SHAND, P. J. ALLSOP and A. B. PATTERSON. 1961. Malignant catarrh of deer. *Vet. Rec.* 73: 457-465.
5. JUBB, K. V. F. and P. C. KENNEDY. 1970. *Pathology of Domestic Animals*. Second Ed. Volume 2. Academic Press, New York and London, 7-34.
6. PIERSON, R. E., J. STORZ, A. E. MCCHESENEY and D. THAKE. 1974. Experimental transmission of malignant catarrhal fever. *Am. J. Vet. Res.* 35: 523-525.
7. PLOWRIGHT, W. 1968. Malignant catarrhal fever. *J. Am. vet. med. Ass.* 152: 795-806.
8. RWEYEMANU, M. M., L. KARSTAD, E. Z. MUSCHI, D. M. JESSETT, L. ROWE, S. DREVEMO and J. G. GROOTENHUIS. 1974. Malignant catarrhal fever virus in nasal secretions of the wildebееste: A probable mechanism for virus transmission. *J. Wildl. Dis.* 10: 478-487.
9. STAIR, E. L., R. M. ROBINSON and L. P. JONES. 1968. Spontaneous blue-tongue in Texas white-tailed deer. *Path. Vet.* 5: 164-173.
10. WOBESER, G., J. A. MAJKA and J. H. L. MILLS. 1973. A disease resembling malignant catarrhal fever in captive white-tailed deer in Saskatchewan. *Can. Vet. J.* 14: 106-109.
11. WYAND, D. S., C. F. HELMBOLDT and S. W. NIELSON. 1971. Malignant catarrhal fever in white-tailed deer. *J. Am. vet. med. Ass.* 159: 605-610.

Received for publication 24 September 1975