

COCCIDIA OF COYOTES IN EASTERN COLORADO 1

Author: ARTHUR, ROBERT G.

Source: Journal of Wildlife Diseases, 13(1) : 97-100

Published By: Wildlife Disease Association

URL: <https://doi.org/10.7589/0090-3558-13.1.97>

The BioOne Digital Library (<https://bioone.org/>) provides worldwide distribution for more than 580 journals and eBooks from BioOne's community of over 150 nonprofit societies, research institutions, and university presses in the biological, ecological, and environmental sciences. The BioOne Digital Library encompasses the flagship aggregation BioOne Complete (<https://bioone.org/subscribe>), the BioOne Complete Archive (<https://bioone.org/archive>), and the BioOne eBooks program offerings ESA eBook Collection (<https://bioone.org/esa-ebooks>) and CSIRO Publishing BioSelect Collection (<https://bioone.org/csiro-ebooks>).

Your use of this PDF, the BioOne Digital Library, and all posted and associated content indicates your acceptance of BioOne's Terms of Use, available at www.bioone.org/terms-of-use.

Usage of BioOne Digital Library content is strictly limited to personal, educational, and non-commercial use. Commercial inquiries or rights and permissions requests should be directed to the individual publisher as copyright holder.

BioOne is an innovative nonprofit that sees sustainable scholarly publishing as an inherently collaborative enterprise connecting authors, nonprofit publishers, academic institutions, research libraries, and research funders in the common goal of maximizing access to critical research.

COCCIDIA OF COYOTES IN EASTERN COLORADO[□]

ROBERT G. ARTHUR, Department of Veterinary Pathology and Hygiene,
University of Illinois, Urbana, Illinois 61801, USA

GEORGE POST, Department of Fishery and Wildlife Biology,
Colorado State University, Ft. Collins, Colorado 80523, USA

Abstract: Eighty-two coyote fecal samples were collected from eastern Colorado and examined for coccidia. Sporocysts of *Sarcocystis* were observed in 17 of the samples and oocysts of *Isoospora ohioensis* were observed in two samples. Ten fecal samples contained eimerian coccidia thought to be pseudoparasites of the coyote acquired while ingesting heavily infected rabbits.

INTRODUCTION

Intestinal metazoan parasites of free-ranging coyotes are well documented^{1,5,11} but little information is available on intestinal protozoan parasites. Thornton *et al.*¹¹ reported oocysts of *Isoospora rivolta* (*I. ohioensis* Dubey, 1975) from two of three coyotes in Texas. Fayer and Johnson⁴ observed sporocysts of *Sarcocystis fusiformis* in 21 of 150 fecal samples collected in Utah and Idaho, and mentioned that unsporulated oocysts resembling *Isoospora canis* were present in four pup coyotes live-trapped in Texas. The purpose of the present study was to examine coyotes from eastern Colorado for coccidia.

METHODS AND MATERIALS

Eighty-two coyote fecal samples were collected throughout the year between December, 1973, and January, 1975, in eastern Colorado. These samples included 48 scat samples obtained near dens or trails utilized by coyotes, 19 samples removed from the large intestine of coyotes shot or trapped, and 15 fecal samples from coyotes held in captivity. All captive coyotes had been removed from dens or live-trapped in eastern Colorado and had been maintained in

kennels at several locations at Colorado State University at least 90 days prior to fecal examination. These coyotes were fed commercially prepared dry dog food. Two to three grams of each fecal sample were weighed and prepared for fecal examination by use of the sugar flotation technique described by Levine.⁸

Fecal samples containing unsporulated coccidia were mixed with 2.5% potassium dichromate solution, poured into thin layer petri dishes, and maintained at 20-22 C for 4-7 days to initiate sporulation. Coccidia were examined for specific morphology. Measurements were made with an ocular micrometer utilizing the oil immersion objective (100 x).

RESULTS

Coccidia were observed in 14 of 48 (29.2%) scat samples collected near dens or runs, and in 10 of 19 (52.6%) samples removed from the large intestine of dead coyotes. Coccidia were not found in the fecal samples from captive coyotes. Sporocysts of *Sarcocystis* were the most frequently observed coccidia, occurring in 17 of 82 (20.7%) samples. Sporocysts (Fig. 1) were ellipsoidal, usually with one side flattened. Doublet sporocysts surrounded by the thin oocyst

[□] A portion of a thesis submitted to the Graduate School at Colorado State University in partial fulfillment of the requirements for Master of Science in Wildlife Biology.

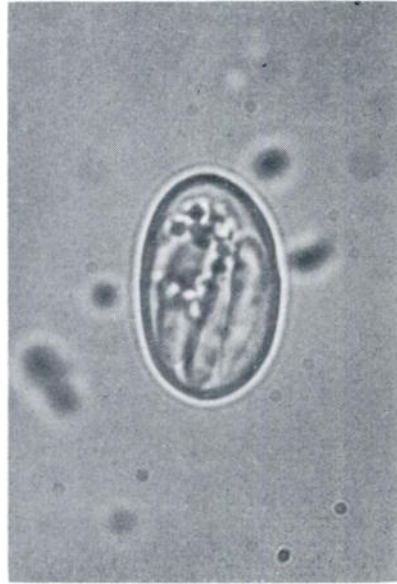

FIGURE 1. *Sarcocystis* sporocyst. X1600.

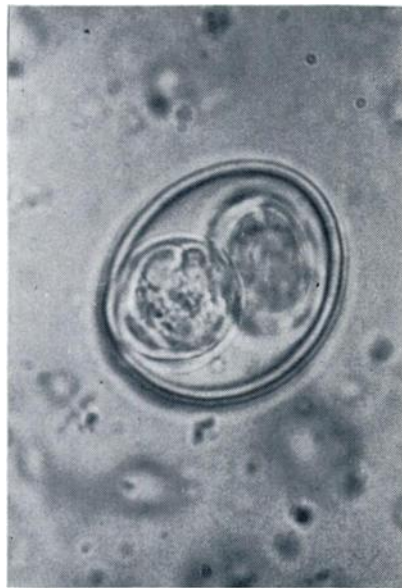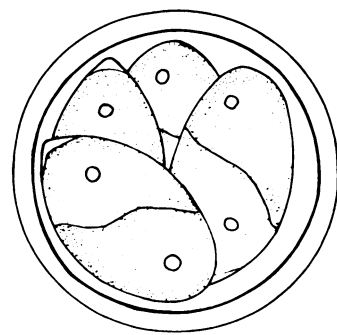


FIGURE 2. Sporulated oocyst of *Isospora ohioensis*. X1000.

wall were frequently observed. One hundred sporocysts from 13 samples measured 14.0-17.0 by 8.5-10.5 μm (average 16.0 by 9.6). The majority of the fecal samples with *Sarcocystis* contained from 10-300 sporocysts per g, although one sample was estimated to contain over 760,000 sporocysts per g.

Two fecal samples obtained near coyote dens contained unsporulated oocysts of *Isospora ohioensis* in addition to *Sarcocystis* sporocysts. *I. ohioensis* oocysts were ellipsoidal to ovoid in shape. Fifty oocysts measured 17.0-23.0 by 15.0-20.5 μm (average 20.6 by 17.3). Their length-width ratio was 1.12-1.31 (average 1.19). Sporulation occurred after 4 days in 2.5% potassium dichromate solution at 20-22 C. Sporulated oocysts (Fig. 2) contained two ellipsoidal sporocysts 13.0 by 12.0 μm . A diffuse or compact sporocyst residuum was present.

Three fecal samples examined contained unsporulated spherical oocysts measuring 8.5-11.4 by 8.2-11.2 μm (average 9.8 by 9.6). The sporont consisted of granules either compact and centrally positioned or diffused and scattered throughout. Sporulation occurred after 5 days in 2.5% potassium dichromate solution at 20-22 C and revealed the oocyst to be a species of *Eimeria* (Fig. 3). A polar granule occasionally was observed.



10 μm

FIGURE 3. Sporulated E-1 oocyst.

There was no oocyst or sporocyst residuum. The sporocysts were elongate, 6.0 by 4.0 μm , with a small Stieda body. The sporozoites were lying lengthwise from head to tail in the sporocyst and contained a small refractile globule. Two of the fecal samples contained 80-100 oocysts per g of feces and the third contained 680. Sporocysts of *Sarcocystis* were present in each case this organism was observed. Exact identification of this *Eimeria* remains in doubt. This coccidia is later referred to as E-1.

Ten fecal samples contained heterogeneous oocysts ranging from 17.0-30.0 by 15.0-22.0 μm . These organisms varied in shape, color, and presence or absence of a micropile. Up to 25% of these organisms sporulated and sporulation revealed they were mixed species of *Eimeria*. Although these species of *Eimeria* were observed frequently, the oocysts were never present in large numbers, and were considered pseudoparasites of the coyotes.

DISCUSSION

Some fecal samples collected from dens and runs may have been subjected to freezing, drying, sunlight or leaching by snow or rain, although only fresh appearing scat was sampled. As a result, coccidia were observed more frequently in samples removed directly from the large intestine of dead coyotes.

Sporocysts of *Sarcocystis* observed in this study were similar in size and morphology to *Sarcocystis fusiformis* reported in free-ranging coyotes by Fayer and Johnson.⁴ A 14% prevalence of *Sarcocystis* infection was reported by Fayer and Johnson while a 20.7% prevalence of infection was observed in the present study. Heydorn and Rommel⁷ determined that sporocysts of *S. fusiformis* were first passed in the feces of dogs 9-10 days after feeding bovine tissue infected with *S. fusiformis* zites, and were observed in the feces for 8-10 weeks after inocu-

lation. Heydorn *et al.*⁸ discussed much of the present knowledge concerning life cycles and taxonomy of the sarcosporidia.

I. ohioensis observed in the present study was similar to those organisms described in the dog by Dubey.² Loveless and Anderson⁹ reported that *I. canis* and *I. rivolta* (*I. ohioensis* Dubey, 1975) from the dog are infective for coyotes.

Eimeria similar to the E-1 observed in this study have not been reported as actual parasites of carnivores. E-1 is not similar to coccidia known to infect small rodents, birds, rabbits or other small animals that serve as food sources for coyotes in Colorado. E-1 was similar to *Eimeria subspherica*, a relatively uncommon bovine coccidia. Coyotes have been known to feed upon fresh cattle manure, but the feasibility of a coyote ingesting a quantity of cattle manure which would yield as many as 680 oocysts per g of coyote feces without the presence of additional bovine coccidia is remote. In addition, E-1 was observed in feces from a coyote killed in an area free of cattle. The possibility exists that E-1 is an actual parasite of the coyote, but additional research will be necessary.

The other *Eimeria* observed in this study resembled a mixed infection of rabbit coccidia containing *E. media*, *E. environ* and *E. audubonii*. Duszynski and Marquardt³ reported that all of 100 cottontail rabbits (*Sylvilagus audubonii*) from northeastern Colorado were infected with 1-6 species of *E. environ*, *E. maior*, *E. media*, *E. audubonii*, *E. neoirresidua*, and *E. poudrei*. Pellérdy¹⁰ suggested that reports of *Eimeria canis* in dogs were actually rabbit coccidia acquired by feeding upon heavily infected rabbits. This phenomenon is believed to be responsible for the large assortment of rabbit-like coccidia observed in coyotes in eastern Colorado. Coyotes could spread rabbit coccidia since some of these coccidia were viable and sporulated after passage through the digestive tract of coyotes.

Acknowledgements

The authors wish to thank Bruce Wheat for his assistance in preparing the photographs used in this manuscript.

LITERATURE CITED

1. BUTLER, J. M. and A. W. GRUNDMAN. 1954. The intestinal helminths of the coyote, *Canis latrans*, in Utah. *J. Parasit.* 40: 440-443.
2. DUBEY, J. P. 1975. *Isospora ohioensis* sp. n. proposed for *I. rivolta* of the dog. *J. Parasit.* 61: 462-465.
3. DUSZYNSKI, D. W. and W. C. MARQUARDT. 1969. *Eimeria* (Protozoa: *Eimeriidae*) of the cottontail rabbit *Sylvilagus audubonii* in northern Colorado, with descriptions of three new species. *J. Protozool.* 16: 128-137.
4. FAYER, R. and A. J. JOHNSON. 1975. *Sarcocystis fusiformis* infection in the coyote (*Canis latrans*). *J. Infect. Dis.* 131: 189-192.
5. GIER, H. T. and D. J. AMEEL. 1968. Parasites and diseases of Kansas coyotes. *Kans. Agric. Exp. Sta., Tech. Bull.* 104.
6. HEYDORN, A. O., R. GESTRICH, H. MEHLHORN and M. ROMMEL. 1975. Proposed for a new nomenclature of the *Sarcosporidia*. *Z. Parasitenk.* 48: 73-82.
7. ——— and M. ROMMEL. 1972. Beiträge zum Lebenszyklus der Sarkosporidien. II. Hund und Katze als Überträger der Sarkosporidien des Rindes. *Berl. Münch. Tierärztl. Wochen.* 85: 121-123.
8. LEVINE, N. D. 1973. *Protozoan Parasites of Domestic Animals and of Man*. 2nd ed. Burgess Publishing Company, Minneapolis, p. 380.
9. LOVELESS, R. L. and F. L. ANDERSON. 1975. Experimental infection of coyotes with *Echinococcus granulosus*, *Isospora canis*, and *Isospora rivolta*. *J. Parasit.* 61: 546-547.
10. PELLERDY, L. P. 1965. *Coccidia and coccidiosis*. Akadémiai Kiadó, Budapest, Hungary. pp. 468-469.
11. THORNTON, J. E., R. R. BELL and M. J. REARDON. 1974. Internal parasites of coyotes in southern Texas. *J. Wildl. Dis.* 10: 232-236.

Received for publication 14 July 1976