



## **SOME CLINICO-PATHOLOGIC FINDINGS IN ELEPHANTS (*Elephas maximus*) INFECTED WITH *Fasciola jacksoni***

Authors: CAPLE, I. W., JAINUDEEN, M. R., BUICK, T. D., and SONG, C. Y.

Source: Journal of Wildlife Diseases, 14(1) : 110-115

Published By: Wildlife Disease Association

URL: <https://doi.org/10.7589/0090-3558-14.1.110>

---

BioOne Complete ([complete.BioOne.org](https://complete.BioOne.org)) is a full-text database of 200 subscribed and open-access titles in the biological, ecological, and environmental sciences published by nonprofit societies, associations, museums, institutions, and presses.

Your use of this PDF, the BioOne Complete website, and all posted and associated content indicates your acceptance of BioOne's Terms of Use, available at [www.bioone.org/terms-of-use](https://www.bioone.org/terms-of-use).

Usage of BioOne Complete content is strictly limited to personal, educational, and non - commercial use. Commercial inquiries or rights and permissions requests should be directed to the individual publisher as copyright holder.

---

BioOne sees sustainable scholarly publishing as an inherently collaborative enterprise connecting authors, nonprofit publishers, academic institutions, research libraries, and research funders in the common goal of maximizing access to critical research.

## SOME CLINICO-PATHOLOGIC FINDINGS IN ELEPHANTS (*Elephas maximus*) INFECTED WITH *Fasciola jacksoni*

I. W. CAPLE,<sup>□</sup> M. R. JAINUDEEN, T. D. BUICK and C. Y. SONG

Faculty of Veterinary Medicine and Animal Science, Universiti Pertanian Malaysia, Sungai Besi, Selangor, Malaysia.

**Abstract:** Severe submandibular and ventral abdominal oedema was observed in an Asian elephant (*Elephas maximus*) in which liver flukes (*Fasciola jacksoni*) were recovered from the bile ducts at post-mortem examination. Clinico-pathologic examination of blood samples and serum from this elephant and another 8 elephants showed that most had anemia and hypoproteinemia. Fecal samples from 6 of the elephants contained from 6 to 83 eggs per gram. Treatment of elephants with nitroxylin (10 mg/kg) by subcutaneous injection produced severe local reactions at the injection site. Feces collected 2 and 4 months after treatment were free of trematode eggs. Hematologic values measured 4 months after treatment showed that the hemoglobin concentration, packed cell volume, erythrocyte count and plasma protein concentration had increased to within the normal range.

### INTRODUCTION

Infection of the liver in elephants (*Elephas maximus*) with flukes (*Fasciola jacksoni*) has been associated with clinical signs such as pale mucous membranes, depraved appetite, loss of weight and submandibular swellings.<sup>3,6,8</sup> Clinical pathology studies of blood and serum of elephants with fascioliasis has not been reported. There are few references to the treatment of fascioliasis in elephants,<sup>13</sup> and many drugs, such as hexachloroethane, may not be tolerated.<sup>8</sup>

During an investigation of submandibular and ventral abdominal oedema, and death attributed to liver flukes in a group of elephants in Central Malaysia, the hemoglobin concentration, packed cell volume, erythrocyte and leucocyte counts and plasma protein concentration of affected elephants was studied before and after treatment

with subcutaneous injections of nitroxylin.<sup>□</sup> The effects of nitroxylin on fluke infections, and the reactions to the drug are described.

### MATERIALS AND METHODS

A group of nine elephants were kept in a jungle clearing in Pahang in Central Malaysia and fed sugar cane, bread and banana leaves, and were allowed to graze in the jungle while on a chain leash. Their ages were estimated to range from 4 to 30 years, and their weights from 500 to 3000 kg.

Two elephants developed oedema in the submandibular region within eight months of capture. In the first elephant, a female estimated to be about 11 years old, oedema initially became apparent around the umbilicus. This oedema gradually became larger and a submandibular swelling developed. The oedematous area in-

<sup>□</sup> Present Address and Reprint Requests: 'Attwood' Veterinary Research Laboratory, Mickleham Road, Westmeadows, 3047, Australia.

<sup>□</sup> Trodax, May & Baker (Pty) Ltd., Petaling Jaya, Kuala Lumpur, Malaysia.

creased in size over a period of three months before the elephant died (Fig. 1). At post-mortem examination numerous trematodes were found in the bile ducts.

When the second elephant (Kala) developed submandibular oedema it was considered that treatment should be attempted before the condition progressed. As oral administration of drugs to elephants, particularly untrained elephants, was found to be difficult, nitroxylin was given by subcutaneous injection. Feces of all elephants were examined for trematode eggs by a zinc sulphate flotation technique<sup>1</sup> before treatment, and the

response to nitroxylin was monitored by examination of feces for eggs two and four months after treatment.

Blood samples were collected from a marginal ear vein of four elephants before treatment and four months after treatment to determine total erythrocyte (RBC) and leucocyte (WBC) counts, packed cell volume (PCV), hemoglobin concentration (Hb) and total plasma protein concentration.<sup>7</sup>

Sulphobromophthalein (BSP) liver function tests were performed on four elephants including Kala. A polyvinylchloride cannula was introduced into a marginal ear vein of each ear, and



FIGURE 1. Asian elephant showing clinical signs of submandibular and ventral oedema associated with anemia and hypoproteinemia and infection of *Fasciola jacksoni*.

the clearance rate of BSP from the bloodstream was determined by injection of 100 ml of a 5% solution of BSP <sup>□</sup> into one ear vein and estimation of the plasma BSP concentration in accurately timed samples taken from the other ear vein during the next 30 minutes.<sup>4</sup> From these data the time for the plasma concentration to be halved was calculated.

As there was no information on the dose rate or toxicity of nitroxylnil in elephants, one elephant (Kala) was injected subcutaneously with nitroxylnil solution containing 34% active ingredient at a dose rate of 10 mg/kg. The elephant received a total of 25 ml of solution given at five sites on the hindquarters. This elephant was examined for evidence of systemic toxicity, and the rectal temperature was monitored for two days after treatment. There was no detectable reaction in this elephant apart from slight swelling at three of the injection sites one week later. The other seven elephants received nitroxylnil at a dose rate of 10 mg/kg, and subcutaneous injections of 3 to 10 ml of solution were given on either side of the neck in five elephants and at the base of the tail in two elephants.

#### RESULTS AND DISCUSSION

Trematodes obtained from the bile ducts of the dead elephant were identified as *Fasciola jacksoni*.<sup>3,12</sup> In six of the eight elephants fecal samples contained operculated *F. jacksoni* eggs which measured 60-72 × 108-132 μm, and the number of eggs ranged from 6 to 83 per gram of feces.

Although only two of the elephants showed clinical signs of submandibular and ventral abdominal oedema, most had anemia and hypoproteinemia be-

fore treatment. One week before the most severely affected elephant died the blood Hb concentration was 4.5 g% which is less than one-third commonly reported in normal Asian elephants.<sup>7</sup> The hematologic findings in four elephants infected with *F. jacksoni* (Table 1) were similar to those described in sheep infected with *F. hepatica*,<sup>10</sup> and the pathogenesis of the infections is probably similar.

We could not find any published information on BSP excretion in elephants. This test is a sensitive indicator of liver function in domestic animals,<sup>4</sup> and was adapted for use in elephants. In sheep infected with liver flukes, BSP clearance rates are decreased. The BSP clearance rates in the elephants Kala and Pagi were slower than in Lakimala and Cikmek, and this may have been related to the degree of liver damage. However, it would be necessary to use other tests of liver function to support this finding.

Nitroxylnil did not cause any systemic reaction, but in seven elephants local reactions occurred at the injection sites (Fig. 2). These reactions appeared to be unrelated to the volume of nitroxylnil injected, or the site of the injection, and varied from a local swelling to a circular lesion of about 4 cm in diameter (Fig. 2). The centres of these lesions either sloughed or were debrided surgically two weeks after the injection, and the lesions healed within two months (Fig. 3). This particular preparation of nitroxylnil may be unsuitable for use in elephants because of this local reaction to subcutaneous injection.

Nitroxylnil was effective in treating the trematode infection as fecal samples collected two and four months after treatment contained no *F. jacksoni* eggs. Since strongyle and paramphi-

<sup>□</sup> Bromthalein, Merck, Darmstadt, Germany.

TABLE 1. Hematologic values and BSP half-time in plasma in four elephants before treatment with nitroxylinil, and hematologic values four months after treatment.

Elephant		Hb g%	PCV %	RBC $10^6/\text{mm}^3$	WBC $10^3/\text{mm}^3$	Plasma g%	BSP half-time min
Kala	Before	6.8	19	1.53	14.5	5.4	5.1
	After	9.9	27	1.66	8.5	6.8	
Pagi	Before	9.0	26	not recorded		5.8	6.5
	After	11.1	32	1.75	7.8	6.8	
Cikmek	Before	7.7	28	1.81	17.0	8.6	3.6
	After	13.5	40	2.98	12.2	9.9	
Lakimala	Before	9.0	28	2.30	16.2	8.6	4.3
	After	12.1	36	3.05	17.8	9.4	
Normal values*		12.1	34	3.18	14.7	9.0	

\*Reported for Asian elephants by Jainudeen and Jayasinghe<sup>7</sup>.

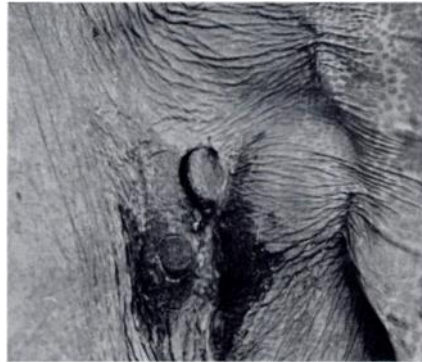


FIGURE 2. Lesions on neck of elephant at injection sites where nitroxylin was given two weeks previously.

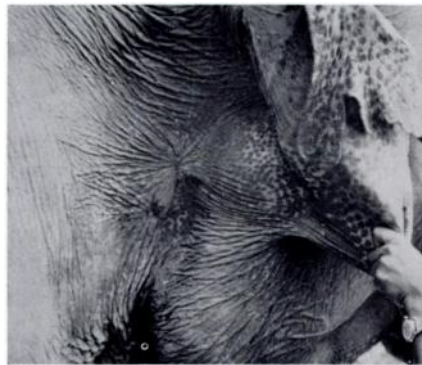

FIGURE 3. Same lesions as in Figure 2 after two months.

stone eggs were present in most fecal samples, the elephants were given thiabendazole <sup>□</sup> three months after treatment with nitroxylin because the strongyle egg count was up to 200 eggs per gram in one elephant. Numerous nematodes identified as *Murshidia murshida* and *Quillonia renneie*<sup>12</sup> were passed in the feces the day following treatment with thiabendazole.

The physical condition of the elephants improved after treatment

with nitroxylin. In the elephant Kala, submandibular oedema was not apparent one month after treatment. In blood samples taken four months after treatment the PCV, Hb and RBC were considerably higher than in the blood samples taken before treatment and the plasma protein concentration also had increased (Table 1). The supplementary feed given to the elephants was increased after treatment and this also may have contributed to their recovery.

Submandibular and ventral abdominal oedema, commonly known as 'rot' in elephants, has been recorded with fluke infection for more than a century,<sup>3,6</sup> and probably is associated with a reduced plasma colloid osmotic pressure when the plasma protein concentration falls to abnormally low levels. Anemia and hypoproteinemia commonly occur in elephants infected with hookworms<sup>11</sup> and intestinal flukes.<sup>13</sup> Submandibular oedema also has been observed in an elephant with tuberculosis.<sup>9</sup> Oedema in elephants is not diagnostic for trematode infections; this type of response also occurs in congestive heart failure, kidney and liver disease, gastrointestinal parasitism and inanition. A definitive diagnosis depends on a detailed clinical examination and clinico-pathologic findings. It was considered that the hypoproteinemia in the elephant probably was due to a number of factors, including liver damage, gastrointestinal parasitism and inadequate nutrition. The pathophysiology of anemia in fluke infections of elephants is unknown. In other animals, anemia has been attributed to loss of blood through the biliary tract and to impaired erythrocyte production due to poor nutrition of affected animals.<sup>5</sup>

<sup>□</sup> Thiabendazole; Merck, Sharp & Dohme, Sydney, Australia.

**Acknowledgements**

The authors thank Mr. Mohammed Khan, Chief Game Warden of Malaysia for assistance in the collection of samples, and for his interest and encouragement. Nitroxynil was obtained through the courtesy of May & Baker (Pty) Ltd, Kuala Lumpur, Malaysia. Drs. Caple and Buick were on an assignment of the Australian-Asian Universities Co-operation Scheme sponsored by the Australian Development Assistance Agency.

**LITERATURE CITED**

1. BORAY, J. C. and I. G. PEARSON, 1960. The anthelmintic efficiency of tetrachlorodifluoroethane in sheep infested with *Fasciola hepatica*. Aust. vet. J. 36: 331-337.
2. ———. 1967. Studies on experimental infections with *Fasciola hepatica* with particular reference to acute fascioliasis in sheep. Ann. trop. Med. Parasit. 61: 439-450.
3. COBBOLD, T. S. 1882. The Parasites of Elephants. Trans. Linn. Soc., London, 2nd Ser. zoology, Vol. 2. pt. 4. 223-258.
4. CORNELIUS, C. E. 1970. Liver Function. In: *Clinical Biochemistry of Domestic Animals*. J. J. Kaneko and C. E. Cornelius, Eds. 2nd. ed. Vol. 1. p. 161-230. Academic Press, New York and London.
5. DAWES, B. and D. L. HUGHES. 1970. Fascioliasis: The invasive stages in mammals. In: *Advances in Parasitology*. B. Dawes ed. Vol. 9. p. 259-274. Academic Press, London and New York.
6. EVANS, G. H. 1910. In: *Elephants and their Diseases*. Government Printery, Rangoon, Burma.
7. JAINUDEEN, M. R. and J. B. JAYASINGHE. 1971. Hemogram of the domesticated asiatic elephant (*Elephas maximus*). J. Zoo anim. Med. 2: 5-11.
8. McGAUGHEY, C. A. 1962. Diseases of Elephants. Part V. Internal Parasites. Ceylon vet. J. 10: 61-64.
9. PINTO, M. R. M., M. R. JAINUDEEN and R. G. PANABOKKE. 1973. Tuberculosis in a domesticated Asiatic elephant (*Elephas maximus*). Vet. Rec. 93: 662-664.
10. SINCLAIR, K. B. 1962. Observations on the clinical pathology of ovine fascioliasis. Brit. vet. J. 118: 37-53.
11. SUTHERLAND, A. K. and P. J. O'SULLIVAN. 1950. Helminthiasis in an elephant. Aust. vet. J. 26: 88-89.
12. VAN DER WESTHUYSEN, O. P. 1938. Helminth parasites of the elephant. Onderspoort J. Vet. Sci. 10: 49-190.
13. WINDSOR, R. S. and W. A. SCOTT. 1976. Fascioliasis and salmonellosis in African elephants in captivity. Br. vet. J. 132: 313-317.

Received for publication 5 July 1977