

Paragonimus westermanni IN TIGERS (Panthera tigris) 1 IN INDIA.

Authors: SINGH, N. P., and SOMVANSHI, R.

Source: Journal of Wildlife Diseases, 14(3) : 322-324

Published By: Wildlife Disease Association

URL: <https://doi.org/10.7589/0090-3558-14.3.322>

The BioOne Digital Library (<https://bioone.org/>) provides worldwide distribution for more than 580 journals and eBooks from BioOne's community of over 150 nonprofit societies, research institutions, and university presses in the biological, ecological, and environmental sciences. The BioOne Digital Library encompasses the flagship aggregation BioOne Complete (<https://bioone.org/subscribe>), the BioOne Complete Archive (<https://bioone.org/archive>), and the BioOne eBooks program offerings ESA eBook Collection (<https://bioone.org/esa-ebooks>) and CSIRO Publishing BioSelect Collection (<https://bioone.org/csiro-ebooks>).

Your use of this PDF, the BioOne Digital Library, and all posted and associated content indicates your acceptance of BioOne's Terms of Use, available at www.bioone.org/terms-of-use.

Usage of BioOne Digital Library content is strictly limited to personal, educational, and non-commercial use. Commercial inquiries or rights and permissions requests should be directed to the individual publisher as copyright holder.

BioOne is an innovative nonprofit that sees sustainable scholarly publishing as an inherently collaborative enterprise connecting authors, nonprofit publishers, academic institutions, research libraries, and research funders in the common goal of maximizing access to critical research.

Paragonimus westermani IN TIGERS (*Panthera tigris*)[□] IN INDIA.

N. P. SINGH and R. SOMVANSHI, College of Veterinary Sciences, G.B. Pant University of Agriculture and Technology, Pantnagar (India)

Abstract: *Paragonimus westermani* was found in the lungs of two young tigers (*Panthera tigris*). Cysts were focally distributed in the lungs, initiating an emphysematous response together with extensive fibrosis in the vicinity of the cysts.

INTRODUCTION

Paragonimus westermani was first reported in the lungs of two Bengal tigers that died in the Hamburg and Amsterdam Zoological gardens.² Later the trematode was reported from the lungs of a tiger in England¹ and from leopard and tigers in China.³

The present paper records the presence and pathogenicity produced by *P. westermani* in the lungs of two tigers (*Panthera tigris*) from the Tarai area on the foothills of the Himalayas.

CASE REPORT

Two young tigers were brought to the University for necropsy. Tissues were collected for histopathology and chemical analysis. The tissues were processed routinely, sectioned at 5 μ m and stained with haematoxylin and eosin. The significant findings were recorded photographically.

Grossly, the lung parenchyma was emphysematous, dark brown in colour, consolidated and contained numerous small, spherical, focally distributed, raised cysts measuring approximately 1 cm in diameter. Each cyst contained clear watery fluid and pairs of ovoid, reddish brown, fleshy trematodes measuring approximately 0.6 to 1.0 cm in length. The trematodes were identified as *P. westermani*. All other visceral organs appeared normal.

Histopathologic examination of the cysts revealed two trematodes surrounded by an empty space (probably containing the watery fluid seen on gross examination (Fig. 1) and a distinct cyst wall consisting of thick connective tissue (Fig. 2). Extensive fibrosis and destruction of the normal architecture of lung parenchyma around the cyst wall was evident.

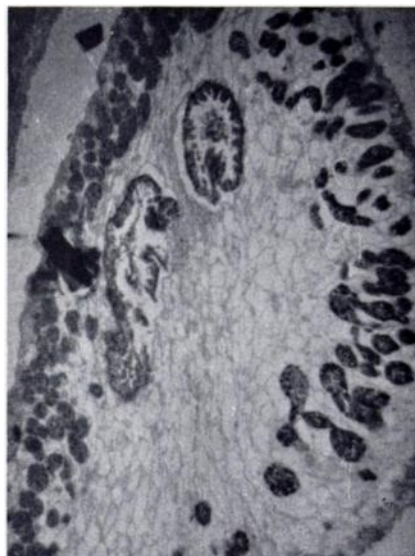


FIGURE 1. Cross section of parasite within the cyst in lung parenchyma. H & E. $\times 35$

[□] Research Paper No. 1278 through the Experimental Station GBPUAT, Pantnagar, Nainital, U.P.

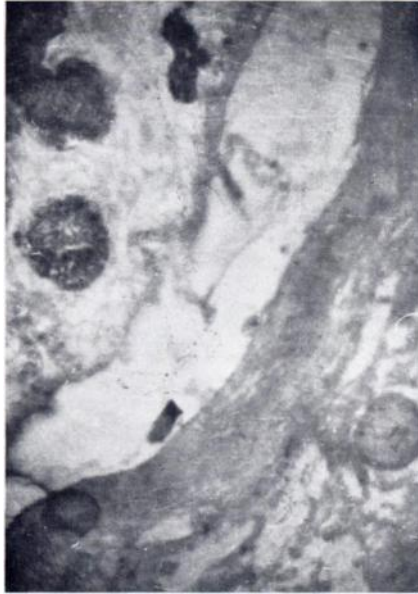

FIGURE 2. Parasitic cyst showing thickened capsule of fibrous tissue around the parasite. H & E. $\times 35$

Trematode eggs were randomly distributed within the lung parenchyma (Fig. 3). The inner content of some eggs was not visible, only the egg shell being discernible. Alveoli around these eggs were completely consolidated. There was infiltration of mononuclear inflammatory cells and macrophages, resembling a granuloma. Occasionally some eggs released from worms were observed lying in the clear space near the cystic wall. The alveoli in other areas showed atelectasis and blood pigments. Hemorrhage was an occasional feature.

DISCUSSION

P. westermanni is the only trematode reported from the lungs of tigers. In the present investigation the parasite was recorded in two tigers (one male and one female). Grossly the parasitic cysts were spherical, approximately 1 cm in diameter, and focally distributed

throughout the lung parenchyma. Wu⁷ and McGaughery,⁴ while studying the transmission of the parasite also found enlarged and fibrosed submaxillary glands in an infected tigress. Her lungs were consolidated, dark brown, tough and leathery in nature. In the present investigation, however involvement of submaxillary glands was not a feature. Other visceral organs also failed to reveal any pathoanatomical changes. Wu⁷ found pleural thickening and atelectasis of lungs and this was clearly observed in the present investigation. However, no communication of the cysts with the bronchioles for escape of eggs could be observed. Jubb and Kennedy¹ reported that in some cases such communications may not be observed and after the death or migration of adults such cavities may be obliterated with fibrous connective tissue.

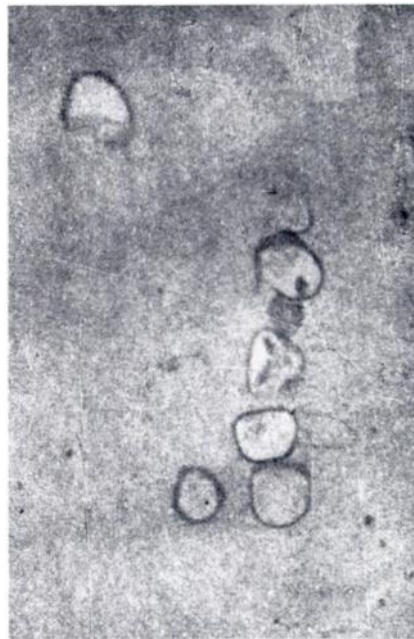

FIGURE 3. Oval clusters within the granuloma and with complete consolidation of lung parenchyma. H & E. $\times 70$

The consolidated areas seen around ova of trematodes consisted of infiltration with inflammatory cells, degeneration and necrosis, which was identical to the granulomas described by Soulsby⁶ and Smith *et al.*⁵ Such clusters of ova may be due to aspiration of eggs from bronchioles, and these ova may remain in the body for a long time, even sur-

passing the death or disappearance of the parasite.¹

The trematodes were not considered to be the cause of death in these tigers. Soulsby⁶ considered that the parasites in the lungs are not usually of great importance but those lodged in the brain and other organs may cause trouble.

LITERATURE CITED

1. JUBB, K.V.F. and P.C. KENNEDY. 1970. *Pathology of Domestic Animals*, Vol. I. p. 264. Academic Press. N.Y.
2. KERBERT. 1887. Cited by Shipley, A.E. 1905.
3. McGAUGHERY, C.A. 1931. *Paragonimus westermanni* in a captive tigress. *J. Comp. Pathol.* 44: 209-212.
4. SHIPLEY, A.E. 1905. Notes on parasites from zoological gardens in London and elsewhere. *Proc. Zool. Soc. London* 1: 248.
5. SMITH, H.T., T.C. JONES and R.D. HUNT. 1972. *Veterinary Pathology*. Fourth Ed. Lea and Febiger, Philadelphia pp. 807-808.
6. SOULSBY, E.J.L. 1969. *Helminths, Arthropods, and Protozoa of Domesticated Animals*. Sixth Ed. E.L.B.S. and Baillier, Tindall & Coswell London. pp. 57-61.
7. WU, K. 1938-39. *Paragonimus* among leopards and tigers in China. *Peking Nat. Hist. Bull.* 13: 231-249.

Received for publication 23 August 1977.