

## **AVIAN POX INFECTION IN AN AMERICAN GREEN-WINGED TEAL (*Anas crecca carolinensis*) IN ALASKA**

Authors: MORTON, JAMIE K., and DIETERICH, ROBERT A.

Source: Journal of Wildlife Diseases, 15(3) : 451-453

Published By: Wildlife Disease Association

URL: <https://doi.org/10.7589/0090-3558-15.3.451>

---

The BioOne Digital Library (<https://bioone.org/>) provides worldwide distribution for more than 580 journals and eBooks from BioOne's community of over 150 nonprofit societies, research institutions, and university presses in the biological, ecological, and environmental sciences. The BioOne Digital Library encompasses the flagship aggregation BioOne Complete (<https://bioone.org/subscribe>), the BioOne Complete Archive (<https://bioone.org/archive>), and the BioOne eBooks program offerings ESA eBook Collection (<https://bioone.org/esa-ebooks>) and CSIRO Publishing BioSelect Collection (<https://bioone.org/csiro-ebooks>).

Your use of this PDF, the BioOne Digital Library, and all posted and associated content indicates your acceptance of BioOne's Terms of Use, available at [www.bioone.org/terms-of-use](http://www.bioone.org/terms-of-use).

Usage of BioOne Digital Library content is strictly limited to personal, educational, and non-commercial use. Commercial inquiries or rights and permissions requests should be directed to the individual publisher as copyright holder.

---

BioOne is an innovative nonprofit that sees sustainable scholarly publishing as an inherently collaborative enterprise connecting authors, nonprofit publishers, academic institutions, research libraries, and research funders in the common goal of maximizing access to critical research.

## AVIAN POX INFECTION IN AN AMERICAN GREEN-WINGED TEAL (*Anas crecca carolinensis*) IN ALASKA

JAMIE K. MORTON and ROBERT A. DIETERICH, Institute of Arctic Biology, University of Alaska, Fairbanks, Alaska 99701, USA.

**Abstract:** Poxvirus infection was diagnosed on the basis of gross and microscopic appearance plus the presence of typical inclusion bodies in a juvenile American green-winged teal (*Anas crecca carolinensis*) in Alaska. This constitutes the first known report of avian pox in migratory ducks and the first report of poxvirus infection in wild birds in Alaska.

### INTRODUCTION

Avian pox with two forms of lesions<sup>1,2,5</sup> has been reported in at least 60 species of birds belonging to 20 different families since the late 1800's.<sup>4</sup> Pox usually is seen in the fall and winter in chickens but has been reported year-round in wild birds.<sup>5</sup> The use of vaccines has greatly reduced the economic losses in domestic poultry.<sup>1</sup>

Strains are defined as mono-, bi- or tri-pathogenic based on host specificity, and Kirmse reported strains seem more host

specific in smaller birds.<sup>8</sup> Pigeon strains appear to be mainly monopathogenic.<sup>7</sup> Fowl pox has been transmitted experimentally to domestic ducks and geese causing lesions on the feet with focal epithelial proliferation and later necrosis and sloughing.<sup>3,7</sup>

Avian pox in free-living Anseriformes was not reported until 1969 when Leibovitz diagnosed it in a young mute swan (*Cygnus olor*) in New York. He described macules, papules, scabs and ulcers on unfeathered parts of the skin. He



FIGURE 1. American green-winged teal with raised nodular avian pox lesion on tip of bill.

was able to transmit the disease to domestic geese but not to domestic ducklings, chickens or pigeons.<sup>9</sup> Simpson *et al.* reported mild pox lesions on the head, feet and legs in one adult free-living and three subadult pen-reared sandhill cranes (*Grus canadensis protensis*), order Gruiformes, in Florida.<sup>10</sup> Cutaneous and diphtheritic lesions were recently reported in common murrelets (*Uria aalge*), order Charadriiformes, in California.<sup>3,4</sup> No reports of avian pox in free-living migratory ducks and geese were found in the literature.

#### CASE HISTORY

A juvenile male American green-winged teal was shot during hunting season at Minto Flats, approximately 50 km west of Fairbanks, Alaska in September 1978. A large (approximately 11 mm × 13 mm) firm dark nodular mass was observed on the dorsal surface of the distal end of the bill (Figure 1). The bird

appeared otherwise healthy and no gross internal lesions were seen.

The mass was preserved in 10% buffered formalin. The lesion was sectioned according to standard techniques at 7  $\mu$ m and stained with hematoxylin and eosin and with Lendrum's stain for inclusion bodies. Hypertrophy and hyperplasia of the epithelial cells with characteristic large acidophilic intracytoplasmic inclusion bodies were observed microscopically (Figure 2). The size and number of inclusion bodies increased in maturing cells located at an increasing distance from the stratum germinativum. Poxvirus infection was diagnosed on the basis of gross and microscopic appearance plus the presence of typical inclusion bodies. No virus isolation was attempted.

This constitutes the first known report of poxvirus infection in migratory ducks and the first report of avian pox in wild birds in Alaska. The infection was probably contracted in Alaska as the bird was young and had not yet migrated.

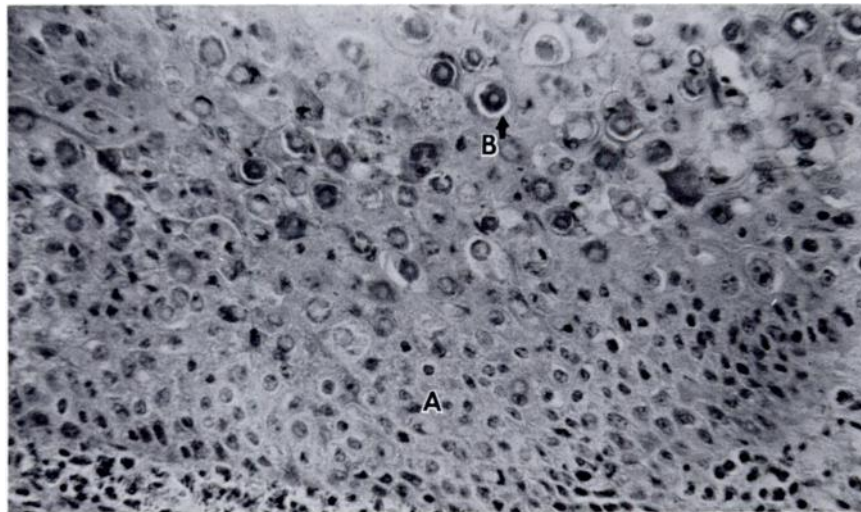


FIGURE 2. Photomicrograph of avian pox lesion. Note numerous large acidophilic intracytoplasmic inclusion bodies located above the stratum germinativum. A. Stratum germinativum. B. Inclusion bodies. (320 $\times$ )

**LITERATURE CITED**

1. BUXTON, A. and G. FRASER. 1977. *Animal Microbiology*. J.B. Lippincott Co., Philadelphia. 830 pp.
2. CUNNINGHAM, C.H. 1959. Fowl pox. pp. 575-598. In: *Diseases of Poultry*, Biester, H.E. and L.H. Schwarte, eds. Iowa State University Press, Ames, Iowa. 1103 pp.
3. HARRIS, J.M., A.S. WILLIAMS and F.R. DUTRA. 1978. Avian pox in a group of common (California) murres (*Uria aalge*). *Vet. Med./Small Anim. Clin.* 73: 918-919.
4. HILL, J.R. and G. BOGUE. 1978. Natural pox infection in a common murre (*Uria aalge*). *J. Wildl. Dis.* 14: 337-338.
5. KARSTAD, L. 1971. Pox. pp. 34-41. In: *Infectious and Parasitic Disease of Wild Birds*, Davis, J.W., R.C. Anderson, L. Karstad and D.O. Trainer, eds. Iowa State University Press, Ames, Iowa. 344 pp.
6. KIRMSE, P. 1967. Pox in wild birds. An annotated bibliography. *Wildl. Dis.* 49.
7. ———. 1969. Host specificity and pathogenicity of pox viruses from wild birds. *Bull. Wildl. Dis. Ass.* 5: 376-386.
8. ——— and H. LOFTEN. 1969. Avian pox in migrant and native birds in Panama. *Bull. Wildl. Dis. Ass.* 5: 103-107.
9. LEIBOVITZ, L. 1969. Natural occurrence and experimental study of pox and *Haemoproteus* infections in a mute swan (*Cygnus olor*). *Bull. Wildl. Dis. Ass.* 5: 130-136.
10. SIMPSON, C.F., D.J. FORRESTER and S.A. NESBITT. 1975. Avian pox in Florida sandhill cranes. *J. Wildl. Dis.* 11: 112-115.

*Received for publication 18 January 1979*

---