



**MORTALITY IN LITTLE PENGUINS (*Eudyptula minor*)
ALONG THE COAST OF VICTORIA, AUSTRALIA**

Authors: OBENDORF, D. L., and McCOLL, K.

Source: Journal of Wildlife Diseases, 16(2) : 251-260

Published By: Wildlife Disease Association

URL: <https://doi.org/10.7589/0090-3558-16.2.251>

BioOne Complete (complete.BioOne.org) is a full-text database of 200 subscribed and open-access titles in the biological, ecological, and environmental sciences published by nonprofit societies, associations, museums, institutions, and presses.

Your use of this PDF, the BioOne Complete website, and all posted and associated content indicates your acceptance of BioOne's Terms of Use, available at www.bioone.org/terms-of-use.

Usage of BioOne Complete content is strictly limited to personal, educational, and non - commercial use. Commercial inquiries or rights and permissions requests should be directed to the individual publisher as copyright holder.

BioOne sees sustainable scholarly publishing as an inherently collaborative enterprise connecting authors, nonprofit publishers, academic institutions, research libraries, and research funders in the common goal of maximizing access to critical research.

MORTALITY IN LITTLE PENGUINS (*Eudyptula minor*) ALONG THE COAST OF VICTORIA, AUSTRALIA

D. L. OBENDORF, Veterinary Clinical Centre, Department of Veterinary Paraclinical Sciences, University of Melbourne, Werribee, Victoria, 3030.

K. McCOLL, Department of Agriculture, Veterinary Research Institute, Parkville, Victoria, 3052.

Abstract: Forty-eight little penguins (*Eudyptula minor*) consisting of 21 (43.7%) mature, 18 (37.5%) juvenile and nine (18.7%) of undetermined age, from 10 Victorian coastal localities were examined during 1977-78. Thirty-seven (77%) of all penguins were in poor body condition with moderate to heavy burdens of internal and external parasites. Acute parasitic gastric ulceration with accompanying hemorrhage, was implicated in the death of four birds. Chronic gastric ulcers were thought to have caused appetite depression and starvation in 28 birds. Other significant lesions encountered included renal coccidiosis, parasitic cholangiohepatitis and pulmonary aspergillosis. It is suggested that the increased mortality experienced during 1977-78 was due to starvation or to exacerbation of the effects of existing parasite burdens on starving and exhausted birds.

INTRODUCTION

The little penguin (*Eudyptula minor*) is the smallest species of penguin and the only one to breed along the Australian coast. Every year dead penguins are found along Victorian coastal beaches, and recovery of flipper bands from dead birds has shown that young penguins experiencing their first year at sea are primarily involved. However, from December, 1977 to June, 1978, ornithologists noted that in addition to the juvenile birds, an unusually large number of mature penguins also was found dead or moribund. Similar reports were received by the Victorian Division of Fisheries and Wildlife. As a result, an investigation was begun to study the possible causes for this mortality.

MATERIALS AND METHODS

Forty-eight little penguins were submitted to the Veterinary Clinical Centre and Veterinary Research Institute for post-mortem examination between December, 1977 and June, 1978. They were collected by members of the Victorian Ornithological Research Group

(VORG), officers of the Victorian Division of Fisheries and Wildlife, naturalists and the authors. The collection localities, together with the number of birds collected from each locality are shown in Fig. 1. Although many dead little penguins were observed at these localities, the 48 submitted birds were the only ones suitable for necropsy.

Birds were classified as adults or juveniles on the basis of body size and condition of the plumage, and were examined at necropsy. Parasites were removed, preserved in 70% ethyl alcohol and lodged with the parasite collection of the School of Veterinary Science, University of Melbourne. In some cases, direct microscopic examination of wet smears from the ureters, gall bladder and intestines was undertaken.

Tissue samples were fixed in 10% formal saline, paraffin embedded, sectioned at 5 μ m and stained with hematoxylin and eosin (H&E).

Bacteriologic examinations were made when considered necessary and in these cases, samples were inoculated into tetrathionate broth and cultured on both

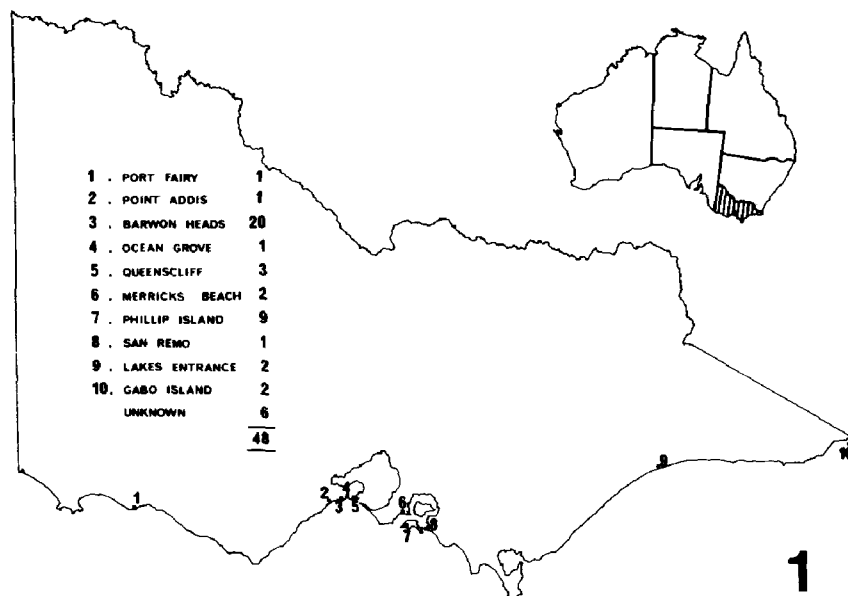


FIGURE 1. Map of the state of Victoria depicting the 10 localities where penguins were collected. The accompanying table lists the numbered localities and indicates the number of penguins examined from each locality.

sheep blood and McConkey agar. When fungal involvement was suspected, samples also were cultured on Sabouraud's agar.

RESULTS

Of the 48 penguins submitted, 21 (43.7%) were considered mature, 18

(37.5%) juvenile, and nine (18.7%) were of undetermined age. Thirty-eight (79%) of the birds were male.

The major necropsy findings encountered are summarized in Table 1. Emaciation, moderate to heavy burdens of both ectoparasites and endoparasites, and gastric ulcers were the most consistent findings.

TABLE 1. Prevalence of various necropsy findings in little penguins.

Age Group	Adult	Juvenile	Unknown	Total
Number of Birds	21	18	9	48
Poor Body Condition	18	15	4	37
Ectoparasites (fleas, lice and ticks)	7	16	2	25
Gastric Ulceration	14	12	6	32
Gastric Nematodes	16	15	5	36
Intestinal Coccidiosis	1	2	2	5
Intestinal Cestodes	16	15	9	40
Intestinal Trematodes	1	0	0	1
Pulmonary Aspergillosis	2	0	0	2
Diphtheritic Stomatitis/ Esophagitis	0	4	0	4

GROSS PATHOLOGY

Thirty-seven (77%) of all penguins examined were judged to be in poor body condition, and these birds showed atrophied muscles, depleted fat reserves, scant gastro-intestinal content, and small livers with enlarged gall bladders.

Moderate infestations of biting lice (*Austrogoniodes watersoni*) and fleas (*Parapsyllus australiacus*) were found on 15 immature, seven mature, and two unknown-aged birds. These penguins were all severely emaciated. The lice were usually located in sites inaccessible to the bird during preening, such as under the bill and around the head, while ticks (*Ixodes kohlsi*) were found predominantly in the external ear canal on five immature birds and one bird of unknown age.

Ulcers, often associated with nematodes, were found in the proventriculus and gizzard of 32 (67%) birds. The ulcers varied from 0.5-2.0 cm in diameter and were usually multiple (Fig. 2). Numerous yellow, punctate erosions approximately 2 mm in diameter also were noted around the periphery of the gastric ulcers; these appeared to be nematode-induced.

Twenty-eight of 32 ulcers (87.5%) were chronic, with nodular rounded edges, and lined with a firm, cream-white deposit. Occasionally, scarred nodular lesions were the only remaining evidence of prior gastric ulceration. When chronic ulcers were present, a thick tenacious mucus coating covered the proventricular and gizzard mucosa.

In four of 32 (12.5%) birds, acute ulcers with attached nematodes were seen. The birds had pale musculature and blood was present in the lumen of the proventriculus, gizzard and intestine (Fig. 3).

Adult and immature *Contraecaecum spiculigerum* were consistently found tightly attached to both acute and chronic ulcers, and stomach burdens of up to 300 nematodes were recorded.

Cestodes identified as *Tetrabothrius* sp. were found in the small intestine of 40

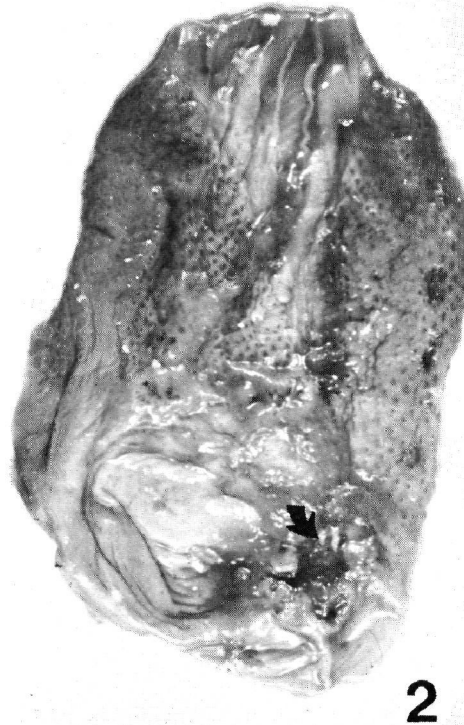

FIGURE 2. Chronic proventricular and gizzard ulcers after removal of nematodes and mucus. The arrow illustrates the cream-white deposit in the ulcers.

(83.3%) birds. Often the burden was so heavy that the duodenum was almost completely occluded by cestodes. One mature bird also had a heavy burden of the digeneid trematode *Galactosomum angelae*, but severe autolysis precluded histopathologic examination of this case.

Unsporulated oocysts were seen in intestinal wet preparations of five birds. The oocysts were suspended in 2.5% potassium dichromate solution but they failed to sporulate after 10 days at room temperature.

The livers generally were small and contracted and the gall bladders often were grossly enlarged (especially in emaciated birds). In only six penguins

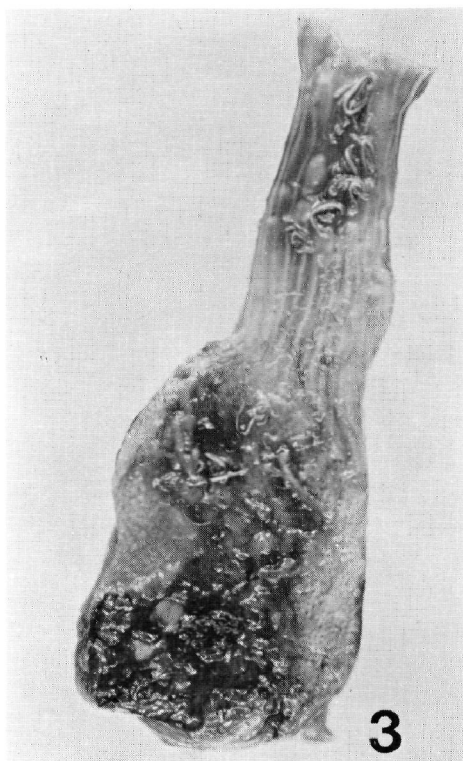


FIGURE 3. Stomach and esophagus of a little penguin with acute haemorrhagic ulceration associated with a large number of *Contracaecum spiculigerum*.

were additional gross liver changes noted. Two mature birds had firm white nodules 3 mm in diameter scattered throughout the liver parenchyma in close association with bile ducts. Four other birds (two immature and two of unknown age) had multiple dark brown nodular lesions 1-2 mm in diameter throughout the liver parenchyma. Several globular trematodes approximately 4 mm in length were found in these lesions and, in one case, some 400 trematodes were recovered from the liver. Numerous trematode eggs measuring $23.5 \times 20.3 \mu\text{m}$ ($22.5\text{-}25.0 \times 17.5\text{-}22.5$) were found in the bile. The trematodes were identified as *Renicola* sp., a parasite normally restricted to the kidney of its host. However, *Renicola* were not recovered

from the kidneys of these penguins, although trematodes were observed in histologic sections of kidney from one of these penguins.

Eleven birds (22.9%) had pale, swollen kidneys. White urate material was visible in the renal tubules, and in five of these penguins the ureters also appeared thickened and were distended with urates.

Pulmonary aspergillosis was diagnosed in two (4.1%) mature penguins. Focal white nodular lesions were scattered through the lung parenchyma. Similar white flattened plaques were present in the air sacs.

In four (8.3%) immature penguins, white encrustations were apparent under the tongue, on the palate, in the palatine cleft, at the commissures of the bill and in the esophagus. The esophageal lesion was quite marked in one bird with diphtheritic plaques extending along the longitudinal folds.

HISTOPATHOLOGY

Histologic examination of chronic gastric ulcers revealed complete loss of the normal mucosal architecture with deep ulceration into the submucosa. Extensive infiltration by lymphocytes and plasma cells, and proliferation of fibroblasts were observed at the margin of the ulcers. Secondary bacterial invasion and subsequent heterophil infiltration of the adjacent tissues were also noted. The cream-white deposit observed grossly in chronic ulcers was composed of a hyaline-like material. Impression molds of the anterior ends of nematodes were formed in this material, which appeared to attach them to the granulation tissue of the ulcer. Frequently, the nematode's anterior end had vacated the hyaline mold and its place was taken by numerous inflammatory cells and debris (Fig. 4).

Acute gastric ulcers consisted of extensive depressions in the mucosa with numerous hemorrhagic foci located on

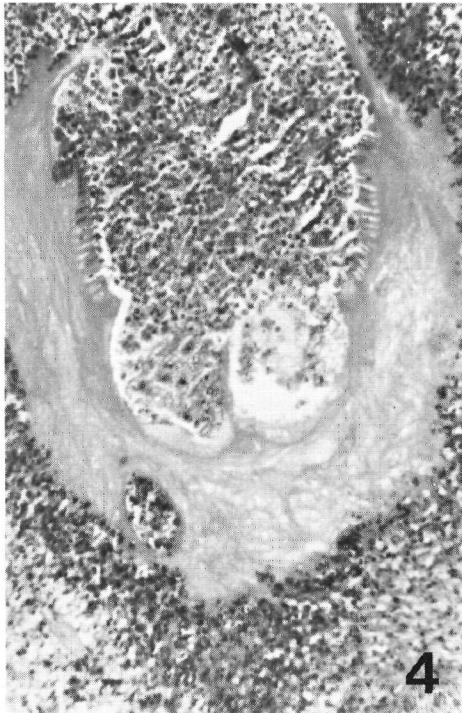


FIGURE 4. Gastric ulceration depicting a vacuolated hyaline impression mold of the anterior end of an ascaridoid nematode filled with inflammatory cells and debris. H&E $\times 450$

the edges and in the deeper parts of the lesions.

Coccidian schizonts were found in the lamina propria of the small intestine of only one bird.

Chronic cholangiohepatitis, characterised by hyperplasia of bile ducts, and periportal infiltration of mononuclear cells, occasional macrophages and fibroblasts was present in 14 of 26 livers (53.8%) examined histologically.

In the six birds where nodules were noted grossly throughout the liver, the histologic findings were similar although more severe and, in addition, there was widespread distribution of hemosiderin in Kupffer cells. The firm white nodules seen grossly in two birds were composed of a necrotic centre sur-

rounded by macrophages and foreign body giant cells containing lipid, mononuclear cells, and degenerate heterophils. The nodules appeared to be in the process of fibrous encapsulation. In the four birds with brown nodular lesions, adult trematodes were seen in cystic dilations of the bile ducts. Accumulations of cellular debris, fibrin and inflammatory cells filled the cystic bile ducts. Extensive erosion of the bile duct epithelium accompanied the presence of trematodes. Trematode eggs were found embedded in the fibrous tissue surrounding parasitized biliary tracts, and occasionally trematodes were found in the hepatic parenchyma, where they elicited a severe inflammatory reaction. This reaction was similar although somewhat more acute to that described in the two birds that had firm white hepatic nodules. A noticeable difference, however, was the lack of macrophages distended with fat. The only fat observed in these lesions was found within the body of the trematodes. In one further bird, of unknown age, no gross liver lesions were observed, but histopathologic examination revealed a chronic parasitic cholangiohepatitis with trematodes present in the parenchyma.

Histopathologic examination of the urinary tract revealed lesions in 20 of 31 kidneys examined (64.5%), with the commonest finding being focal chronic interstitial nephritis and intrarenal ureteritis. This was consistent with residual lesions of renal coccidiosis and, indeed, in 12 cases (38.7%), coccidian gametocyte stages and oocysts were seen. Gametogenous stages were located in the collecting ducts and intrarenal ureters (Fig. 5). Apparent blockage of the collecting ducts by accumulation of oocysts was observed (Fig. 6). The associated inflammatory reaction consisted of mild focal interstitial infiltration of lymphocytes and macrophages, with much cellular debris in the collecting tubules and ureters of affected kidneys. Intrarenal ureteritis,

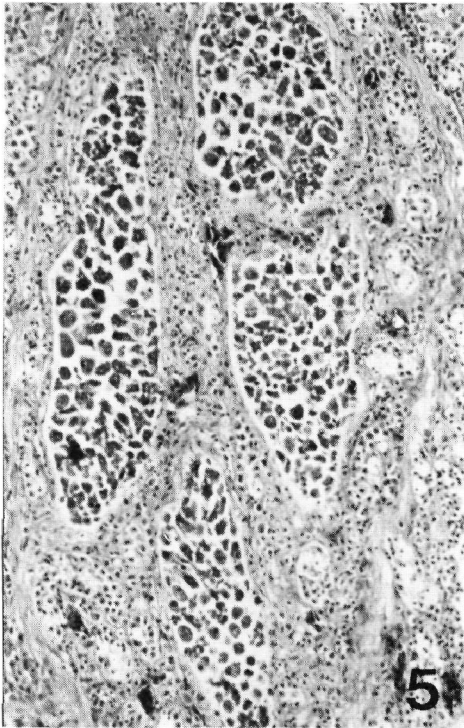


FIGURE 5. Renal coccidiosis, depicting gametogenous stages present in dilated collecting ducts of the kidney. H&E $\times 140$

characterized by infiltration of surrounding tissues by heterophils, lymphocytes and plasma cells was a common finding, while lymphoid follicular aggregations often were located in the ureteral wall of chronic cases. The only other renal lesion recorded was a case of severe nephrosis of unknown etiology.

Histologic examination of the white flattened plaques observed grossly in the lungs and air sacs revealed lesions characterized by a central necrotic core containing branching septate mycelia with an inflammatory reaction consisting of infiltrations of heterophils and macrophages, and exudation of fibrin into the adjacent lung tissue.

The oral and esophageal lesions were due to a mild diphtheritic inflammatory response, with a plaque composed of

cellular debris, bacteria and food material being formed. Ulceration of the esophageal mucosa and the formation of a fibronectic pseudomembrane was apparent histologically in the one bird with the gross esophageal lesions.

No significant fungi or bacteria were isolated from any of these upper alimentary tract lesions and bacteriologic examinations conducted on various organs of eight birds failed to isolate any significant pathogenic bacteria.

DISCUSSION

Mortalities of the little penguin have been reported on the North Island, New Zealand during the winter of 1973 and the autumn of 1974. The first occurrence followed stormy weather and involved birds of mixed age and sex, while the

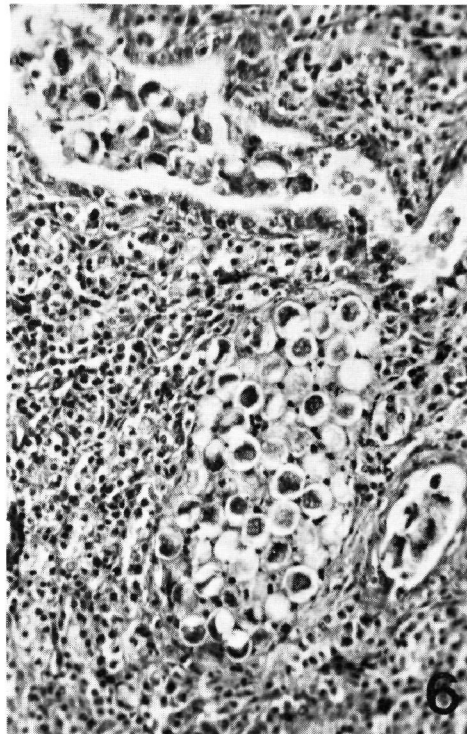


FIGURE 6. Renal coccidiosis, illustrating oocyst accumulation in the collecting ducts of the kidney. H&E $\times 450$

second appeared unrelated to storms and consisted exclusively of immature, predominantly female birds. The significant necropsy findings on both occasions were empty gastrointestinal tracts, depleted fat reserves, atrophic muscles and moderate to heavy parasite burdens. Unidentified renal trematodes were particularly common, and were associated with a mild inflammatory response. Biting lice and mites also were recorded.²

In the present study, the most significant and consistent findings were the poor body condition and the moderate to heavy internal and external parasite burdens. Acute parasitic gastric ulceration with accompanying hemorrhage was considered the cause of death in several birds. Chronic gastric ulceration may have resulted in the death of several other birds, due to appetite depression and starvation (as little or no stomach or intestinal content was found in these birds). Gastric ulcers associated with *Contracaecum* sp. also have been recorded in several species of pinnipeds and sea birds^{1,3,4,5,9,10} but, previously, such lesions have not been associated with poor body condition in the host. The hyaline-like mold attaching the nematodes to the ulcer and the host inflammatory response noted in this study were similar to those previously reported.⁵

It was difficult to assess the significance of the other parasite infections. Fourteen of 26 birds had a chronic cholangiohepatitis with *Renicola* sp. being found in five cases and implicated in two other very chronic cases (where the presence of lipid in macrophages and foreign body giant cells provided evidence of degenerating fluke). *Renicola* was also possibly responsible for the hepatic lesions in the remaining seven cases, although there was no evidence to support this contention. The liver appears to be an unusual site for the genus *Renicola* which normally inhabits the kidneys of birds (J. Pearson, Pers. Comm.) and has been reported in the

kidneys of the little penguin (B. Munday, Pers. Comm.). In fact, the severity and distribution of lesions in the seven birds where *Renicola* was implicated suggests that the trematode may be in either an aberrant host, or an aberrant tissue site.

The intestinal trematodes and cestodes were considered to be of minor significance. However, we were unable to assess the significance of intestinal coccidian infections in the few birds affected.

Renal coccidiosis generally appeared mild and focal with only two birds showing more severe and generalized lesions. It was considered that the urate retention could have caused the ureteritis, but the significance of this retention could not be assessed. The similarities between the renal coccidiosis lesions in this study and those reported by Munday *et al.*⁶ in Tasmanian mutton birds (*Puffinus tenuirostris*) provide an interesting comparison.

The significance of ixodid ticks on immature little penguins has been investigated in Australia.⁷ Up to 80 ticks were recorded on penguin chicks in a New South Wales colony, suggesting chicks may have died from high levels of infestation. In this study, the significance of ectoparasites was considered minimal.

In most years, the majority of beach-washed little penguins are immature birds spending their first year at sea. This probably is associated with the long distances that many of these birds travel within weeks of leaving a breeding colony. One immature bird was found dead on a beach 800 km from its colony within 39 days of banding,⁸ and although recovery of banded birds is low (approximately 4%), there is evidence to suggest that many immature birds travel such distances after dispersal from their breeding colonies (B. Robertson, Pers. Comm.).

It has been suggested that lack of available squid, shrimp and small fish

caused by vagaries in the east Australian currents may have caused the penguin mortality examined in this survey. Regular beach patrols along the west central Victorian coastline from 1975 to 1978 have shown that the prevalence of various seabirds washed ashore steadily rose to reach a maximum in 1978. In each year little penguins, short-tailed shearwaters (*P. tenuirostris*) and fairy prions (*Pachyptila turtur*) made up over 70% of all beached seabirds recorded (D. Eades, Pers. Comm.). Reports of significant penguin mortalities were first made in 1977 and 1978 (D. Eades, I. Eberhard, Pers. Comm.). All three of the above mentioned species have major breeding colonies along the Victorian coastline, in Tasmania and on the islands of Bass Strait, and appear to feed in the waters of the Strait during their summer breeding season.

Although a peak in breeding success was achieved in the little penguin colony at Phillip Island, Victoria in 1974-75 (P. Reilly, Pers. Comm.), estimates, based on chicks reared per pair of adult birds and on the number of chicks banded, show that the breeding success of the colony was lower in 1976-77 than for the previous eight breeding seasons (P. Reilly, Pers. Comm.).

Acknowledgements

We wish to acknowledge Dr. R.B. Callinan and Dr. D. Bostock, Veterinary Research Institute, Parkville, for their assistance in the pathological examination of penguins; Dr. J.C. Pearson, Department of Parasitology, University of Queensland, Mrs. P.M. Thomas, Department of Zoology, University of Adelaide, and Mr. M.D. Murray, McMaster Laboratory, Sydney, New South Wales, who identified parasites; Dr. I.H. Eberhard, National Parks and Wildlife Service, Tasmania, and Dr. B.L. Munday, Mt. Pleasant Laboratories, Tasmania who provided information on little penguin mortalities in Tasmania; and Mr. D. Eades, Royal Australian Ornithologist Union, Victoria, and Mrs. P. Reilly and Mr. B. Robertson both of the Victorian Ornithological Research Group, who provided information concerning the little penguin colony at Phillip Island, and data from seabird surveys, respectively.

LITERATURE CITED

1. CATTON, P.E., B.B. BABERO and D. TORRENS. 1976. The helminth fauna of Chile: IV Nematodes of the genera *Anisakis* Dujardin, 1845 and *Phocanema*

The data show that since 1975 there has not only been an apparent increase in seabird mortality (including *E. minor*), but also a decline in the breeding success of the little penguin colony at Phillip Island. These observations give some basis for the general belief that abundance of marine food sources may have been somewhat depleted since 1975.

Increased mortality may have been directly due to starvation or due to exacerbation of the effects of existing parasite burdens on starving and exhausted birds. In the latter case, deaths could be attributed either directly to parasitic lesions (e.g., acute hemorrhagic gastric ulcers), or indirectly to the effects of parasites (e.g., chronic gastric ulcers producing appetite depression and thus exacerbating the lack of food).

Although the survey consisted of only 48 birds, the high prevalence of certain significant necropsy findings in the study sample helps to validate the results and conclusions. Access to a significant number of moribund or freshly dead birds prevented a more extensive or conclusive study. Hopefully, however, this survey will provide a useful foundation for subsequent investigations into penguin mortalities and its effects on the population.

- Myers, 1954 in relation with gastric ulcers in a South American sea lion, *Otaria byronia*. J. Wildl. Dis. 12: 511-515.
2. CROCKETT, D.E. and M.P. KEARNS. 1975. Northern little blue penguin mortality in Northland. Notornis 22: 69-72.
 3. JOHNSTON, D.G. and S.H. RIDGWAY. 1969. Parasitism in some marine mammals. J. Am. vet. med. Ass. 155: 1064-1072.
 4. KEYES, M.C. 1965. Pathology of the northern fur seal. J. Am. vet. med. Ass. 147: 1090-1095.
 5. LIU, S.K. and A.G. EDWARD. 1971. Gastric ulcers associated with *Contraecum* spp. (Nematode: Ascaroidea) in a stellar sea lion and a white pelican. J. Wildl. Dis. 7: 266-271.
 6. MUNDAY, B.L., R.W. MASON, R.J.H. WELLS and J.H. ARUNDEL. 1971. Further studies on 'limey - disease' of Tasmanian mutton birds (*Puffinus tenuirostris*). J. Wildl. Dis. 7: 126-129.
 7. MYKYTOWYCZ, R. and E.R. HESTERMAN. 1957. A note on tick infestation of the fairy penguin, *Eudyptula minor* Forester. CSIRO Wildl. Res. 2: 165-166.
 8. REILLY, P.N. and P. BALMFORD. 1971. Penguin Study Group - Second Report. Australian Bird Bander. 9: 8-10.
 9. SWEENEY, J.C. 1972. Common diseases of pinnipeds. J. Am. vet. med. Ass. 165: 805-810.
 10. WILSON, T.M. and P.H. STOCKDALE. 1970. The harp seal, *Pagophilus groenlandicus* (Erxleben, 1777) XI. *Contraecum* sp. infestation in a harp seal. J. Wildl. Dis. 6: 152-154.

Received for publication 12 July 1979
