



A CASE REPORT OF COCCIDIOSIS CAUSED BY *Eimeria cameli* IN A CAMEL (*Camelus dromedarius*) IN NIGERIA

Author: Chineme, C. N.

Source: Journal of Wildlife Diseases, 16(3) : 377-380

Published By: Wildlife Disease Association

URL: <https://doi.org/10.7589/0090-3558-16.3.377>

BioOne Complete (complete.BioOne.org) is a full-text database of 200 subscribed and open-access titles in the biological, ecological, and environmental sciences published by nonprofit societies, associations, museums, institutions, and presses.

Your use of this PDF, the BioOne Complete website, and all posted and associated content indicates your acceptance of BioOne's Terms of Use, available at www.bioone.org/terms-of-use.

Usage of BioOne Complete content is strictly limited to personal, educational, and non - commercial use. Commercial inquiries or rights and permissions requests should be directed to the individual publisher as copyright holder.

BioOne sees sustainable scholarly publishing as an inherently collaborative enterprise connecting authors, nonprofit publishers, academic institutions, research libraries, and research funders in the common goal of maximizing access to critical research.

A CASE REPORT OF COCCIDIOSIS CAUSED BY *Eimeria cameli* IN A CAMEL (*Camelus dromedarius*) IN NIGERIA

C. N. CHINEME, Department of Veterinary Pathology and Microbiology, Ahmadu Bello University, Zaria, Nigeria.

Abstract: The gross and histopathologic lesions caused by *Eimeria cameli* in the intestinal tract of a camel (*Camelus dromedarius*) are described. Post mortem examination showed lesions in the small intestine which had swollen mucosa on which were numerous whitish-grey foci. Histologically, giant schizonts in various developmental stages were seen in the lamina propria of the jejunum. The associated inflammatory cellular response in these areas was predominantly mononuclear and eosinophilic in character.

INTRODUCTION

Information on the occurrence and pathogenicity of "globidiosis" of the camel is scanty. Henry and Masson⁴ found mature macrogametocytes and a very large, thick-walled immature oocyst which they called *Globidium cameli* in the small intestinal mucosa of a dromedary (*Camelus dromedarius*) in France. Enigk¹ reported a similar parasite in the jejunum and ileum of a camel (*Camelus bactrianus*) in Germany. He described immature and mature schizonts, microgametocytes and large immature oocysts.

The coccidium described by Tsygankov¹⁰ as a new species (*Eimeria kazakhstanica*) was suggested by Levine and Ivens⁶ to correspond with *Eimeria cameli*. Gruvel and Graber (cited by Pellerdy⁷) believed that coccidiosis was and still is an important disease in the Chad Republic where there are large camel herds. *E. cameli* was found in Europe at a post mortem examination of a zoo camel.⁷

The purpose of this report is to document a case of intestinal coccidiosis caused by *E. cameli* in a camel (*C. dromedarius*) from Nigeria.

CASE REPORT

History

A 5-year-old male camel (*Camelus dromedarius*) originally reared in Sokoto was purchased for student teaching at the Faculty of Veterinary Medicine, Ahmadu Bello University, Zaria, Nigeria. The animal developed clinical signs of progressive wasting and was euthanized for post-mortem examination.

Gross Findings

At necropsy, the mucosal surface of the jejunum contained pinhead-sized whitish-grey foci which were more numerous in the distal portion of the organ. The remainder of the small intestine and the entire large intestine showed no such lesion. However, the small and large intestinal mucosae were swollen and reddened. The mesenteric lymph nodes were enlarged and edematous and the body fat together with the coronary fat had become scanty.

Histopathologic Findings

The most significant microscopic changes observed were confined to the jejunal mucosa where large, cyst-like structures and a few immature oocysts

were seen in the lamina propria. These developmental, cyst-like forms measured approximately 240 to 330 μm in diameter and were identified as giant schizonts of *E. cameli*. Some contained either delicate granules or small spherules. They were embedded at varying depths in the mucosa but were predominantly at the base of the mucosa. Each schizont contained a peripherally-located spherical, ovoid or flattened nucleus which is regarded as belonging to the host cell. Schizont development ranged from those in the early formative stage, with small rings of nuclei (Fig. 1) through those bearing parasitophorous vacuoles, to mature schizonts with well-developed merozoites (Fig. 2). None of the schizonts seemed to have released any of the merozoites to the surrounding tissues.

The few oocysts seen in the mucosa measured approximately $60 \times 88 \mu\text{m}$ and had a thick wall, the external layer of which was detached. Each oocyst had a

truncated end with a micropyle that measured approximately 10 to 15 μm . The cellular reaction in the lamina propria of the jejunum was dominated by presence of lymphocytes and eosinophils, with a few macrophages.

DISCUSSION

Most of the findings in the present case agree with those of Henry and Masson.¹ The present finding of loss of condition however contrasted with Enigk's¹ observation of absence of clinical signs in animals infected with *E. cameli*. Even though no survey of coccidiosis in the camel has been reported from Nigeria, Gruvel and Graber² (cited by Pellerdy) asserted that camel mortality from coccidial and other parasitic diseases in the Chad Republic (a close neighbouring country), amounted to 5 to 10%.

The classification of the various protozoan pseudocysts has caused much con-

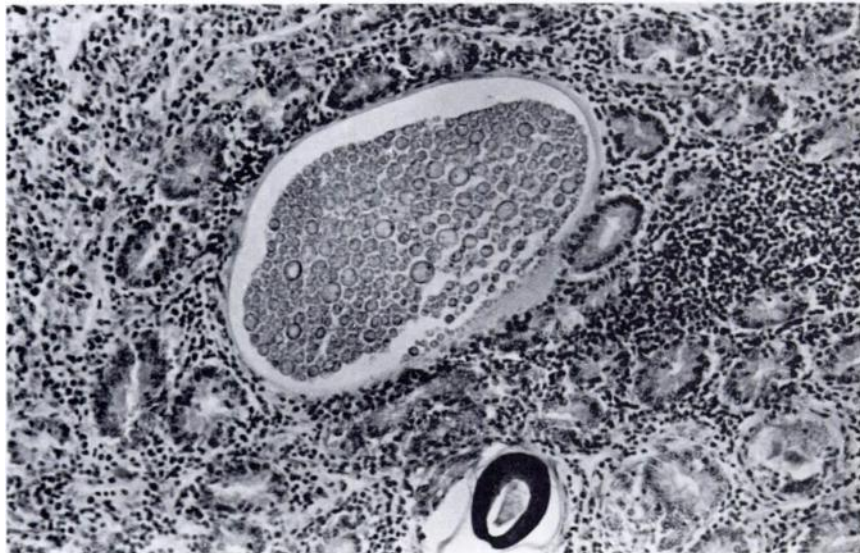

FIGURE 1. Section of the jejunum of a camel showing a schizont of *E. cameli* in the early formative stage - with small rings of nuclei. A thick-walled oocyst lies below the schizont. H&E $\times 100$.

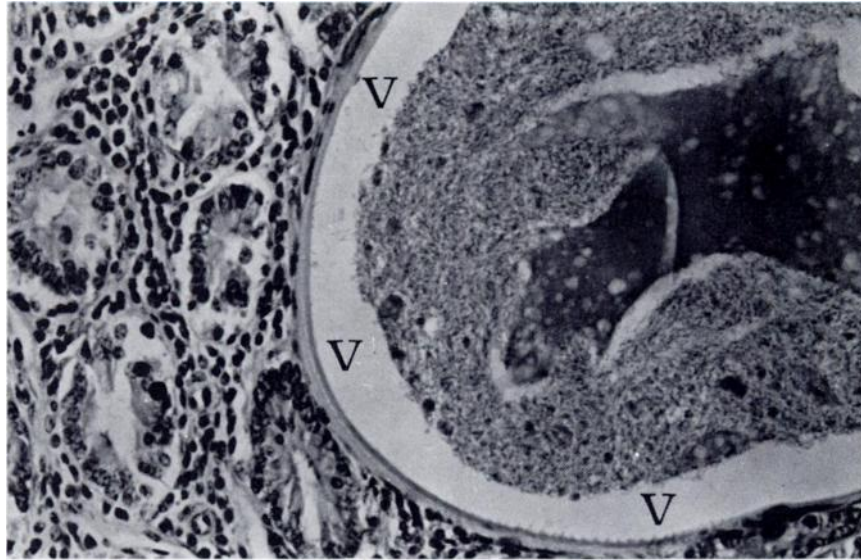


FIGURE 2. Edge of a schizont of *E. cameli* containing clumps of merozoites which surround pink-staining fluid in the center. The space (v) separating the merozoites from the wall of the schizont is a fixation artifact. H&E \times 200.

trovery even among protozoologists. The large macroscopically visible schizonts described in the intestinal tract used to be called "globidia". It is now clear that the intestinal globidia repre-

sent macroschizont development of one or more *Eimeria* spp.^{8,9} Such large schizonts reported here have been described for other *Eimeria* spp. including *E. bovis*³ and *E. gilruthi*.⁵

Acknowledgements

The author thanks Professor J.K. Frenkel of the Department of Pathology and Oncology, University of Kansas Medical Center, Kansas City, Kansas for advice on parasite identification and Mr. S.S. Tulpule of the Department of Veterinary Anatomy, Ahmadu Bello University, Zaria for supplying the specimen.

LITERATURE CITED

1. ENIGK, K. 1934. Zur kenntnis des *Globidium cameli* und der *Eimeria cameli*. Arch. Protistenk. 83: 371-380.
2. GRUVEL, J. and M. GRABER. 1969. (Cited by PELLERDY, L.P. 1974). Coccidia and Coccidiosis. 2nd ed. Akademiai Kiado, Budapest. p. 698.
3. HAMMOND, D.M., G.W. BOWMAN, L.R. DAVIS and B.T. SIMMS. 1946. The endogenous phases of the life cycle of *Eimeria bovis*. J. Parasit. 32: 409-423.
4. HENRY, A. and G. MASSON. 1932. Considerations Sur le genre *Globidium*. *Globidium Camel*. n. sp. parasite du dromedaire. Ann. Parasit. 10: 382-401.
5. LEVINE, N.D. 1973. *Protozoan Parasites of Domestic Animals and Man*. 2nd ed. Burgess Pub. Co., Minneapolis.

6. ——— and V. IVENS. 1970. The coccidian parasites (Protozoa, Sporozoa) of ruminants. Ill. Biol. Monog. #44. pp. 278.
7. PELLERDY, L.P. 1974. *Coccidia and Coccidiosis*. 2nd ed. Akademiai Kiado, Budapest p. 698.
8. REICHENOW, E. 1940. Ueber das Kokzid de Equiden *Globidium leuckarti*. *Ztschr. Infektionskr. der. Haustiere*. 56: 126-134.
9. ———. 1953. *Lehrbuch der Protozoenkunde*. 6th ed. Jena. Gustav. Fisher Verlag.
10. TSYGANKOV, A.A. 1950. Materialy k faune, vozrastnoi i sezonnoi dinamike koktsidii verblyudov v Kazakhstane (Data on the coccidial fauna of camels and their age and seasonal dynamics in Kazakhstan). Author's summary of Candidate Thesis, Alma-Ata.

Received for publication 4 September 1979
