

## **FIBROSING ADENOCARCINOMA OF THE INTESTINE OF A GOPHER SNAKE (*Pituophis melanoleucus*)**

Author: JESSUP, DAVID A.

Source: Journal of Wildlife Diseases, 16(3) : 419-421

Published By: Wildlife Disease Association

URL: <https://doi.org/10.7589/0090-3558-16.3.419>

---

BioOne Complete ([complete.BioOne.org](https://complete.BioOne.org)) is a full-text database of 200 subscribed and open-access titles in the biological, ecological, and environmental sciences published by nonprofit societies, associations, museums, institutions, and presses.

Your use of this PDF, the BioOne Complete website, and all posted and associated content indicates your acceptance of BioOne's Terms of Use, available at [www.bioone.org/terms-of-use](https://www.bioone.org/terms-of-use).

Usage of BioOne Complete content is strictly limited to personal, educational, and non - commercial use. Commercial inquiries or rights and permissions requests should be directed to the individual publisher as copyright holder.

---

BioOne sees sustainable scholarly publishing as an inherently collaborative enterprise connecting authors, nonprofit publishers, academic institutions, research libraries, and research funders in the common goal of maximizing access to critical research.

## FIBROSING ADENOCARCINOMA OF THE INTESTINE OF A GOPHER SNAKE (*Pituophis melanoleucus*)

DAVID A. JESSUP, Wildlife Investigations Laboratory, California Department of Fish & Game, 987 Jedsmith Drive, Sacramento, California 95819, USA.

**Abstract:** Histologic examination of a mass from the intestine of a gopher snake revealed a neoplastic process with an excessively exuberant fibrous component.

### INTRODUCTION

Reports of spontaneous tumors in captive or free-living lower animals are uncommon.<sup>1</sup> Since establishment of the Registry of Tumors in Lower Animals, comparison of tumors and review of the subject have been facilitated. Sclerosing or fibrosing adenocarcinoma of the intestine has not been well described or reported as a cause of death in lower animals. The mucin secreting epithelium appeared to be the origin of this tumor.

### CASE HISTORY

On 9 February 1977, a rubbery ovoid grey mass measuring 3 × 5 cm was removed at postmortem from an adult male gopher snake (*Pituophis melanoleucus*) and submitted for histologic examination. No other tissues were submitted from this animal. Two and one-half months previously, melena had been noticed and symptomatic treatment with kaolin and pectin was instituted. This animal had been in captivity for more than three years. Shortly before death, enlargement of the central one-third of the snake's body was noticed and impaction, possibly due to a kaolin-pectin fecalith, was suspected.

### PATHOLOGY

A cross-section of the ovoid mass revealed a tubular lumen with an irregular surface and thick firm walls. Microscopic examination of hematoxylin and eosin stained sections of the wall revealed

dense sheets of eosinophilic spindle cells, fibrous connective tissue, and randomly scattered islands of glandular epithelial cells (Fig. 1). The cells forming the islands were eosinophilic with small, often flattened nuclei. The cytoplasm and cell walls were indistinct and they formed rings about lumens containing wispy poorly-staining material (Fig. 2). These islands of cells varied in depth, size, and shape but were similar to glandular cells of the distorted and the irregular mucosa. The normal intestinal mucosa was present in only a few areas.

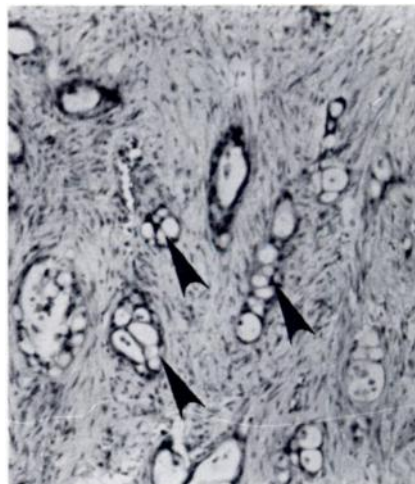


FIGURE 1. Dense sheets of connective tissue and randomly scattered islands of secretory cells (arrows). Hematoxylin and eosin 125×.

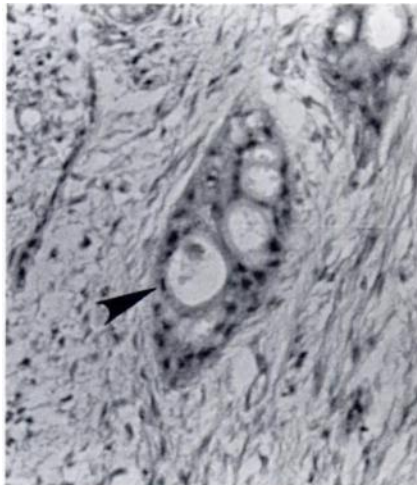


FIGURE 2. Secretory cell island forming a ring about the lumen. Note flattened cells (arrow). Hematoxylin and eosin 2000 $\times$ .

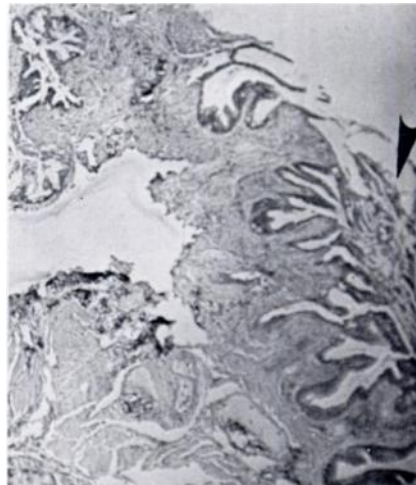


FIGURE 3. Lumen of intestine to right (arrow), distortion and loss of normal tissue relationships of connective tissue and muscular elements in wall. Hematoxylin and eosin 25 $\times$ .

Laminar connective tissue and muscular layers were too distorted by fibrous tissue to recognize and no encapsulation of the process was evident (Fig. 3). Alcian blue stained the glandular cells among the connective tissue and in the lumen (Fig. 4). The mass was diagnosed as a fibrosing or sclerosing adenocarcinoma of mucin secreting epithelial cells.

#### DISCUSSION

A mucinous adenocarcinoma of the colon with splenic metastasis in a Komodo dragon (*Varanus komodoensis*) dying of heart failure was reported to the Tumor Registry of Lower Animals by Montali.<sup>2</sup> In 1954 Wadsworth mentioned, but did not describe, an adenocarcinoma in the intestine of a canebrake rattlesnake (*Crotalus horridus atricaudatus*).<sup>1</sup> The intestinal tumor in this case was of mucinous epithelial origin and incited a marked fibrous response.

Adenocarcinomas of the colon tend to be polypoid while those of the intestine tend to be annular.<sup>3</sup> Although extensive

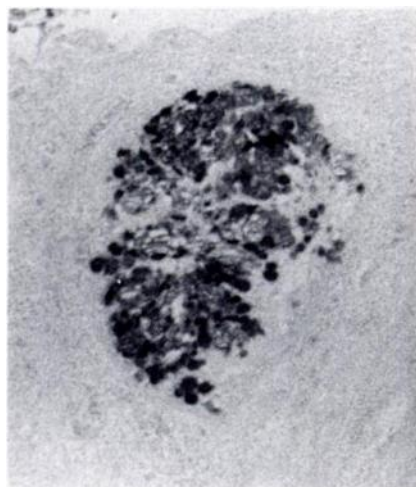


FIGURE 4. Alcian blue staining of glandular cell islands. Alcian blue 1600 $\times$ .

fibrosis associated with intestinal adenocarcinoma is not uncommon, the factors responsible for stimulating that

response have not been isolated. Fecal impaction, egg impaction, and various tumors cause palpable enlargement in the abdominal cavity of snakes. Radiography can supply information that may aid in differentiating these conditions.<sup>4</sup> Adenocarcinoma of the intestine, although uncommon, should be considered as a differential diagnosis in these cases.

#### LITERATURE CITED

1. HARSHBARGER, J.C. 1978. Spontaneous Neoplasms in Reptiles. *Pathology of Laboratory Animals*, Vol. 2, Springer-Verlag, New York.
2. ———. 1973. Registry of Tumors in Lower Animals, Washington, D.C.
3. ROBBINS, S.L. 1974. *Pathologic Basis of Disease*. W.B. Saunders, Philadelphia, Pennsylvania. 941-967.
4. JESSUP, D.A. 1978. Special restraint and radiographic techniques in small exotic animals. *Western Vet.* 16: 8-15.

*Received for publication 14 September 1978*

---