



AVIAN POX INFECTION IN A CANADA GOOSE (*Branta canadensis*)

Author: COX, W.R.

Source: Journal of Wildlife Diseases, 16(4) : 623-626

Published By: Wildlife Disease Association

URL: <https://doi.org/10.7589/0090-3558-16.4.623>

BioOne Complete (complete.BioOne.org) is a full-text database of 200 subscribed and open-access titles in the biological, ecological, and environmental sciences published by nonprofit societies, associations, museums, institutions, and presses.

Your use of this PDF, the BioOne Complete website, and all posted and associated content indicates your acceptance of BioOne's Terms of Use, available at www.bioone.org/terms-of-use.

Usage of BioOne Complete content is strictly limited to personal, educational, and non - commercial use. Commercial inquiries or rights and permissions requests should be directed to the individual publisher as copyright holder.

BioOne sees sustainable scholarly publishing as an inherently collaborative enterprise connecting authors, nonprofit publishers, academic institutions, research libraries, and research funders in the common goal of maximizing access to critical research.

AVIAN POX INFECTION IN A CANADA GOOSE (*Branta canadensis*)

W. R. COX, Department of Pathology, Ontario Veterinary College, Guelph, Ontario, Canada N1G 2W1.

Abstract: Lesions suggestive of Avian Pox were found on a debilitated Canada goose (*Branta canadensis*). These were demonstrated histologically to be characteristic poxvirus lesions and poxvirus particles were seen using electron microscopy. The virus was successfully transmitted to domestic geese but not to leghorn chickens or to domestic ducks.

INTRODUCTION

Natural Avian Pox infection is most commonly known in domestic fowl, where the disease can reach levels of economic importance¹ and is known from a variety of wild birds.⁵ It has been considered, however, to be rare, if not non-existent in wild anatids.^{2,4,7,8} Confirmed⁹ and unconfirmed³ reports of pox in free-living swans (*Cygnus olor* and *Cygnus atratus*) are available, and recently the condition has been identified in a wild green-winged teal (*Anas crecca*).¹⁰ Experimental infection of domestic ducks and domestic geese by fowl poxvirus has been documented⁷ and geese were susceptible to pox of swan origin.⁹

The purpose of this paper is to report a case of naturally occurring pox infection in a Canada goose (*Branta canadensis*), and a brief study of the susceptibility of some experimental hosts to the virus involved.

CASE HISTORY

In August, 1975, a free-flying, mature male Canada goose was found in a debilitated condition and presented to a veterinary clinic in Galt, Ontario. Bacterial enteritis was diagnosed and appropriate therapy instituted. The bird was given to the Ontario Waterfowl Research Foundation in Guelph on 21 August where treatment was continued. The goose appeared to be recovering

when, on 24 August, a swelling was noticed in the left hock region. The bird was found dead on 26 August and submitted for post mortem examination.

MATERIALS AND METHODS

Microscopic Examination

Representative samples of lesions were placed into 10% buffered formalin, embedded in paraffin, sectioned at 6 μ m and stained with hematoxylin and eosin. Paraffin embedded tissue was dewaxed with xylene, rehydrated, postfixed in glutaraldehyde and subsequently processed routinely for electron microscopy.

Egg Inoculation

Supernatant prepared from lesions from the case material and from experimentally infected birds was inoculated onto the chorioallantoic membrane (CAM) of six 12-day old chicken embryos, which were incubated at 37 C for 5 days. The CAM was harvested and similarly re-passaged once through 12-day old chicken embryos.

Transmission Studies

Inoculum prepared from the case material was used in attempts to infect four 8-week old white domestic geese, six 8-week old domestic Pekin ducks, and six 16-week old leghorn chickens. The ducks and geese were inoculated either on the back of the neck or on the volar aspect of the left foot web. Chickens were in-

oculated on the lateral aspect of the right tibio-tarsal joint. The birds were examined periodically for the appearance of lesions. After 4 to 8 weeks, the birds were killed and the inoculated portions of skin were fixed in 10% buffered formalin, processed and tissue sections were examined for evidence of poxvirus infection.

RESULTS

Pathology

The bird was severely emaciated. The left tibio-tarsal joint was swollen. On the plantar aspect of the joint were two raised, firm nodules, each measuring approximately 7 mm diameter and 5 mm thick, which on cut surface were whitish, and glistening. The periarticular soft tissue was edematous and contained three areas with caseous debris. The articular cartilage was coated with fibrin. There was a 5 mm diameter area of necrosis extending 5 mm into the lateral aspect of the proximal tarsus. This contained a bony sequestrum which was easily removed. The kidneys were shrunken and the dorsal one-third of the left kidney was necrotic, being dry, yellowish and firm. There were no significant lesions in other systems. *Pseudomonas aeruginosa* and *Escherichia coli* were cultured from the diseased joint.

Histologically, the skin lesions were characterized by a hyperplastic epidermis consisting of hypertrophied epithelial cells. Large, eosinophilic intracytoplasmic inclusion bodies were present in many of these cells. The kidneys presented large, well demarcated areas of necrosis, the margins of which are separated from the more normal tissue by a thin fibrous tissue layer. At least one organizing venous thrombus could be seen at the periphery of the necrotic area. In other areas of the kidneys there was some amyloid deposition. A diagnosis of septic arthritis with

renal infarction, amyloidosis, and incidental avian pox was made.

Egg Inoculation

Attempts to propagate the virus on chicken embryo CAM failed. Embryos were either killed outright by *P. aeruginosa* contamination, or there was no development of pox lesions.

Transmission studies

No pox lesions were seen on gross or histological examination of the chickens or the ducks. There was a moderate accumulation of mononuclear cells in the inoculated area of the chickens, but no similar reaction could be appreciated in the ducks.

The two geese inoculated in the skin of the neck developed, after 4-6 weeks, small firm raised nodules measuring 2 mm to 5 mm in diameter. Histologically, these areas were found to be associated with feather follicles and consisted of hypertrophied epithelial cells, many with large eosinophilic intracytoplasmic inclusion bodies. Accompanying these lesions were accumulations of mononuclear cells. No cells containing inclusion bodies were present in inoculated footweb. There was, however, an intense mononuclear cell accumulation in the inoculated area.

Electron Microscopy

Typical pox virus particles were seen on electron microscopic examination. They were 325-375 nm in length and 125-250 nm in width. Various shapes were seen, including spherical (empty and full), oval, and disc or biconcave disc (Fig. 1).

DISCUSSION

Although incidental to the cause of death, the Canada goose presented in this case report was infected by a strain of avian poxvirus. The lesions seen on both gross and histological examination were typical for this disease. The diagnosis is supported by the demonstration of poxvirus particles using electron

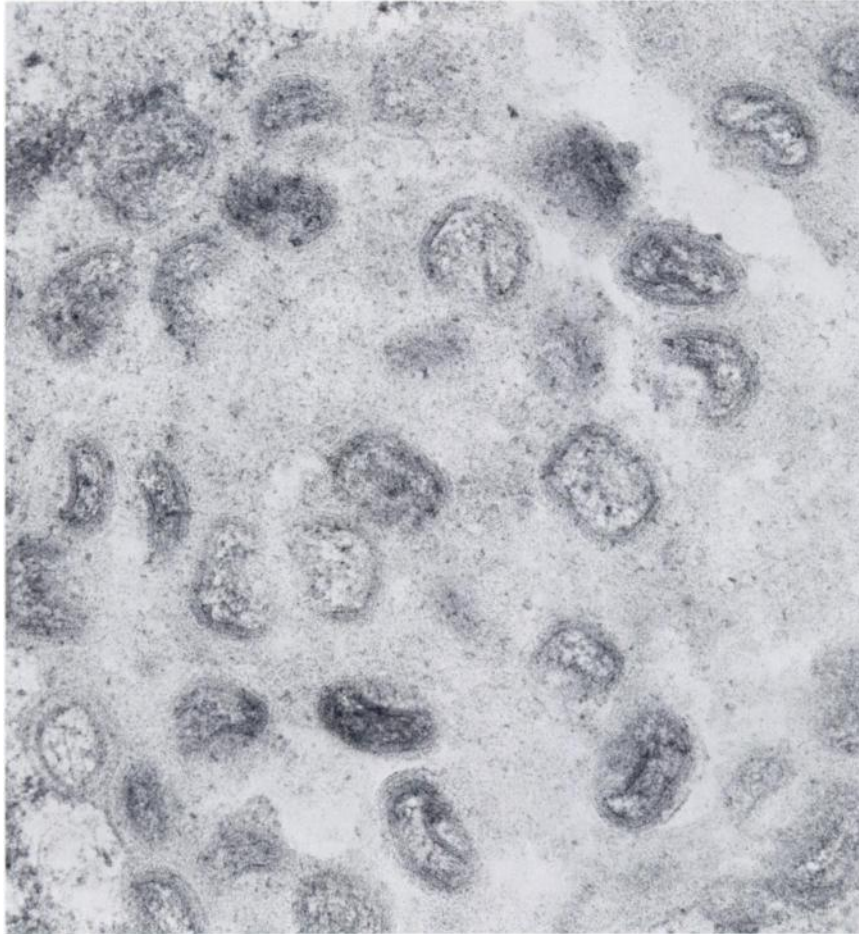


FIGURE 1. Poxvirus particles in the cytoplasm of an hypertrophied epithelial cell from the skin of the Canada goose. $\times 39,560$.

microscopy. The varying shapes of virus particles seen probably represent different developmental stages as described by Tajima and Ushijima.¹¹

Transmission of the disease to domestic geese further supports the diagnosis of avian pox. The inability to

infect other species of birds, however, together with the lack of lesion formation on chick embryo CAM indicates that the virus is highly host specific. Similar results were obtained by Kirmse⁶ with a strain of poxvirus which was highly specific for the yellow-shafted flicker.

Acknowledgements

This study was supported in part by the Ontario Ministry of Natural Resources and the Ontario Ministry of Agriculture and Food. Thanks are extended to Dr. Margaret

Hacking, who performed the bacteriology, Dr. Jan Thorsen, who attempted virus isolation, and Mrs. Carol Skene, who assisted with the electron microscopy. Dr. Ian Barker's assistance and advice in preparing the manuscript is gratefully acknowledged.

LITERATURE CITED

1. BRUNER, D.W. and J.H. GILLESPIE. 1973. *Hagan's Infectious Diseases of Domestic Animals*. 6th ed. Cornell University Press, Ithaca. p. 918-948.
2. CUNNINGHAM, C.H. 1972. Avian Pox. In: *Diseases of Poultry*. 6th ed. M.S. Hofstad, ed. Iowa State Univ. Press, Ames. p. 707-724.
3. HARRIGAN, K.E., I.K. BARKER and M.J. STUDDERT. 1975. Poxvirus infection in the white-backed magpie (*Gymnorhina hypoleuca*) and pox-like conditions in other birds in Australia. *J. Wildl. Dis.* 11: 343-347.
4. HILL, J.R. and G. BOGUE. 1978. Natural pox infection in a common murre (*Uria aalge*). *J. Wildl. Dis.* 14: 337-338.
5. KARSTAD, L. 1971. Pox. In: *Infectious and Parasitic Diseases of Wild Birds*. J.W. Davis, R.C. Anderson, L. Karstad and D.O. Trainer, eds. Iowa State Univ. Press, Ames. p. 34-41.
6. KIRMSE, P. 1967. Host specificity and long persistence of pox infection in the flicker (*Colaptes auratus*). *Bull. Wildl. Dis. Ass.* 3: 14-21.
7. ———. 1967. Experimental pox infection in waterfowl. *Avian Diseases* 11: 209-216.
8. ———. 1967. Pox in wild birds, an annotated bibliography. *Wildl. Dis.* 49.
9. LEIBOVITZ, L. 1969. Natural occurrence and experimental study of pox and *Haemoproteus* infections in a mute swan (*Cygnus olor*). *Bull. Wildl. Dis. Ass.* 5: 130-136.
10. MORTON, J.K. and R.A. DIETERICH. 1979. Avian pox infection in an American Green-winged Teal (*Anas crecca carolinensis*) in Alaska. *J. Wildl. Dis.* 15: 451-453.
11. TAJIMA, M. and T. USHIJIMA. 1966. Electron Microscopy of avian pox viruses with special reference to the significance of inclusion bodies in viral replication. *Jap. J. Vet. Sci.* 28: 107-118.

Received for publication 18 September 1979