

## **MORTALITIES ASSOCIATED WITH HERPESVIRUS INFECTION IN CAPTIVE MACROPODS**

Authors: CALLINAN, R.B., and KEFFORD, B.

Source: Journal of Wildlife Diseases, 17(2) : 311-317

Published By: Wildlife Disease Association

URL: <https://doi.org/10.7589/0090-3558-17.2.311>

---

The BioOne Digital Library (<https://bioone.org/>) provides worldwide distribution for more than 580 journals and eBooks from BioOne's community of over 150 nonprofit societies, research institutions, and university presses in the biological, ecological, and environmental sciences. The BioOne Digital Library encompasses the flagship aggregation BioOne Complete (<https://bioone.org/subscribe>), the BioOne Complete Archive (<https://bioone.org/archive>), and the BioOne eBooks program offerings ESA eBook Collection (<https://bioone.org/esa-ebooks>) and CSIRO Publishing BioSelect Collection (<https://bioone.org/csiro-ebooks>).

Your use of this PDF, the BioOne Digital Library, and all posted and associated content indicates your acceptance of BioOne's Terms of Use, available at [www.bioone.org/terms-of-use](http://www.bioone.org/terms-of-use).

Usage of BioOne Digital Library content is strictly limited to personal, educational, and non-commercial use. Commercial inquiries or rights and permissions requests should be directed to the individual publisher as copyright holder.

---

BioOne is an innovative nonprofit that sees sustainable scholarly publishing as an inherently collaborative enterprise connecting authors, nonprofit publishers, academic institutions, research libraries, and research funders in the common goal of maximizing access to critical research.

## MORTALITIES ASSOCIATED WITH HERPESVIRUS INFECTION IN CAPTIVE MACROPODS

R.B. CALLINAN<sup>□</sup> and B. KEFFORD, Department of Agriculture, Veterinary Research Institute, Park Drive, Parkville, Victoria, Australia, 3052.

**Abstract:** Fatal cases of herpesvirus infection in a quokka (*Setonix brachyurus*), eight grey dorcopsis wallabies (*Dorcopsis muelleri luctuosa*) in two separate outbreaks, as well as presumptive fatal herpesvirus infection in a western grey kangaroo (*Macropus fuliginosus*) are described. All were captive animals and deaths were preceded by a period of stress. Lesions occurred most often in alimentary tract epithelium, respiratory tract, skin, genital epithelium, conjunctivae, liver and adrenal cortex. Herpesviruses were recovered from the quokka and a grey dorcopsis wallaby from each outbreak. The implications, particularly concerning certain apparently susceptible species, for those responsible for the health of macropod collections are discussed.

### INTRODUCTION

There have been several reports of herpesvirus infection involving members of the family Macropodidae. A disease outbreak was described in a group of captive parma wallabies (*Macropus parma*) in which several animals died.<sup>1</sup> A herpesvirus was isolated from a moribund animal and experimental transmission of this virus to parma wallabies caused a similar fatal disease.<sup>6</sup> Munday<sup>4</sup> reported a possible herpesvirus infection in a red kangaroo (*M. rufus*) and potoroo (*Potorous apicalis*). Webber and Whalley<sup>6</sup> mentioned an outbreak of disease in a group of captive tammar wallabies (*M. eugenii*), clinically and serologically consistent with herpesvirus infection. They examined sera from a wide range of native Australian marsupials for serum neutralizing (SN) antibodies to the parma wallaby herpesvirus (PWHV) and showed evidence of widespread infection in wild and captive populations by this or a closely related herpesvirus.

In a brief report, Spence<sup>5</sup> described a devastating outbreak of herpesvirus in-

fection in which all the members of a breeding colony of brush-tailed rat kangaroos (*Bettongia penicillata*), consisting of eight adults and their pouch young, died over a 3 day period. Eleven rufous rat kangaroos (*Aepyprymnus rufescens*), the entire population of a neighbouring pen, also died. A contiguous colony of rufous rat kangaroos was not affected.

This paper describes cases of herpesvirus infection in a quokka (*Setonix brachyurus*) and in two geographically isolated groups of grey dorcopsis wallabies (*Dorcopsis muelleri luctuosa*) as well as a case of presumptive herpesvirus infection in a western grey kangaroo (*Macropus fuliginosus*).

### MATERIALS AND METHODS

#### Pathology

Necropsies were performed on one quokka, eight grey dorcopsis wallabies and one western grey kangaroo. Representative tissue samples from major organs and sites showing gross lesions were fixed in 10% neutral buffered

<sup>□</sup> Current address: NSW Dept. of Agriculture, Regional Veterinary Laboratory, Wollongbar, NSW 2480, Australia.

formaldehyde solution for routine histological processing. Paraffin embedded sections were stained with haematoxylin and eosin.

#### Bacteriology

Routine aerobic bacteriological examinations were conducted, using inocula from selected organs in each case. Sites cultured were lung, liver, kidney, spleen, brain, small and large intestines, mesenteric lymph node and conjunctiva.

#### Mycology

Routine direct examinations and cultures were conducted, using inocula from oesophageal and stomach lesions in the western grey kangaroo.

#### Virology

In outbreak 1, virus isolation attempts were made from lung, kidney and spleen of a grey dorcopsis wallaby. In outbreak 2, brain, kidney, liver, lung, mesenteric lymph node and spleen from one animal were cultured. Pooled liver and kidney were cultured from the quokka.

Cell cultures used were primary chicken embryo fibroblasts (PCEF) established from 9-day old embryonated chicken eggs and potoroo kidney cells<sup>[2]</sup> (PtK2). PCEF cells were grown in Medium 199<sup>[2]</sup> supplemented with 2-10% foetal calf serum and PtK2 cells were grown in Eagle's (Dulbecco Modified) medium<sup>[2]</sup> supplemented with 5-10% foetal calf serum. All media contained penicillin (100 IU/ml and streptomycin (100 µg/ml).

Tissue obtained during necropsy was macerated in Hank's balanced salt solution (HBSS) with penicillin (1000 IU/ml) and streptomycin (1000 µg/ml) to produce a 10% w/v suspension. This suspension was centrifuged and supernatant fluid was inoculated onto tissue cultures. Initial virus isolation from outbreak 1 dorcopsis wallabies was made

using PCEF cells and subsequent passages were carried out on PtK2 cells. The isolation and all subsequent passages of quokka virus and outbreak 2 dorcopsis wallaby virus were carried out using PtK2 cells.

Stock virus samples were prepared using standard techniques and stored in liquid nitrogen. Virus titrations and ether and chloroform sensitivities were carried out using standard microtitre techniques. Presumptive evidence of nucleic acid type was obtained using the indirect method of McFerran *et al.*<sup>3</sup>

Cells from cultures infected with the virus and showing extensive CPE were scraped into the supernatant fluid and sonicated. Debris was removed by centrifuging at 800 g for 20 min. The supernatant fluid was centrifuged at 10,000 g for 30 min and finally at 80,000 g for 60 min. The resultant pellet was resuspended in 0.05 M phosphate buffer (pH 7.2) stained with 4% phosphotungstic acid (pH 7) and applied to a carbon-coated grid for electron microscopic examination.

## RESULTS

### Case Reports

During the winter of 1978, three grey dorcopsis wallabies and one quokka held in a zoo collection in suburban Melbourne were submitted to this Institute for necropsy. In the winter of 1979, a western grey kangaroo from the zoo collection and five grey dorcopsis wallabies from a fauna park 60 km from Melbourne were also submitted for necropsy.

**Grey Dorcopsis Wallabies.** Outbreak 1 (1978). Seven grey dorcopsis wallabies of mixed ages and sexes were introduced to an enclosure with black tail wallabies (*Wallabia bicolor*) and grey

<sup>[2]</sup> Commonwealth Serum Laboratories, Parkville, Victoria.

kangaroos (*M. fuliginosus* and *M. giganteus*). Over the next 3 to 5 weeks, five grey dorcopsis wallabies died. Two were subsequently found to have died from bacterial infections and will not be discussed further. The other three died 12 to 24 h after being found moribund.

**Outbreak 2 (1979).** Seven grey dorcopsis wallabies were kept in a mixed exhibit of parma wallabies, tamar wallabies, red necked wallabies (*M. rufogriseus*) and red bellied pademelons. Over a one week period, five grey dorcopsis wallabies (three mature males, one mature female and one weaned immature female) were found moribund and died within 24 h. Prior to death, some showed reddening of the mucous membranes of the mouth, cloaca, conjunctiva and skin, particularly around the mouth.

**Quokka.** An adult male recently moved to a new enclosure with two adult females, developed conjunctivitis. The animal was moved to a treatment centre where it remained for 1 month, during which time the conjunctivitis persisted. It was found dead 1 day after vesicles were noted on the mucosa of the mouth and cloaca.

**Western Grey Kangaroo.** A seven month old orphan donated to the zoo became dyspnoeic and dehydrated 2 days after receipt. It was given parenteral electrolytes and antibiotics, but died the following day.

#### Gross Pathology

**Grey Dorcopsis Wallabies.** (Outbreaks 1 and 2) Findings were similar in both groups of animals. Lesions were seen in lungs, liver, gastro-intestinal tract, conjunctivae and vagina. Lungs in all animals were firm and red with irregular dark red oedematous areas up to 2 cm diameter throughout the parenchyma. Smaller airways often contained pale froth. Livers showed scattered yellow foci up to 1 mm diameter visible beneath the capsule and on the cut surface. The mucosa of the sacculated part of the stomach showed widespread

irregular red areas 1 to 4 mm diameter, often with a central grey plaque up to 3 mm in diameter. In the small and large intestinal mucosa numerous brown, soft irregular areas up to 5 mm diameter were present and could be easily removed to reveal a red base. Irregular red sub-serosal areas corresponding to mucosal lesions were visible throughout the gastro-intestinal tract. Mesenteric lymph nodes were enlarged, red and oedematous. In some animals there was patchy reddening of the conjunctivae with some associated yellow exudate. One animal showed several eroded red areas about 2 mm diameter in the vagina.

**Quokka.** There was a bilateral purulent conjunctival exudate. The lips and gingivae were redder than normal, and the cloaca was swollen and reddened. Patchy, yellow plaques overlaid much of the reddened penile and preputial epithelium. The lungs were congested and oedematous with numerous dark red foci up to 1 mm diameter beneath the pleura and with lesser numbers on the cut surface. Some smaller airways contained pale pasty material. There was excess, slightly red abdominal fluid. The sacculated part of the stomach showed numerous irregular pale foci up to 1 mm diameter each surrounded by a red halo.

**Western Grey Kangaroo.** Diphtheritic, white plaques were irregularly distributed on the mucosa of the oesophagus and the oesophageal region of the stomach. The stomach was distended by a frothy mucoid material suggesting that the animal had swallowed copious amounts of saliva, while the lung and liver lesions were similar to those in the dorcopsis wallabies.

#### Bacteriology and Mycology

No significant bacteria were recovered from sites cultured and no fungi were recovered from cultures of oesophageal and stomach lesions in the western grey kangaroo.

### Histopathology

The basic lesion was disseminated focal necrosis. Usually nests of cells showed vacuolar degeneration, often with intranuclear acidophilic or basophilic inclusion bodies. Necrosis of these cells followed, with extension of the process to surrounding cells leading to disintegration and partial to complete loss of local normal tissue structure. Haemorrhage was often associated with necrotic areas, but inflammation was usually absent or slight with accumulations of mononuclear cells at the periphery of necrotic foci.

Bronchiolar epithelium often showed focal necrosis with eventual detachment of sheets of necrotic cells. The lesion often extended to involve elements of the underlying bronchiolar wall and adjacent parenchyma. The basic parenchymal lesion consisted of swelling of alveolar septa, focal necrosis of

alveolar and interstitial cells, occasional inclusion body formation and exudation of proteinaceous fluid and haemorrhage into alveoli. In some animals, a moderately intense neutrophil infiltrate developed in affected areas. Lung in all cases showed a low grade interstitial pneumonia. Necrotic foci usually occurred in parenchyma adjacent to portal areas in the liver. Many hepatocyte nuclei at the margins of these foci contained basophilic inclusion bodies, whereas more acidophilic inclusions usually were present in nuclei of the neighbouring degenerating biliary epithelial cells (Figure 1). Lesions in the stratified epithelium of oesophagus, oesophageal stomach, cloaca, skin, external genital epithelium and conjunctiva, were essentially similar and their development followed the general pattern described (Figure 2). Ulceration usually was the end result. In the cardiac glandular region of the stomach and in

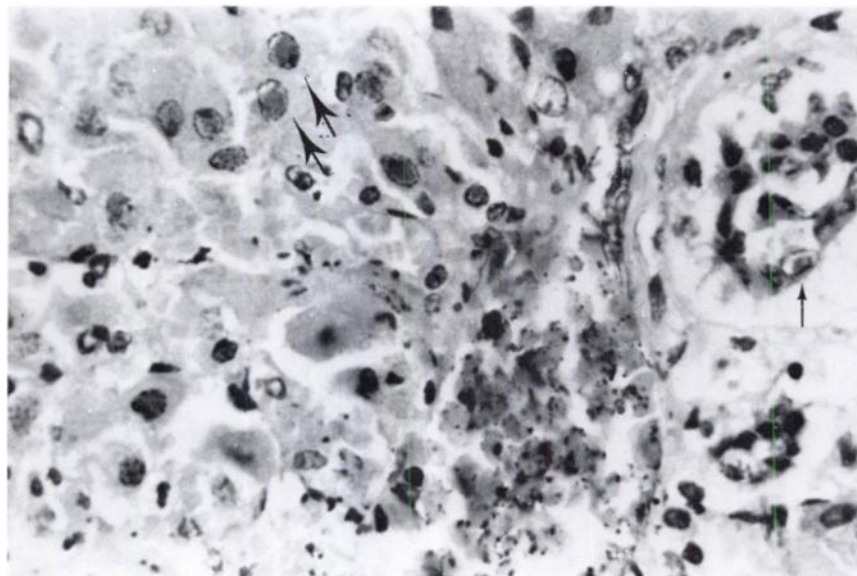


FIGURE 1. Grey dorcopsis wallaby. Margin of necrotic focus in liver. Intranuclear inclusion bodies are visible in hepatocytes (thick arrows) and biliary epithelial cell (thin arrow)  $\times 400$ .

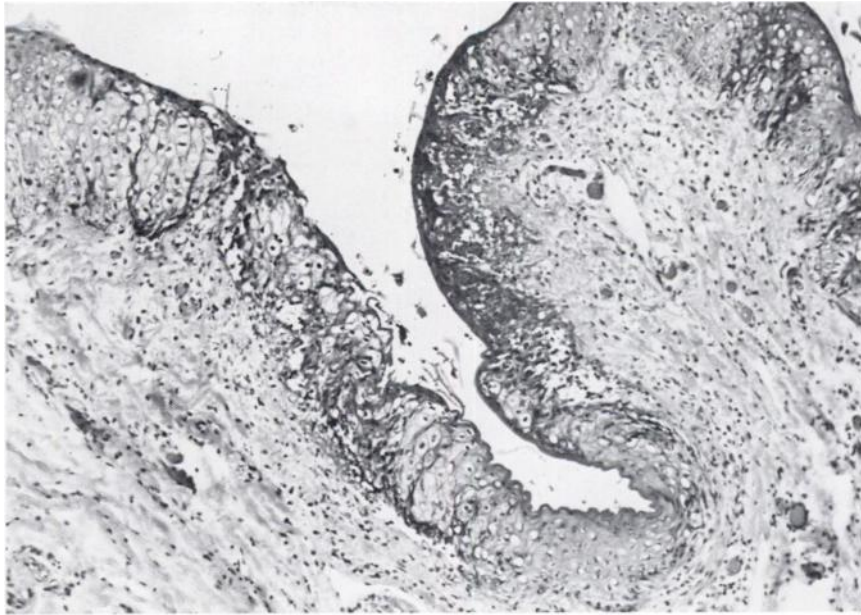


FIGURE 2. Quokka. Areas of epithelial degeneration and necrosis in cloacal skin  $\times$  100.

the intestines, foci of necrosis first appeared in the lamina propria associated with degenerative changes and inclusion body formation in neighbouring epithelial cells. As the necrotic lesions enlarged, mononuclear cells and polymorphs infiltrated adjacent areas. Eventually, in many areas, the entire depth of the mucosa became necrotic and the underlying submucosa usually showed marked congestion, haemorrhage and inflammatory cell infiltration. Foci of necrosis occurred in the splenic red pulp and adrenal cortex in dorcopsis wallabies. Their development followed the general pattern described. The distribution and frequency of necrotic lesions in various organs is summarized in Table 1.

#### Virology

**Outbreak 1.** A CPE typical of a herpesvirus, with foci of rounded refrac-

tile cells developing progressively into plaques, developed 24 to 48 h after inoculation of PCEF cultures with lung material. No CPE developed in cultures inoculated with spleen and kidney material.

**Outbreak 2.** A typical herpesvirus CPE developed 48 to 72 h after inoculation of PtK2 cell cultures with material from liver, lung, spleen and mesenteric lymph node, but not brain or kidney.

**Quokka.** A typical herpesvirus CPE developed after 72 h in PtK2 cell cultures inoculated with material from pooled liver and kidney.

In each case, monolayers showing CPE, after staining with haematoxylin and eosin, revealed eosinophilic intranuclear inclusions and syncytia similar to those described by Finnie *et al.*<sup>1</sup> The cytopathic agents were ether and chloroform sensitive and their nucleic acids were assumed to be DNA, as 5-

TABLE 1. Distribution and frequency of necrotic foci in affected animals.

	Grey Dorcopsis Wallaby	Quokka	Western Grey Kangaroo
Skin	+	+++	NE
Conjunctiva	+	+++	NE
Genital epithelium	+	+++	NE
Spleen	+	—	—
Adrenal cortex	++	—	NE
Intestines	+++	—	NE
Cardiac glandular stomach	+++	+++	NE
Oesophageal stomach	—	NE	+++
Oesophagus	NE	NE	+++
Liver	+++	+++	+
Pulmonary parenchyma	+++	—	+++
Bronchiolar epithelium	+++	+++	+++

+++ numerous necrotic foci

++ moderate numbers of necrotic foci

+ few necrotic foci

— no necrotic foci

NE not examined histologically, no gross lesions.

bromodesoxyuridine inhibited the development of CPE almost entirely (i.e. 1% of the CPE of the controls).

#### Electron Microscopy

In each case, preparations of infected cell cultures showed enveloped particles typical of herpesviruses with naked virion diameters of 115 to 125 nm.

#### DISCUSSION

Disease resulting from herpesvirus infection is emerging as the cause of significant losses in collections of captive macropods. In this report, mortalities in a quokka, a western grey kangaroo and in two separate groups of grey dorcopsis wallabies are described. All showed disseminated focal necrotic lesions consistent with herpesvirus infection and herpesviruses were isolated from the quokka and a dorcopsis wallaby in each group. Virus isolation from the grey kangaroo was not attempted.

It seems likely that both wild and captive macropod populations are infected with herpesviruses which may

have evolved in association with marsupial hosts. In crowded captive conditions, virus may be spread to uninfected animals from carrier species or from other species in which the stress associated with captivity has allowed expression of latent virus infection. There is evidence that certain species in captivity are likely to develop serious disease following infection. Tamar wallabies at Macquarie University appeared to be the species most susceptible to outbreaks of disease associated with raised SN antibody levels to PWHV.<sup>6</sup> The occurrence of temporally and geographically separate disease outbreaks in two groups of grey dorcopsis wallabies also supports this contention, especially as the species is one not commonly held in captivity (G. George, pers. comm.).

One hundred percent mortality in neighbouring groups of brush-tailed kangaroos and rufous rat kangaroos has been reported,<sup>5</sup> suggesting that these species also may be particularly susceptible. Lesions due to herpesvirus infection were most severe in livers and lungs.

Herpesvirus infection may be transmitted by the airborne route in respiratory infections.<sup>2</sup> In this outbreak there was opportunity for the infection of an additional group of rufous rat kangaroos in a contiguous pen. However, these animals remained unaffected indicating that better understanding is needed of the disease determinants operating in herpesvirus infection of macropods.

At present, efforts to keep the disease prevalence low must be directed mainly at providing optimal environments, in order to minimize stress, particularly for those species thought to be more susceptible. Further study of the relationships between virus isolates is required. Possibly some attention should be given to vaccine development so that endangered and valuable captive species may be protected.

#### Acknowledgements

We wish to acknowledge the contribution of several members of staff at the Veterinary Research Institute, Parkville. Special thanks are due to Dr. W.M. Forsyth for permission to include material from his initial diagnosis of the disease in dorcopsis wallabies. We also wish to thank Dr. K. McColl for his contribution to the pathological examinations and Dr. C. Wilks and Dr. R. Borland for their advice and assistance.

We are grateful to Dr. R. Butler, Royal Melbourne Zoological Gardens and to Dr. P. Whitely, Sir Colin McKenzie, Fauna Park, Healesville, for providing clinical histories and for submitting cases to us. Thanks are due also to Dr. R. Garret, Plant Research Institute, Burnley, for carrying out the electron-microscopy.

The excellent technical assistance of Mr. D. Grix, Mrs. J. Slattery, Mr. M. Kotiw and Mr. W. Djordjevic is acknowledged.

#### LITERATURE CITED

1. FINNIE, E.P., I.R. LITTLEJOHNS and H.M. ACLAND. 1976. Mortalities in parma wallabies (*Macropus parma*) associated with probable herpesvirus. *Aust. vet. J.* 52: 294.
2. MARTIN, W.B. 1976. The herpesviruses. *Vet. Rec.* 99: 352-354.
3. McFERRAN, J.B., J.K. CLARK and T.J. CONNOR. 1972. Serological classification of avian adenoviruses. *Archiv. ges. Virusforsch.* 39: 132-139.
4. MUNDAY, B.L. 1978. Marsupial disease. In: Proc. No. 36 of Course for Veterinarians. Fauna-Part B. Postgraduate Committee in Vet. Sci. Univ. of Sydney.
5. SPENCE, T. 1979. Annual Report, Zoological Gardens Board, Perth, Western Australia. Wescolour Press. p. 16.
6. WEBBER, C.E. and J.M. WHALLEY. 1978. Widespread occurrence of neutralising antibodies to a herpesvirus from a parma wallaby. *Aust. J. exp. Biol. med. Sci.* 56: 351-357.

*Received for publication 20 May 1980*