



Plasmodium IN A BALD EAGLE (*Haliaeetus leucocephalus*) IN FLORIDA 1

Authors: GREINER, ELLIS C., BLACK, DAVID J., and IVERSONE, WILLIAM O.

Source: Journal of Wildlife Diseases, 17(4) : 555-558

Published By: Wildlife Disease Association

URL: <https://doi.org/10.7589/0090-3558-17.4.555>

BioOne Complete (complete.BioOne.org) is a full-text database of 200 subscribed and open-access titles in the biological, ecological, and environmental sciences published by nonprofit societies, associations, museums, institutions, and presses.

Your use of this PDF, the BioOne Complete website, and all posted and associated content indicates your acceptance of BioOne's Terms of Use, available at www.bioone.org/terms-of-use.

Usage of BioOne Complete content is strictly limited to personal, educational, and non - commercial use. Commercial inquiries or rights and permissions requests should be directed to the individual publisher as copyright holder.

BioOne sees sustainable scholarly publishing as an inherently collaborative enterprise connecting authors, nonprofit publishers, academic institutions, research libraries, and research funders in the common goal of maximizing access to critical research.

***Plasmodium* IN A BALD EAGLE (*Haliaeetus leucocephalus*) IN FLORIDA**¹

ELLIS C. GREINER,² DAVID J. BLACK³ and WILLIAM O. IVERSON⁴

Abstract: An injured mature bald eagle (*Haliaeetus leucocephalus*) was submitted for treatment of gunshot wounds. Parasites resembling *Plasmodium polare* were detected in the peripheral blood during routine examination. The eagle died from a bacteremia secondary to necrotizing osteomyelitis. Due to the severity of the eagle's wounds, it was impossible to assess the impact of *Plasmodium* on the deterioration of the eagle's condition.

INTRODUCTION

Many infectious agents of both free ranging and captive raptors have been identified and characterized.⁷ Included among them are hematozoon infections caused by species of *Haemoproteus*, *Leucocytozoon*, *Plasmodium*, *Trypanosoma*, *Babesia* or *Hepatozoon*.^{2,4,7,11} *Plasmodium relictum* has been reported in peregrine falcons and gyrfalcons,⁸ kestrels,¹⁰ as well as other Falconiformes and Strigiformes^{9,11} in the United States. To date, there have been no reports of hemosporidian infections in the bald eagle, *Haliaeetus leucocephalus*. This communication reports a diagnosis of *Plasmodium* in a bald eagle in Florida.

CASE HISTORY

A mature male bald eagle was brought to the University of Florida, College of Veterinary Medicine Teaching Hospital, on 2 October 1978 for treatment of injuries and debilitation. The eagle, which weighed 4.5 kg on admission, was found

along a road in north central Florida. Physical examination and radiographic examinations revealed that the bird had extensive soft tissue damage due to the invasion of maggots into gunshot wounds. The injuries were surgically debrided, and the eagle received both topical and systemic antibiotics. On 27 November 1978 as part of routine treatment, the eagle was anesthetized with ketamine HCl and a sample of blood was taken from the alar vein for a complete blood count. Intracellular inclusions resembling parasites were noted in the erythrocytes during the cell counting procedure. On 6 December 1978, the eagle was again anesthetized for purposes of medical treatment, and a series of blood smears was made and stained with Giemsa. The eagle died from a bacteremia secondary to necrotizing osteomyelitis on 8 December 1978.

A post mortem examination was performed. Tissues were fixed in 10% buffered formalin and processed for microscopic examination and stained

¹ Florida Agricultural Experiment Stations Journal Series No. 2996.

² Department of Preventive Medicine, College of Veterinary Medicine, University of Florida, Gainesville, Florida 32610, USA.

³ Division of Laboratory Animal and Wildlife Medicine, Department of Special Clinical Sciences, College of Veterinary Medicine, University of Florida, Gainesville, Florida 32610, USA.

⁴ Division of Comparative Pathology, College of Veterinary Medicine, University of Florida, Gainesville, Florida 32610, USA. Present address: Experimental Pathology Lab. Inc., P.O. Box 474, Herden, Virginia 22070, USA.

with hemotoxylin and eosin, as well as Giemsa.

RESULTS

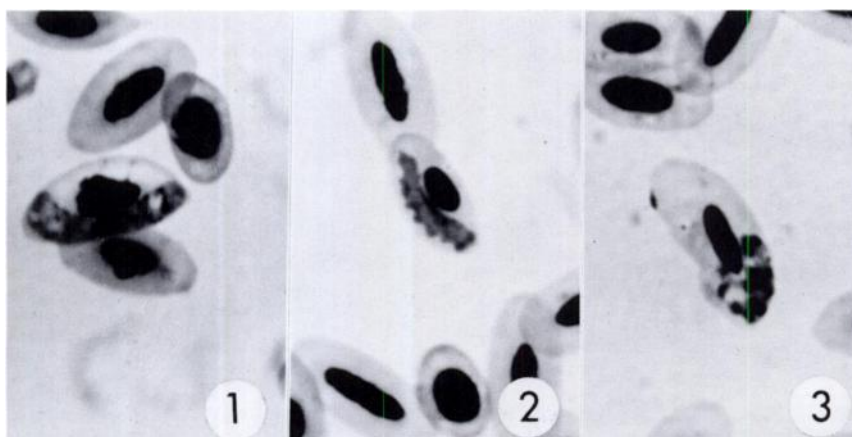
On examination of blood smears, two types of intracellular gametocytes were observed. They were usually a little shorter than the erythrocytes in which they were located and infrequently were wrapped slightly around the poles of the host cell nucleus. The first type (Fig. 1) filled the available space between the erythrocyte (RBC) nucleus and RBC membrane, whereas the periphery of the second type (Fig. 2) of gametocyte was usually scalloped. Whether these two forms represent normal and senescent types of the same parasite or separate taxa remains an enigma. The mean number of pigment granules in the microgametocytes was 8.8 (5 to 11) and 9.2 (5 to 14) in the macrogametocytes. No discernible difference was noted in the pigment size, number, or distribution between the two morphological forms.

Stained gametocytes revealed normal sexual dimorphism.

Erythrocytic schizonts (Fig. 3) were usually polar to sub-polar, rarely lateral, and with few exceptions, were irregular in shape. A few were elongate. Merozoites numbered 8 to 14 with a mean of 11.3. Pigment granules were clustered into one mass, indicating the presence of single parasites instead of multiple infections. Occasionally, schizonts were in immature cells of the erythroid series, but most appeared in mature erythrocytes. Infected erythrocytes did not appear to be hypertrophied, nor was the host cell nucleus displaced. Sections of spleen, liver, lung, kidney, and brain were examined microscopically for the presence of exoerythrocytic schizonts. None was found.

DISCUSSION

Bennett and Woodworth-Lynas³ recorded the following species of *Plasmodium* from Falconiformes in their



Parasites seen in mature erythrocytes of bald eagle.

FIGURE 1. Macrogametocyte filling the space between the RBC nucleus and the RBC limiting membrane.

FIGURE 2. Macrogametocyte with scalloped periphery.

FIGURE 3. Erythrocytic schizont containing 12 merozoites and a single cluster of pigment granules.

host-parasite catalogue: *P. circumflexum*, *P. elongatum*, *P. fallax*, *P. hexamerium*-like, *P. lophurae*, *P. polare*, *P. praecox*, *P. relictum* and *P. subimmaculatus*. The blood stage morphologies of *P. relictum*, *P. praecox* and *P. subimmaculatus* include round gametocytes,⁶ unlike those seen in the bald eagle. The circulating schizonts of *P. elongatum* are not in mature erythrocytes⁶ whereas the majority in the present infection were in mature RBCs. The erythrocytic schizonts were equal to or larger than the parasitized host cell nucleus, ruling out *P. hexamerium*; those of *P. circumflexum*, *P. lophurae* and *P. fallax* are elongate⁶ whereas in the eagle elongate schizonts were the exception.

The aforementioned characteristics most closely resemble *Plasmodium polare* Manwell, 1934. Some of the schizonts in the eagle were larger than those normally attributed to *P. polare*, but most were very similar. The number of merozoites per erythrocytic schizont was correct for *P. polare*.⁶ The gametocytes of *P. polare* are reported to be similar to *Haemoproteus*, normally thick forms filling the available host cell cytoplasm. Because this is the first report of any hematozoan from the bald eagle, however, we do not know what host-induced morphological changes might be

expected or what influence the host's compromised physiologic state might impose.

Garnham⁵ points out how little we know about the distribution of *P. polare*, mentioning only the type host (cliff swallows, *Petrochelidon pyrrhonota*) and a report from falcons in Sicily. It has been reported in ducks from North America in recent studies conducted in Canada² and in two general blood surveys in birds.^{1,12} Unfortunately, the latter two studies did not indicate which hosts were infected with *Plasmodium polare*, but the infected birds were not Falconiformes.

A diagnosis of *P. polare* was made based on the observations of characteristics typical of *P. polare* in the intraerythrocytic organisms present in the blood smear. Unfortunately, the eagle died before blood could be obtained for attempted xenodiagnosis. Blood smears were deposited (Accession #68665) in the International Reference Centre for Avian Haematozoa, Memorial University of Newfoundland.

Due to the severity of the eagle's wounds, and the resultant complications, it is impossible to state what effect, if any, the *P. polare* infection had on the clinical course. However, this report clearly indicates that bald eagles are susceptible to hematozoan infections.

Acknowledgements

We thank Jim Ellis and his staff at the Sante Fe Community College Zoo, Gainesville, Florida, for their assistance and cooperation in housing and caring for the eagle.

LITERATURE CITED

1. BENNETT, G.F., M. CAMERON and E. WHITE. 1975. Hematozoa of the passeriforms of the Tantramer Marshes, New Brunswick. *Can. J. Zool.* 53: 1432-1442.
2. ———, A.D. SMITH, W. WHITMAN and M. CAMERON. 1975. Hematozoa of the Anatidae of the Atlantic Flyway. II. The Maritime Provinces of Canada. *J. Wildl. Dis.* 11: 280-289.

3. ———, and C.B. WOODWORTH-LYNAS. 1981. A host-parasite catalogue of the avian haematozoa. Memorial University of Newfoundland Occasional Papers in Zoology, #4 (in press).
4. R.E. CROFT and N. KINGSTON. 1975. *Babesia moshkovskii* (Schurenkova, 1938) Laird and Lari, 1957; from the prairie falcon, *Falco mexicanus*, in Wyoming; with comments on other parasites found in this host. *J. Wildl. Dis.* 11: 229-233.
5. GARNHAM, P.C.C. 1966. *Malaria Parasites and Other Haemosporidia*. Blackwell Scientific Publications. Oxford. 1114 pp.
6. GREINER, E.C., G.F. BENNETT, M. LAIRD and C.M. HERMAN. 1975. Avian Haematozoa. 2. Taxonomic Keys and color pictorial guide to the species of *Plasmodium*. *Wildl. Dis.* 68: 55 pp.
7. KEYMER, I.F. 1972. Diseases of birds of prey. *Vet. Rec.* 90: 579-594.
8. KINGSTON, N., J.D. REMPLE, W. BURNHAM, R.M. STABLER and R.B. MCGHEE. 1976. Malaria in a captively-produced F₁ Gyrfalcon and in two F₁ Peregrine Falcons. *J. Wildl. Dis.* 12: 562-565.
9. KOCAN, A.A., J. SNELLING and E.C. GREINER. 1977. Some infectious and parasitic diseases in Oklahoma raptors. *J. Wildl. Dis.* 13: 304-306.
10. STABLER, R.M. and R.J. DATEL. 1959. First record of malaria in American falcons (*Falco sparverius*). *J. Colo-Wyo Acad. Sci.* 4: 59.
11. ———, and P.A. HOLT. 1965. Hematozoa from Colorado birds. II. Falconiformes and Strigiformes. *J. Parasit.* 51: 927-928.
12. WILLIAMS, N.A. and G.F. BENNETT. 1978. Hematozoa of some birds of New Jersey and Maryland. *Can. J. Zool.* 56: 596-603.

Received for publication 20 March 1981