



MULTIPLE PRIMARY TUMORS IN A FENNEC FOX (FENNECUS ZERDA)

Authors: GRAY, KENNETH N., HARWELL, GARY, and TSAI, C.C.

Source: Journal of Wildlife Diseases, 18(3) : 369-371

Published By: Wildlife Disease Association

URL: <https://doi.org/10.7589/0090-3558-18.3.369>

BioOne Complete (complete.BioOne.org) is a full-text database of 200 subscribed and open-access titles in the biological, ecological, and environmental sciences published by nonprofit societies, associations, museums, institutions, and presses.

Your use of this PDF, the BioOne Complete website, and all posted and associated content indicates your acceptance of BioOne's Terms of Use, available at www.bioone.org/terms-of-use.

Usage of BioOne Complete content is strictly limited to personal, educational, and non - commercial use. Commercial inquiries or rights and permissions requests should be directed to the individual publisher as copyright holder.

BioOne sees sustainable scholarly publishing as an inherently collaborative enterprise connecting authors, nonprofit publishers, academic institutions, research libraries, and research funders in the common goal of maximizing access to critical research.

MULTIPLE PRIMARY TUMORS IN A FENNEC FOX (*FENNECUS ZERDA*)

KENNETH N. GRAY,[□] GARY HARWELL,[□] and C.C. TSAI[□]

Fennec foxes are native to the deserts of North America and the Arabian and Sinai peninsulas, where they are among the most common mammals. They live in burrows in sandy soil and are nocturnal. This report describes the occurrence of multiple primary tumors in an aged fennec fox.

A 16-yr-old female fennec fox, weighing 4 kg, and belonging to the Houston Zoo, was presented to the Division of Veterinary Medicine and Surgery, The University of Texas System Cancer Center, to be evaluated for cancer chemotherapy. An oral mass located posterior to the last left upper molar tooth had been surgically excised and histopathologically diagnosed as malignant melanoma. Apparent melanoma metastasis to the left submandibular lymph node and a mass in the right side of the neck measuring 2.3 cm × 1.5 cm × 1.3 cm were confirmed histopathologically following their excision 18 days after the initial surgery. Infiltrative growth from the melanoma in the right side of the neck was impinging on the esophagus and could not be removed; hence chemotherapy was elected.

Chemotherapy was initiated with a combination of Methyl-CCNU[□] (100mg/m² orally on day 1 of a 21-day repeating cycle) and DTIC[□] (140mg/m² i.v. on days 1-5 of a 21-day repeating

cycle). Hematologic monitoring and antibiotic therapy (ampicillin,[□] 7mg/kg i.m., b.i.d.) were utilized for clinical evaluation and prophylaxis. Blood sample results have been tabularized (Table 1). Blood chemistries were performed only on day 1, and revealed the following: BUN - 59mg/dl; Creatinine - 1.1mg%; SGOT - 68I.U.; SGPT - 38I.U. The animal was alert and eating satisfactorily on day 16, and remained unchanged through day 20; however, it was found dead on day 21.

Post mortem examination revealed a grayish black tumor mass (1.5 cm × 1.0 cm × 0.6 cm) invading the laryngeal part of the esophagus, with the same type of tissue present in the cervical and prescapular lymph nodes. This tissue was histopathologically identified as malignant melanoma. The tumor mass was partially covered by squamous cell mucosa or exposed as an ulcerative surface. Two major types of neoplastic cells were present, along with variable amounts of fibrous stroma and melanin pigments. Spindle-shaped tumor cells formed highly cellular lobules divided by fibrous connective tissue. Epithelial-like tumor cells were present in the periphery of the tumor mass. Some bizarre large cells were also scattered among the spindle and epithelial-like cells. In general, the tumor was heavily pigmented, but pigment distribution varied from field to

[□] Division of Veterinary Medicine and Surgery, The University of Texas System Cancer Center, Houston, Texas 77030, USA.

[□] The Houston Zoological Gardens, Houston, Texas 77030, USA.

[□] 1-(2-chlorethyl)-3(4-methylcyclohexyl)-1-nitrosourea, Division of Cancer Treatment, National Cancer Institute, National Institutes of Health, Bethesda, Maryland 20014, USA.

[□] Dacarbazine, Dome Laboratories, Division of Miles Labs., Inc., West Haven, Connecticut 06516, USA.

[□] Polyflex, Bristol Laboratories, Syracuse, New York 13201, USA.

TABLE 1. Hematologic values for a fennec fox during and after chemotherapy for malignant melanoma.

Time	PCV(%)	Hg (gm%)	RBC (/mm ³)	WBC (/mm ³)	Platlets (/mm ³)
Day 1 ^a	36	11.9	6,280,000	19,000	880,000
Day 3	36	12.0	6,240,000	13,400	1,205,000
Day 5 ^b	38	ND ^c	6,600,000	9,400	1,140,000
Day 7	35	11.6	6,160,000	1,200	840,000
Day 9	35	11.6	6,190,000	3,200	305,000
Day 16	27	9.0	4,930,000	3,200	ND

^aChemotherapy begun

^bChemotherapy ended

^cND = not determined

field, with a few amelanotic fields (Fig. 1). Sections of the cervical and prescapular lymph nodes showed moderate follicular depletion and atrophy, with considerable numbers of melanophages and some melanocytes scattered in the sinuses.

A second tumor mass (0.6 cm × 0.5 cm × 0.4 cm) was present in the right lobe of the thyroid, and was histopathologically identified as a follicular cell adenoma. The mass was circumscribed from the adjacent compressed gland. It was comprised of multiple lobules of

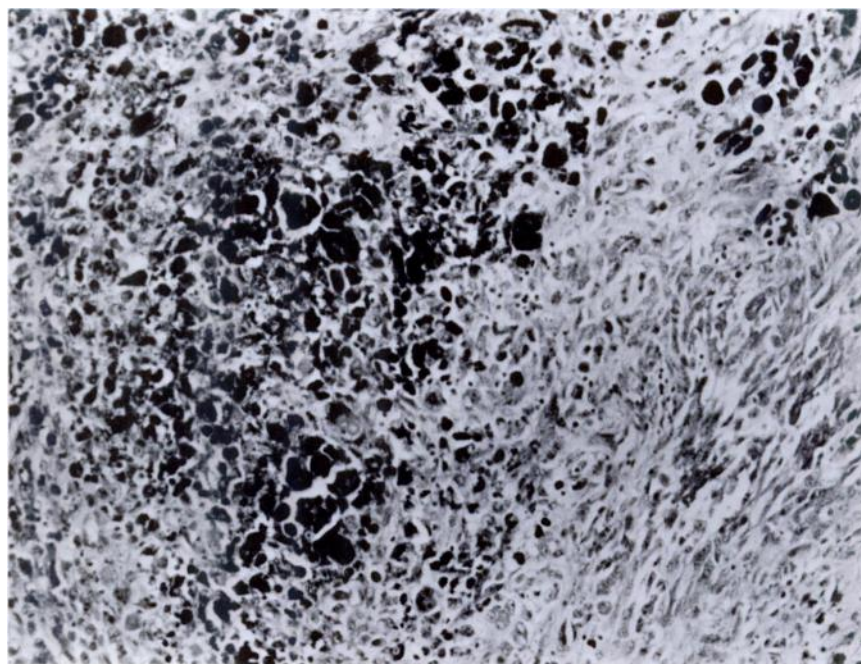


FIGURE 1. Malignant melanoma of the esophagus of a fennec fox. Note the variable pigment content and cellular pleomorphism. H&E stain. ×250.

oxyphil type cells with abundant finely granular eosinophilic cytoplasm. Follicle formation and colloid were absent in the mass.

Other significant findings occurred in the lungs, kidneys, and liver. The lungs had mild multifocal fibrosis. Kidney sections showed a diffuse interstitial fibrosis, renal tubular degeneration, and a diffuse infiltration of lymphocytes; these findings are consistent with chronic interstitial nephritis.

The liver had several small foci of necrosis and distended sinusoids filled with erythrocytes and many small focal hemorrhages. Hemoperitoneum was present and was considered to be the result of liver damage possibly associated with chemotherapy.

The selection of Methyl-CCNU and DTIC combination chemotherapy was based on its current use in experimental treatment of canine oral melanoma at The University of Texas System Cancer Center. The same dosage rates and body surface area determinations were used as in the dog. Leukopenia was maximal on day 7 following onset of chemotherapy, and the animal appeared clinically to have recovered from the anorexia and listlessness associated with chemo-

therapy by day 16, though still anemic. Interpretation of chemotherapeutic effectiveness was not possible in this case.

This is the first report of multiple primary tumors in a fennec fox. In addition, the reporting of oral melanoma and thyroid follicular adenoma in the fennec fox are previously undocumented. The simultaneous occurrence of thyroid neoplasms with other primary neoplasms has been recognized in other animals and man. Most canine thyroid adenomas are of the follicular type. The most frequent malignant oral-pharyngeal neoplasms of the canine are melanomas, squamous cell carcinomas, and fibrosarcomas. Risk for developing oral-pharyngeal cancer increases particularly after 10 yr of age (Theilen and Madewell, 1971, In: *Veterinary Cancer Medicine*, Theilen and Madewell (eds.), Lea and Febiger, Philadelphia, Pennsylvania, pp. 307-331).

Recognition is given to Drs. C.S. Smith, W.F. MacKenzie, and L.C. Stephens, for surgical, histopathological, and photographic contributions. Partial support of this work was supplied by the National Institutes of Health, National Cancer Institute Grant CA16672.

Received for publication 21 December 1981
