

## **CAUSES OF MORTALITY AND MORBIDITY OF WILD KOALAS, PHASCOLARCTOS CINEREUS (GOLDFUSS), IN VICTORIA, AUSTRALIA**

Author: Obendorf, David L.

Source: Journal of Wildlife Diseases, 19(2) : 123-131

Published By: Wildlife Disease Association

URL: <https://doi.org/10.7589/0090-3558-19.2.123>

---

BioOne Complete ([complete.BioOne.org](https://complete.BioOne.org)) is a full-text database of 200 subscribed and open-access titles in the biological, ecological, and environmental sciences published by nonprofit societies, associations, museums, institutions, and presses.

Your use of this PDF, the BioOne Complete website, and all posted and associated content indicates your acceptance of BioOne's Terms of Use, available at [www.bioone.org/terms-of-use](https://www.bioone.org/terms-of-use).

Usage of BioOne Complete content is strictly limited to personal, educational, and non - commercial use. Commercial inquiries or rights and permissions requests should be directed to the individual publisher as copyright holder.

---

BioOne sees sustainable scholarly publishing as an inherently collaborative enterprise connecting authors, nonprofit publishers, academic institutions, research libraries, and research funders in the common goal of maximizing access to critical research.

## CAUSES OF MORTALITY AND MORBIDITY OF WILD KOALAS, *PHASCOLARCTOS CINEREUS* (GOLDFUSS), IN VICTORIA, AUSTRALIA

David L. Obendorf<sup>1</sup>

Department of Veterinary Paraclinical Sciences, University of Melbourne, Veterinary Clinical Centre,  
Princes Highway, Victoria 3030, Australia

**ABSTRACT:** Between 1975 and 1980, necropsy investigations were conducted on 44 wild koalas (24 males, 20 females) from several localities in Victoria, Australia. An additional 11 (5 males, 6 females) were presented for clinical appraisal and treatment. Traumatic injuries resulting from motor vehicle accidents and intra-specific conflict were the commonest reason for submission (19 of 55; 35%). Keratoconjunctivitis (8 of 55; 15%), ascending urinary tract infections (6 of 20 females; 30%), ascending genital tract inflammation (10 of 20 females; 50%) and sarcoptic mange (2 of 55; 4%) were recognized as specific diseases or disease syndromes. A peracute syndrome characterized by lassitude, depression, anorexia and coma was identified in moribund koalas submitted from the wild and also in hospitalized animals. The condition, termed koala stress syndrome, was thought to be initiated by intercurrent disease or trauma, long term hospitalization and frequent manipulation and treatments. Hematological observations in 54 apparently healthy wild koalas from five different populations and on 17 sick or injured animals are also presented. Certain blood parameters are discussed in relation to the health status of the populations or individuals. Areas for further research into koala diseases are also discussed.

### INTRODUCTION

During the past 20 yr koalas have been the subject of considerable scientific investigation—in particular their physiology, nutrition and the management of captive and wild populations (Bergin, 1978). Many studies were initiated out of concern for the continued survival of this highly specialized marsupial.

The significance of disease was given prominence by Mackenzie (1919) and Pratt (1934). Pratt (1934) referred to ophthalmia and conjunctivitis, nephritis and cystitis, pulmonary disorders and cystic reproductive organs in females as common and serious diseases of koalas in Queensland. Both authors considered the high prevalence of reproductive disease as a potential threat to the species.

Backhouse and Bolliger (1961) reported cryptococcosis, cystic reproductive tract disorders and several forms of bacterial pneumonia in koalas from the Sydney area. Dickens (1975, 1978) later reviewed known koala diseases from the viewpoint of the practicing veterinary clinician. Other reviews by Arundel et al. (1977), Bergin (1978) and McKenzie (1981) have also

emphasized disease as important causes of mortality in both captive and wild koalas.

Pneumonic conditions attributed to infections with *Bordetella bronchiseptica* (McKenzie et al., 1979), *Cryptococcus neoformans* (Bolliger and Finckh, 1962), *Corynebacterium equi* (Francis, 1963; Rahman, 1957), and *Streptobacillus moniliformis* (Russell and Straube, 1979) have been reported. McColl and Spratt (1982) have recorded a metastrongylid nematode, *Marsupostrongylus* sp. in the lungs of koalas from Mt. Macedon, Victoria.

Cutaneous mycobacteriosis, due to *Mycobacterium ulcerans*, has been found in wild koalas from the West Gippsland (Bairnsdale) district of Victoria (Mitchell and Johnson, 1981). The condition appears to be restricted to this area, occurring also in domestic animals and man.

This paper attempts to add to this growing knowledge. Some of the common causes of morbidity and mortality of koalas in Victoria based on submissions to the Veterinary Clinical Centre, Werribee are reported in this paper. In so doing, the need for future research is emphasized.

### MATERIALS AND METHODS

#### Animals

From 1975 to 1980, 55 injured, disabled, sick or dead koalas were received at the Veterinary Clinical Centre (VCC), Werribee from numerous Victorian localities. They were principally submitted by officers of the Victorian Division of Fisheries and Wild-

Received for publication 9 September 1982.

<sup>1</sup> Present address: Mt. Pleasant Laboratories, Tasmanian Department of Agriculture, P.O. Box 46, Launceston South, Tasmania 7250, Australia.

TABLE 1. Hematological parameters of 54 wild koalas from five populations in Victoria, Australia.

Brisbane Ranges	Sex* (number)	PCV (%)	Hb (g/dl)	RCC ( $\times 10^{12}$ /liter)	WCC ( $\times 10^9$ /liter)	NRBC's ( $\times 100$ WBC's)	DWCC ( $\times 10^6$ liter)					L:M:N %
							Neutrophils	Eosinophils	Basophils	Lymphocytes	Monocytes	
	M (3)	46 (46-52)	15.1 (14.1-16.2)	4.4 (4.0-4.6)	6.35 (4.3-11.0)	790 (0-1,190)	3.221 (2,070-4,879)	46 (0-138)	0	5.474 (4,347-7,434)	669 (345-1,190)	64.7:34.3
	F (4)	46.5 (42-50)	15.1 (14.0-15.7)	3.7 (3.0-4.0)	9.85 (6.9-11.9)	90 (0-188)	1.991 (1,316-2,640)	109 (0-324)	0	3.798 (1,892-7,700)	363 (172-550)	67.6:32.4
French Island	M (6)	47 (43-52)	14.7 (13.7-16.2)	4.0 (3.8-4.2)	7.0 (4.4-9.9)	505 (44-1,079)	1.477 (780-2,574)	45 (44-99)	17 (0-83)	5.032 (322-6,942)	137 (0-186)	77.8:22.2
	F (5)	40 (31-50)	13.0 (10.0-15.8)	3.3 (2.6-4.0)	7.6 (4.4-10.9)	266 (126-518)	2.400 (572-5,232)	218 (44-654)	0	4.456 (2,520-7,209)	215 (109-315)	65.7:34.3
Phillip Island	M (1)	46	14.0	6.0	5.8	305	3,500	0	0	2.074	122	38.5:61.5
	F (5)	44 (43-47)	13.9 (13.5-14.4)	4.3 (3.8-4.8)	4.3 (3.2-5.2)	776 (750-800)	8,500 (7,200-10,000)	0	0	3.050 (2,440-3,960)	280 (240-300)	28.1:71.9
Pental Island	M (2)	47 (43-48)	14.6 (13.5-15.7)	4.2 (4.0-4.4)	6.2 (5.5-6.9)	90 (69-110)	2.100 (2,000-2,300)	0	35 (0-69)	3.659 (2,695-4,623)	282 (123-440)	64.7:35.3
	F (4)	43 (33-50)	13.3 (10.5-16.0)	3.9 (3.2-4.6)	5.6 (3.8-6.9)	326 (65-759)	2,300 (1,100-3,900)	0	0	2.762 (1,518-5,330)	250 (102-690)	56.7:43.3
Walker-ville	M (12)	40.6 (33-44)	13.2 (11.0-14.2)	3.7 (3.2-3.8)	7.3 (1.7-9.6)	235 (0-660)	1,750 (476-4,212)	654 (79-1,764)	35 (0-198)	4.088 (984-5,829)	334 (0-850)	72.2:28.6
	F (12)	38.0 (31-43)	12.1 (9.1-14.3)	3.5 (2.8-3.8)	6.0 (3.8-8.6)	319 (76-1,288)	1,563 (549-2,144)	556 (49-1,204)	25 (0-147)	3.847 (1,634-5,848)	254 (0-476)	72.4:27.6

\* M—male; F—female.

life, Ministry for Conservation. Some animals were received from members of the public and some were found by the author.

At presentation live animals were examined; in cases with a poor prognosis the animals were killed and examined at necropsy. Animals with significant treatable conditions were maintained in the small animal hospital at the VCC, some for up to 2 wk. Koalas requiring occasional observation and/or less frequent medical treatment were held in external enclosures at "Serendip" Wildlife Research Station, Lara, the Ocean Grove Nature Reserve or the Barwon Heads Wildlife Shelter. Several animals with minor injuries were treated and released directly back into suitable wild habitats.

#### Necropsy examinations

Forty-four koalas from 11 locations were examined by routine necropsy procedures. The origin and number of animals from each locality are as follows: Brisbane Ranges National Park (8), French Island (2), Geelong area (7), Mt. Eliza (1), Mt. Macedon (3), Narbethong (1), Phillip Island (12), Swan Hill (2), You Yangs Forest Park (5), Walkerville (2) and Wonthaggi (1).

Tissues were fixed in 10% formol-saline for histopathological examination. Sterile swab and pipette samples from the conjunctival sac, urinary bladder, female genital tract and from other tissues and organs which appeared grossly abnormal were cultured by routine aerobic bacteriological methods. Scrapings of abnormal skin were examined microscopically as wet preparations mounted in mineral oil or 10% potassium hydroxide. Urine samples were tested for blood, ketone bodies, reducing substances and glucose; pH and specific gravity were also measured. Centrifuged urinary sediments were examined.

#### Hematology and serology

Blood samples from 17 koalas presented at the VCC as well as 54 samples taken from wild, apparently healthy koalas from five different areas were examined. Hemoglobin, packed cell volume (PCV), red cell count (RCC), total white cell count (TWCC), differential white cell count (DWCC) and nucleated red blood cell count (NRBCC) were calculated for each sample. Results were analyzed by averaging the parameters within the same sex and population. Blood urea nitrogen (BUN) levels were also measured on some samples.

Serum samples were tested for chlamydial antibodies with complement fixation tests using a chlamydial antigen derived from cases of sporadic bovine encephalomyelitis (SBE). These tests were performed at the Veterinary Research Institute, Victorian Department of Agriculture, Melbourne.

### RESULTS

Blood samples from 54 wild koalas from five different localities were collected. The hematological parameters for each population are displayed in Table 1. Variations from the "nor-

TABLE 2. Prevalence of the major diseases encountered in koalas from Victoria, Australia.

	Male	Female	Total
Number of koalas examined	29	26	55
Traumatic injuries			
Motor vehicle accidents	7	5	12
Gun shot	1	1	2
Intraspecific fighting and wounds	3	2	5
Koala stress syndrome	9	4	13
Genital tract pathology	0	10	10
Urinary tract infection	0	6	6
Keratoconjunctivitis	4	4	8
Sarcoptic mange	1	1	2

mal" were noted in some parameters of animals from two populations (Walkerville and Phillip Island). Mild anemia with high eosinophil counts was encountered in animals from Walkerville. TWCC of koalas from Phillip Island were lower than those in other populations with evidence of a relative neutrophilia.

Of the 55 koalas submitted, 26 were dead, 29 were presented alive, of which 18 were killed and 11 successfully treated and returned to their original habitat. Euthanasia was carried out only after clinical examination had indicated a poor prognosis for recovery. The major diseases encountered in these koalas are summarized in Table 2.

#### Traumatic injuries

The most common presentation was traumatic injury (19) resulting from road accidents (12 of 19), although some injuries may have resulted from fighting (5 to 19). Tracking cellulitis, fistulated discharging abscesses and deep suppurative wounds which were subject to secondary cutaneous myiasis (fly strike), were seen. Lacerations to the eyelids, face, neck and shoulders were thought to be associated with fighting. Gun shot wounds were also evident in two koalas.

Although certain wounds and injuries were treated medically and surgically, six koalas died during hospitalization or convalescence. The majority of these deaths were not attributable to the severity of the injury. They were thought to be related to stress factors which existed immediately prior to and during hospitalization and treatment. Prolonged period between injury and presentation was thought to reduce the prospect for successful recovery.

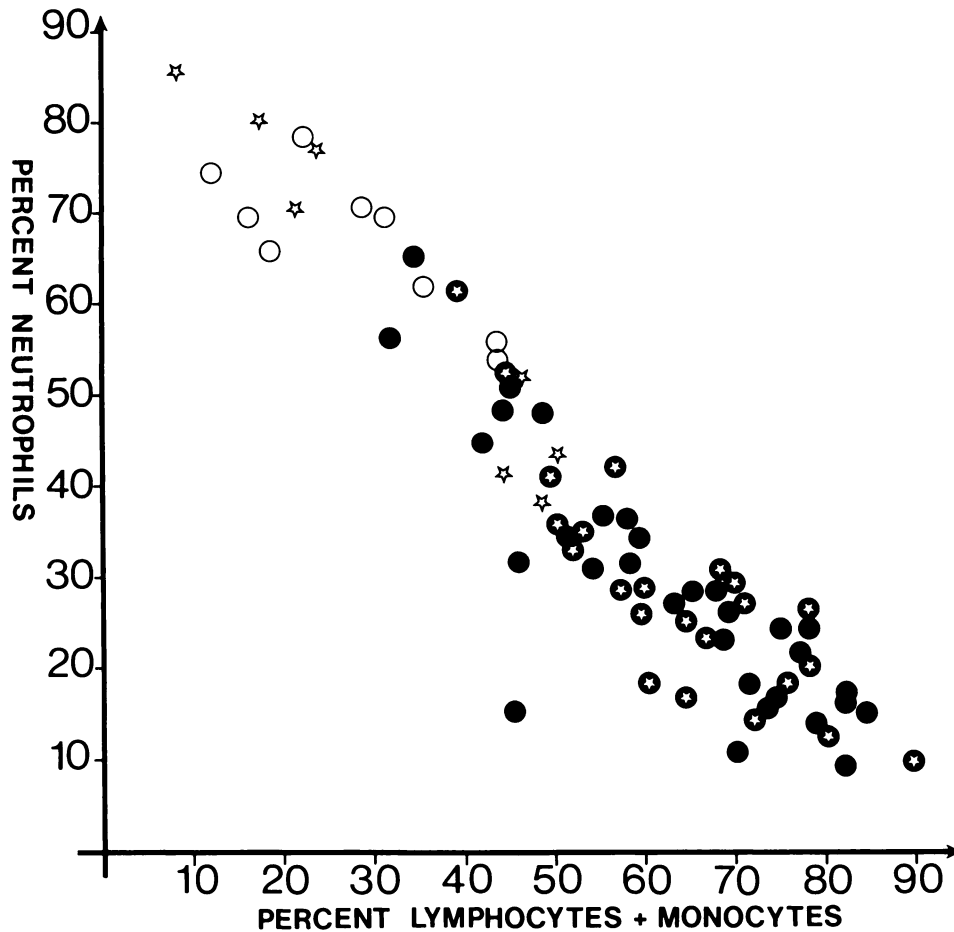


FIGURE 1. Relationship between percent neutrophils and percent lymphocytes and monocytes for koalas from five localities in Victoria. Symbols are as follows: open stars within solid circles = wild-caught males ( $n = 23$ ); solid circles = wild-caught females ( $n = 31$ ); open stars = sick or injured males ( $n = 8$ ); open circles = sick or injured females ( $n = 9$ ).

Hematology was carried out in 17 sick and injured koalas. Those with suppurative lesions such as subcutaneous abscesses, suppurative arthritis and cellulitis conditions had high WCC ( $>15.0 \times 10^9/\text{liter}$ ) and a relative neutrophilia. Seven male and five female koalas which had sustained motor vehicle trauma as well as those with chronic disabilities such as osteoarthritis and chronic keratoconjunctivitis had low WCC (males  $2.6\text{--}7.4 \times 10^9/\text{liter}$ , average  $5.1 \times 10^9/\text{liter}$ ; females  $2.7\text{--}7.1 \times 10^9/\text{liter}$ , average  $5.7 \times 10^9/\text{liter}$ ) again characterized by a relative neutrophilia (Fig. 1).

The abnormalities in certain hematological and blood chemistry parameters were sugges-

tive of marked alterations in homeostasis and metabolic function. Such animals exhibited similar clinical and pathological features as those with so-called koala stress syndrome. This condition will be discussed subsequently.

#### Koala stress syndrome

Wild koalas appear to be highly susceptible to a syndrome characterized by lassitude, depression, anorexia and a precipitous decline in metabolic function. The etiology of this condition is unknown. Males were predominately affected in this study. They were found wandering aimlessly or prostrate and comatose, with no evidence of trauma or overt illness. Some

affected animals were found at the base of trees reluctant to climb or eat. A similar syndrome was noted in animals which had undergone prolonged hospitalization and treatment. Clinically the animals were unusually docile and easy to handle, with hypothermia (<33 C), bradycardia (<30/min) and anorexia. With hospitalization, these koalas showed initial improvement especially after elevation of their core temperature. Some animals began to drink water, but showed no interest in eating, and there was progressive weight loss, and eventual death.

In five cases (4 males, 1 female) hematological parameters indicated hemoconcentration (Hb 16.6–17.9 g/100 ml, PCV 48–55%) and leucopenia (WCC  $2.6\text{--}6.1 \times 10^6/\text{liter}$ ) characterized by a lymphopenia and relative neutrophilia. Hypoglycemia (blood glucose <20 mg %) and an elevated BUN (>60 mg %) were also noted in three cases.

Necropsy findings confirmed the state of dehydration and loss of muscle bulk. Histopathology findings included atrophy of lymphoid follicles in the spleen and lymph nodes, and a depletion in the size and number of adrenal cortical cells. Acute tubular nephrosis was also a common histological finding in these koalas.

#### Female genital tract pathology

Inflammatory lesions were noted in the reproductive tracts of 10 of 20 female koalas from several Victorian localities. The pathology is described and discussed in greater detail elsewhere (Obendorf, 1981). Vaginitis, pyometritis and endometritis were the most commonly encountered lesions. Cystic dilation of the ovarian bursa, occasionally in association with hydro-salpinx, was recorded in six koalas with concurrent inflammatory changes in the lower genital tract. The cystic lesions were considered to have developed as chronic sequelae of previous inflammatory processes in the ovarian bursa. There were no pathological changes in ovaries of these 10 affected cases.

#### Urinary tract infections

Ascending urinary tract infections were entirely restricted to female koalas, the majority of them being young. Clinically they showed increased frequency of urination with dribbling and continual wetting of the fur around the tail and rump. The condition is colloquially re-

ferred to as “wet-tail” or “dirty-tail.” Affected koalas were usually bright and showed interest in eating. However, unlike their healthy counterparts, these animals drank large quantities of water. Chronically affected animals were underweight with dry coarse coats. Cutaneous myiasis (fly-strike) to the perineum and hind-quarters was also seen.

Urine contained red blood cells, polymorphonuclear inflammatory cells, bacteria, desquamated transitional epithelial cells and occasionally renal tubular casts. Anemia (Hb 7.1–10.6 g/dl, PCV 21–33%) and hypoproteinemia (total protein 2.2–3.2 g/100 ml) were consistent findings. Elevated BUN levels were present in some cases, but generally did not appear to be a feature of the disease.

A wide variety of bacteria including coagulase-positive *Staphylococcus* sp., haemolytic *Streptococcus* sp., *Escherichia coli*, *Proteus* sp. and diptheroids as well as yeasts were isolated from cultures of urine and swabs from the urinary bladder and renal pelvis.

Macroscopically, the urinary bladder and urethra were always affected. They showed mucosal ulcerations and hemorrhage both into the lumens and within the mucosae, as well as edematous thickened walls. Several koalas had one or both ureters thickened due to similar inflammatory changes. These also had pyelonephritis and renal interstitial fibrosis. Small, firm kidneys were seen in two koalas with chronic generalized renal fibrosis.

Inflammatory changes in tissue sections were both chronic and progressive. The urethra, bladder and ureters showed epithelial erosions, deep mucosal ulcerations, plasma cell infiltrates with lymphocyte aggregations in the submucosa, and the formation of proteinaceous pseudomembranes. Renal histology ranged from tubular degeneration and proteinaceous cast formation to focal and generalized pyelonephritis with interstitial infiltrates of plasma cells and lymphocytes. In several chronic cases, hydronephrosis, glomerular tuft atrophy and extensive renal fibrosis incorporating small focal aggregates of lymphocytes were seen.

#### Keratoconjunctivitis

Eight of 55 (15%) koalas examined in this study had conjunctival and ocular lesions consistent with chlamydial keratoconjunctivitis (Cockram and Jackson, 1974). Bilateral lesions

were more commonly encountered. Five cases had mucopurulent ocular discharges which encrusted and at times caused eyelid closure. Two of these koalas had red and edematous conjunctivae, while three others showed villous proliferation of the palpebral conjunctivae with chemosis completely obscuring the eye. An additional three cases had corneal scarring, pigmentation and superficial vascularization. In one of these cases an anterior synechia was present and was thought to be a sequel of corneal ulceration. Secondary trauma to the eyelids as a result of scratching and rubbing, with superimposed bacterial infections, was commonly encountered in affected koalas.

The acute cases were seen in the late summer and autumn. Two young koalas with acute conjunctivitis were successfully treated with topical oxytetracycline ointment. Frequent treatments for up to 3 wk were necessary to bring about remissions. Koalas with long standing keratoconjunctivitis were refractory to such treatment.

In cases presenting with chemotic proliferative conjunctivae, the histological appearance was characterized by villous hyperplasia with plasma cell and polymorphonuclear cell infiltrates into the subepithelial tissues. Polymorphonuclear cell accumulations within the conjunctival sac were common in cases with secondary bacterial infection. Early corneal changes consisted of opacity due to edema and mild episcleral congestion. Chronic corneal changes were ulceration, vascularization, fibrosis and pigmentation.

Four koalas with eye lesions thought to be typical of chlamydial keratoconjunctivitis had antibodies to the SBE complement fixation test ranging from 1:128 to 1:4,096 while 11 koalas with no obvious eye abnormalities had titers ranging from 1:16 to 1:512 (average titer 1:172).

#### **Sarcoptic mange**

The mange mite, *Sarcoptes scabiei*, was recovered in large numbers from skin scrapings of two juvenile koalas from Phillip Island. Both animals had grossly thickened dry encrusted lesions on the foot-pads, face, nose and lips. Cracking and moist exudation was evident along the skin folds of the paws and digits. The forelimbs, chest, face and abdomen also contained numerous scab-like lesions. Alopecia was not a

feature of the condition. Severe pruritis was evident causing the animals to lick and bite their paws.

#### **DISCUSSION**

The results of this study indicate that motor vehicle accidents represent a significant cause of mortality among koalas in certain sanctuaries in Victoria (e.g., Phillip Is.) and national parks (e.g., Brisbane Ranges National Park). In all these wildlife sanctuaries speed restrictions and wildlife warning and crossing signs need to be erected and stringently policed.

Intraspecific trauma may result from hierarchy conflicts and aggressive interactions, especially during the breeding season. Biting to the head, neck and shoulders are recognized fighting behavior of koalas (Smith, 1980). Lacerations and scratches to the face, eyes, and limbs are possibly due to clawing and trauma resulting from falling while climbing in trees.

Certain diseases of koalas have been considered significant causes of morbidity and mortality within specific populations. Individual sporadic cases of keratoconjunctivitis appear to be common, although there are reports of high prevalence of this disease in certain populations. Keratoconjunctivitis was thought to be associated with the decline in koala numbers in Queensland between 1885 and 1930 (Pratt, 1934). Chlamydial keratoconjunctivitis still represents a major disease of koalas across their range (Cockram and Jackson, 1974, 1976, 1981; Dickens, 1978; McKenzie, 1981). The mode of infection is unknown, though flies may act as mechanical vectors. The impairment of vision caused by this disease adversely affects the feeding of koalas and may also predispose to trauma from motor vehicle accidents. The duration of the disease is unknown, however, the finding of three koalas with chronic ocular lesions may be an indication that partial recoveries in the wild may occur.

The etiology of ascending urinary tract infections in female koalas is not known. Dickens (1978) suggested that the bacteria isolated from "wet-tail" cases may be of secondary importance, and this is borne out in this study. He has suggested that the causative agents may be *Mycoplasma*, chlamydiae or viruses. In the current study, four of six koalas with "wet-tail" from Phillip Island also had ascending genital

tract lesions suggesting that the two conditions may be associated. Preliminary findings suggest that chlamydia may be incriminated as the causative agent of the genital tract lesions (McCull, pers. comm.). If so, it may be that chlamydia infections are responsible for the ascending lesions in both of these systems. This is likely since the external openings of the urinary and genital tract are in close proximity.

At Phillip Island there is a high prevalence of genital tract pathology. Martin (1981) has demonstrated a significant reduction in the reproductive efficiency of this population with a resultant domination of the population by older individuals due to lack of juvenile recruitment. The long-term effects of this tendency on the survival of this population are considered serious. Therefore, it is evident that further investigation into the etiology and source of the genital tract pathology is required.

Both the urinary and genital tract conditions in females are cause for some concern in relation to translocation and repopulation of koalas from Phillip Island to other suitable habitat areas. Since both these conditions may share a similar etiology and may be transmitted venereally, the immediate health of the translocated females and the long-term breeding prospects of such newly established populations may be in jeopardy. On this basis, the use of Phillip Island specifically as a nucleus sanctuary for future translocation of breeding animals should be seriously reconsidered.

The leucopenia characterized by a relative neutrophilia may relate to the higher prevalence of urinary, genital and ocular disease in this particular population. Consequently, the L+M:N % ratio may be a useful indicator of the health status of this population.

Sarcoptic mange has been previously reported in a juvenile koala which had been hand-reared with a wombat (Barker, 1974). Wild wombats, *Vombatus ursinus*, are known to harbor *S. scabiei*, and in this reported case, was the likely source of infection. Sarcoptic mange has also been reported in captive koalas from Queensland (Brown et al., 1982). Barker (1974) suggested that scabies infection of Australian marsupials may represent a comparatively recent infection derived from man and his domestic animals. Cross infection studies using canid-derived and marsupial-derived *S. scabiei*

in a range of hosts have not been carried out. Such investigations may help to determine the host origins of the marsupial derived form. Treatment of sarcoptic mange has been successfully carried out by whole body immersion in 0.2% Malathion or 0.25% Amitraz aqueous solutions repeated two or three times at 10 day intervals (Barker, 1974; Brown et al., 1982).

Koala stress syndrome was diagnosed both in animals presenting from the wild and several traumatized koalas which developed the syndrome while undergoing hospitalization and treatment. Males were more prone to the condition than females. It is suspected that the condition is stress related. In hospitalized and convalescent koalas, surgical intervention, anesthesia, post-operative handling and medical treatment were thought to be the stress factors.

After several attempts to treat, maintain and release koalas, it became apparent that certain hematological and biochemical parameters were of prognostic value. A shift in the leucocyte ratio favoring polymorphonuclear leucocytes coupled with a low WCC ( $<6.0 \times 10^9$ /liter), and elevated BUN ( $>60$  mg %), hemoconcentration (Hb  $> 16.0$  g/100 ml) and hypoglycemia ( $<20$  mg %) were considered poor prognostic parameters. The age and severity of the injury, the degree of impairment to locomotion, chewing and feeding and the general alertness at presentation were considered important preliminary factors for deciding whether treatment and hospitalization would be attempted. Mature males showed a poorer recovery rate than females and juveniles. Prolonged hospitalization, regular handling and manipulation in the course of treatment reduced the probability of successful rehabilitation of these injured koalas. The factors which initiate this syndrome and reasons for the drastic alteration in homeostasis and metabolic function, as indicated by the clinical presentation and hematological parameters, are not known. The term, koala stress syndrome was used in response to the perceived increase in "stress factors" acting on these koalas and is not intended as a physiological explanation for the condition.

The extent of injuries, treatment options and post-operative care may have to be considered in the light of the chances for a successful recovery, as this syndrome proved uniformly fa-



tal. Handling and transit stresses during capture and translocation of koalas, particularly in respect to mature male animals, should be minimized to prevent the possible development of acute signs of koala stress syndrome.

The most consistently useful hematological parameter for assessing the health status of the koala was considered to be the ratio percentage of lymphocytes and monocytes to neutrophils (L+M:N ratio). Significantly injured or sick animals presented at the VCC had low L+M:N ratios (35:65) in comparison with normal animals bled from wild populations (70:30). The mild anemia and relative eosinophilia evident in koalas from Walkerville was attributed to heavy infestations of the tick, *Ixodes tasmani*, during the spring and autumn periods. A comparison of PCV, hemoglobin concentration and RCC of Walkerville koalas in August 1980 and January 1981 has demonstrated a significant reduction in these parameters with an elevation in eosinophil counts in the January sample associated with increases in tick numbers.

Much of the research into the koala has been initiated out of concern for the continued survival of this marsupial in the face of diminishing habitat, infertility problems and the threat of disease. Across its natural range, the koala is fully protected and is no longer considered endangered. The use of Phillip Island as a sanctuary for koalas has been part of a long-term plan for the conservation of this unique marsupial. Nevertheless, the small size of the island and of its individual koala reserves has created certain management problems. In the past decades, translocation of surplus animals to other suitable habitats in Victoria occurred as the island population increased. Overuse of the available favored habitat and, in some cases, food tree depletion make management of this island population difficult. The popularity of Phillip Island as a tourist resort has led to additional problems for koalas. Main roads bisecting koala sanctuaries have made motor vehicle accidents common while the continuous close exposure to humans may represent a further stress factor.

Sound management of koala populations in sanctuaries, national parks and forest habitats is vital for their continued survival. It is hoped that this study will provide the stimulus for a greater understanding of the role diseases may have in this regard.

#### ACKNOWLEDGMENTS

I would like to thank Messrs. F. Brown, M. O'Sullivan, K. Cherry, D. White, J. Davidson and other officers of the Victorian Fisheries and Wildlife Division, Ministry for Conservation for submitting sick and injured koalas for examination. A special vote of thanks is extended to Mr. R. Martin, Department of Zoology, Monash University for providing koalas from the Phillip Island and Walkerville areas.

I am indebted to Mr. J. Wheeler, Mrs. T. Lehrman and Mr. J. and Mrs. J. Bailey for providing aftercare facilities for several convalescing koalas. Drs. J. Wilkinson, N. Sullivan and R. Reuter are thanked for their assistance in the field of clinical pathology and histopathology.

Thanks are also extended to Mr. F. Oddi, Mrs. J. Wilson, Miss A. Pearce and Mrs. C. Reich for their technical assistance.

Were it not for the encouragement of my wife, Maree, and the able reviewing by Drs. I. K. Barker, I. Beveridge and J. H. Arundel, this manuscript would not have been published.

#### LITERATURE CITED

- ARUNDEL, J. H., I. K. BARKER, AND I. BEVERIDGE. 1977. Diseases of marsupials. In *The Biology of Marsupials*, Ed. B. Stonehouse and D. Gilmore (eds.). MacMillan Press, London, pp. 141-154.
- BACKHOUSE, T. C., AND A. BOLLIGER. 1961. Morbidity and mortality in the koala *Phascolarctos cinereus*. *Aust. J. Zool.* 9: 24-37.
- BARKER, I. K. 1974. *Sarcoptes scabiei* infection of a koala *Phascolarctos cinereus* with probable human involvement. *Aust. Vet. J.* 50: 528.
- BERGIN, T. J., ed. 1978. *The Koala*. Australia Proceedings of the Taronga Symposium on Koala Biology, Management and Medicine. Zoological Parks Board of New South Wales, Sydney, Australia, 239 pp.
- BOLLIGER, A., AND E. S. FINCKH. 1962. The prevalence of cryptococcosis in the koala (*Phascolarctos cinereus*). *Aust. J. Sci.* 24: 325.
- BROWN, A. S., A. A. SEAWRIGHT, AND G. T. WILKINSON. 1982. The use of Amitraz in the control of an outbreak of sarcoptic mange in a colony of koalas. *Aust. Vet. J.* 58: 8-10.
- COCKRAM, F. A., AND A. R. B. JACKSON. 1974. Isolation of a chlamydia from cases of keratoconjunctivitis in koalas. *Aust. Vet. J.* 50: 82.
- , AND ———. 1976. Chlamydial keratoconjunctivitis in koalas. *Aust. Vet. Pract.* 6: 36-38.
- , AND ———. 1981. Keratoconjunctivitis of the koala *Phascolarctos cinereus* caused by *Chlamydia psittaci*. *J. Wildl. Dis.* 7: 497-503.
- DICKENS, R. K. 1975. The koala *Phascolarctos cinereus*, past, present and future. *Aust. Vet. J.* 51: 459-463.

- . 1978. The Koala in Health and Disease. Proceedings No. 36. Postgraduate Committee in Veterinary Science, University of Sydney Fauna Course, Part A, pp. 105–117.
- FRANCIS, J. 1963. Susceptibility of *Corynebacterium equi* to streptomycin and treatment of pneumonia of koala bears. *Vet. Rec.* 75: 642.
- MACKENZIE, W. C. 1919. The Genito-Urinary System in Monotremes and Marsupials. Jenkin Buxton and Co., Melbourne, Australia, 106 pp.
- MARTIN, R. 1981. Age-specific infertility in three populations of koala *Phascolarctos cinereus*. *Aust. Wildl. Res.* 8: 275–283.
- MCCOLL, K. A., AND D. M. SPRATT. 1982. Parasitic pneumonia in a koala (*Phascolarctos cinereus*) from Victoria, Australia. *J. Wildl. Dis.* 18: 511–512.
- MCKENZIE, R. A. 1981. Diseases of free living and captive koalas *Phascolarctos cinereus*. *Aust. Vet. J.* 57: 243–246.
- , A. D. WOOD, AND P. J. BLACKALL. 1979. Pneumonia associated with *Bordetella bronchiseptica* in captive koalas. *Aust. Vet. J.* 55: 427–430.
- MITCHELL, P., AND D. JOHNSON. 1981. The recovery of *Mycobacterium ulcerans* from koalas in east Gippsland. In *Wildlife Diseases of the Pacific Basin and other Countries*, M. E. Fowler (ed.). Wildlife Disease Association, Ames, Iowa, USA, p. 48.
- OBENDORF, D. L. 1981. Pathology of the female reproductive tract in the koala *Phascolarctos cinereus* (Goldfuss), from Victoria, Australia. *J. Wildl. Dis.* 17: 587–592.
- PRATT, A. 1934. Koala diseases. In *The Call of the Koala*. Robertson and Mullen, Melbourne, Australia, pp. 96–99.
- RAHMAN, A. 1957. The sensitivity of various bacteria to chemotherapeutic agents. *Brit. Vet. J.* 113: 175–188.
- RUSSELL, E. G., AND E. F. STRAUBE. 1979. Streptobacillary pleuritis in a koala (*Phascolarctos cinereus*). *J. Wildl. Dis.* 15: 391–394.
- SMITH, M. 1980. Behaviour of the koala, *Phascolarctos cinereus* (Goldfuss), in captivity. VI. Aggression. *Aust. Wildl. Res.* 7: 177–190.