



Fetal Mummification in the Sandbar Shark, *Carcharhinus plumbeus* (Nardo, 1827)

Authors: Rosa-Molinar, Edward, and Williams, Carol S.

Source: Journal of Wildlife Diseases, 19(2) : 156-158

Published By: Wildlife Disease Association

URL: <https://doi.org/10.7589/0090-3558-19.2.156>

BioOne Complete (complete.BioOne.org) is a full-text database of 200 subscribed and open-access titles in the biological, ecological, and environmental sciences published by nonprofit societies, associations, museums, institutions, and presses.

Your use of this PDF, the BioOne Complete website, and all posted and associated content indicates your acceptance of BioOne's Terms of Use, available at www.bioone.org/terms-of-use.

Usage of BioOne Complete content is strictly limited to personal, educational, and non - commercial use. Commercial inquiries or rights and permissions requests should be directed to the individual publisher as copyright holder.

BioOne sees sustainable scholarly publishing as an inherently collaborative enterprise connecting authors, nonprofit publishers, academic institutions, research libraries, and research funders in the common goal of maximizing access to critical research.

Game Reserve, Tanzania. The estimated recruitment of calves into yearlings for that year was relatively low, i.e. 50%.

In the wet season of 1972, I recognized a similar condition in the northern sector of the Reserve (Gainer, 1979, M.S. Thesis, Univ. British Columbia, Vancouver, British Columbia, 203 pp.). Virtually every herd of wildebeest in this area contained calves that were lame. Two 3-mo-old calves were collected for examination as part of a survey of the parasites, diseases and anomalies of wildlife in the Reserve.

One calf was weak and captured by hand, another was shot. The live calf was lethargic and reluctant to move, maintaining a head-down, stiff-legged posture. Its rectal temperature was 36 C, the ambient air temperature. Several limb joints were noticeably enlarged and purulent material drained from the left front interdigital space. Despite treatment with procaine penicillin, the animal died 20 hr later.

At necropsy, both calves had limb joints full of a dry, caseous material. The intermetacarpals and intermetatarsals were the most severely affected joints, but the most extensive involvement was one of the live calf's coxofemoral joints. The joint capsule was obliterated completely and the necrotic femoral head had separated from the femur. In addition, the liver of

this calf had a 15-cm region of unwallied necrosis and a 2-cm localization of inflammation in the left posterior-dorsal lung. These lesions are all typical of the fulminating foot abscess form of necrobacillosis in young ruminants (Rosen, 1981, op. cit.).

Several samples of the joint material were submitted for bacterial culture and identification. From this material *F. necrophorum* was isolated and identified according to established criteria (Merchant and Packer, 1971, Veterinary Bacteriology and Virology, Iowa State University Press, Ames, Iowa, 752 pp.).

Despite the fact that this is the first published account of necrobacillosis in wildebeest, biologists in the area consider this disease to cause significant losses in this species. The recruitment of calves into yearlings in the population near Miombo Center was 80% in 1972 and 1973, approximately 25% higher than in 1969 when the outbreak occurred. Calves that are even mildly affected would have little chance of escaping predation. In this area, wildebeest were the only species affected, and only calves were involved.

I wish to thank Dr. P. H. Hummel for the laboratory work and Mr. F. Mes for field assistance.

Journal of Wildlife Diseases, 19(2), 1983, pp. 156-158
© Wildlife Disease Association 1983

Fetal Mummification in the Sandbar Shark, *Carcharhinus plumbeus* (Nardo, 1827)

Edward Rosa-Molinar¹ and Carol S. Williams, Department of Biology, Carver Research Laboratories, Tuskegee Institute, Tuskegee Institute, Alabama 36088, USA; Sneed Collard, Department of Biology, University of West Florida, Pensacola, Florida 32504, USA

Reports of fetal mummification in sharks are rare. Randall (1977, *Pac. Sci.* 31: 143-164), Springer (1960, *Fish. Bull.* 178, 61: 1-38) and Clark and von Schmidt (1965, *Bull. Mar. Sci.*

15: 13-83) reported fetal "mummies" but provided no detailed descriptions. Springer (1960, op. cit.) reported two fetuses of *C. plumbeus* with no noticeable putrefactive decomposition. Randall (1977, op. cit.) reported one fetus in *Triaenoden obesus*, and Clark and von Schmidt (1965, op. cit.) reported three species representing three genera of the family Carcharhinidae, *Mustelus norrisi* (1 fetal mummy); *Carcharhinus plumbeus* (2 fetal mummies) and

Received for publication 9 April 1982.

¹ Present address: Department of Microbiology, School of Veterinary Medicine, Auburn University, Auburn, Alabama 36830, USA.

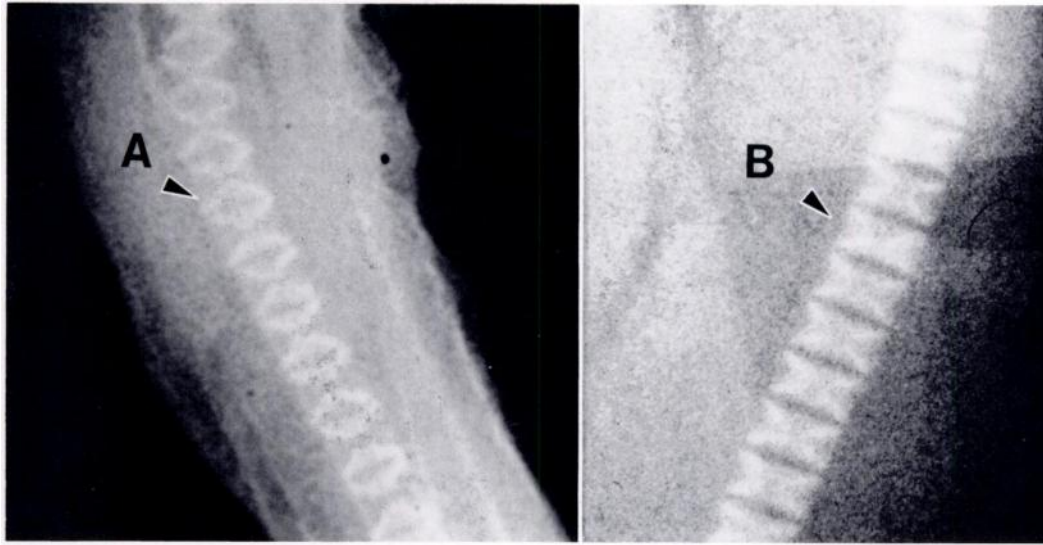


FIGURE 1. Radiographs of vertebrae of sandbar shark fetuses. Note spherical type vertebrae and hollow centra in the mummified fetus (A) as opposed to the normal "bow-tie" type vertebrae and well-developed centra in the normal fetus (B).

Galeocerdo cuvieri (2 fetal mummies). This is the first descriptive report of fetal mummification in the sandbar shark.

A gravid female sandbar shark was collected by rod and reel at the Pensacola Shark Rodeo, Pensacola, Florida, on July 23, 1980. After necropsy revealed 10 mummified male fetuses, for comparative purposes two "normal" specimens of *C. plumbeus* were obtained on loan from the Museum of Comparative Zoology at Harvard University, Cambridge, Massachusetts (MCZ-202, MCZ-3561). Fetal measurements similar to those used by Bigelow and Schroeder (1948, Mem. Sears Found. Mar. Res. 1: 57-576), were taken on both the "mummies" and "normal" fetuses. Radiographs were taken on a transworld x-ray machine, using 10-MA units between 46-52 KVP's. Counts of vertebrae were made using the method of Springer and Garrick (1964, Proc. U.S. Nat. Mus. 116: 73-96).

Initial examination revealed that all of the fetuses were coated with a brown mucous film. One had a ruptured abdominal wall, exposing the viscera. This same fetus had exposed vertebrae. Necropsy also revealed hypomelanosis in one fetus, a condition which has been linked to loss or shut down of the melanocyte system and to hypervitaminosis A (Ashley, 1972, *In Fish Nutrition*, Halver (ed.), Academic Press,

New York, pp. 439-537; Snieszko, 1972, *In Fish Nutrition*, Halver (ed.), Academic Press, New York, pp. 403-435).

The precaudal length for the "mummies" ranged from 11-17 ($\bar{x} = 14.0$) cm. Weights ranged from 11 to 32 ($\bar{x} = 21.5$) g. The precaudal length for the "normal" fetuses ranged from 25-28 ($\bar{x} = 26.5$) cm. Weights ranged from 145-290 ($\bar{x} = 216$) g. Radiographs of the "mummies" and the "normal" fetuses showed differences in the shape of individual vertebral segments. The vertebrae of the "mummies" appeared to be spherical with poorly developed centra and with solid well-developed edges, whereas the vertebrae of the "normal" appeared to present a "bow-tie" type with well-developed centra and solid well-developed edges (Fig. 1). This either suggests abnormality in the development of vertebrae in the mummies or is evidence of reabsorption.

A comparison of vertebral counts of the mummified and the normal fetuses revealed that the mummified fetuses had lower total vertebral counts than did the "normal" fetuses, but the precaudal vertebrae were not different. In fetal development of *C. plumbeus* it has been reported that skeletal structures (cartilage) are present and differentiated after 3 mo in utero (Romer, 1942, Am. Nat. 76: 394-404; Romer

and Parsons, 1977, *The Vertebrate Body*, W. B. Saunders Co., Philadelphia, Pennsylvania, 624 pp.). These mummies are 3 mo in development as evidenced by the presence of placentas (Wrass, 1973, *Pac. Sci.* 27: 305–318). The total counts of vertebrae for the mummified fetuses ranged from 150–157 (\bar{x} = 153.5). The counts for the normal fetuses ranged from 176–178 (\bar{x} = 177.0). The mummified precaudal vertebrae ranged from 76–79 (\bar{x} = 72.2) whereas the normal fetuses' precaudal vertebrae ranged from 80–82 (\bar{x} = 81.0).

Based on our observations of total and precaudal vertebral counts, it appears that the development of these fetuses prior to mummification was abnormal. It is difficult to interpret these findings in terms of maternal physiology since only one specimen was collected and all of our observations are postmortem. Mummification in other vertebrates has been attributed to genetic factors, specifically a lethal gene (Loje, 1930, *Tidskr. Landokonomi* 10: 517–549; Hertig and Sheldon, 1943, *Ann. Surg.* 117: 596–606; Gilmore, 1952, *Dairy Cattle Breeding*, J. B. Lippincott, New York, 604 pp.; Asdell, 1955, *Cattle Fertility and Sterility*, Little, Brown Co., Boston, Massachusetts, 277 pp.; Roberts, 1971,

Veterinary Obstetrics and Genital Diseases, Edwards Bros., Ithaca, New York, 776 pp.; Lauritsen, 1976, *Acta Obstet. Gynecol. Scand.* 54: 261–264), but this may not be the case (Deaton et al., 1959, *J. Dairy Sci.* 43: 312; Davidson and Roberts, 1961, *Cornell Vet.* 51: 34–46; Novak and Woodruff, 1979, *Novak's Gynecologic and Obstetric Pathology*, 8th Ed., Philadelphia, W. B. Saunders Co., 795 pp.). Environment factors, more specifically the uterine environment, should be considered at the time of early and late fetal death, premature birth, and anatomical malformations (Erb and Morrison, 1957, *J. Dairy Sci.* 40: 1030–1035; Roberts, 1962, *J. Am. Vet. Med. Assoc.* 40: 691–698; Novak and Woodruff, 1979, *op. cit.*).

We would like to thank B. Fink at the Harvard Museum of Comparative Zoology for the loan of the two normal shark specimens, J. Zentz and D. Steele at Woods Hole Oceanographic Institution and A. Houston and S. Allen at Tuskegee Institute for technical assistance, A. Caldwell at Auburn University School of Veterinary Medicine, Department of Radiology for taking the radiographs and G. D'Audrea at the Veterinary Diagnostic Laboratories for reviewing the manuscript.

Journal of Wildlife Diseases, 19(2), 1983, pp. 158–159
© Wildlife Disease Association 1983

Hypermature Cataract in a Crested Mynah, *Leucopsar rothschildi*

R. E. Schmidt, Veterinary Sciences Division, USAF School of Aerospace Medicine, Aerospace Medical Division, AFSC, United States Air Force, Brooks Air Force Base, Texas 78235, USA

As cortical cataracts develop, there can be liquefactive necrosis of lens fibers. If the necrotic cortical material is lost through absorption or extrusion, hypermature cataract results, with a smaller than normal lens and wrinkled capsule (Hogan and Zimmerman, 1962, *Ophthalmic Pathology, An Atlas and Textbook*, 2nd Ed., W. B. Saunders, Philadelphia, Pennsylvania, pp. 666–671; Yanoff and Fine, 1975, *Ocular Pathology, A Text and Atlas*, Harper &

Row, Hagerstown, Maryland, pp. 371–375). Descriptions of cataracts in birds are infrequent, although they have been seen in older canaries, parrots and birds of prey (Arnall and Keymer, 1975, *Bird Diseases*, T.F.H. Publications, Neptune City, New Jersey, pp. 305–308). Inbreeding and local trauma have been suggested as possible causes (Petraik, 1969, *Diseases of Cage and Aviary Birds*, Lea & Febiger, Philadelphia, Pennsylvania, pp. 351–355). Other reported possible causes of avian lens opacity or cataract include avian encephalomyelitis virus, Vitamin E deficiency and possible genetic

Received for publication 26 July 1982.