



## **Renal Carcinoma in a Captive Edwards Lory (*Trichoglossus haematodus capistratus*)**

Authors: Hubbard, Gene B., and Fletcher, Kenneth C.

Source: Journal of Wildlife Diseases, 19(2) : 160-161

Published By: Wildlife Disease Association

URL: <https://doi.org/10.7589/0090-3558-19.2.160>

---

BioOne Complete ([complete.BioOne.org](https://complete.BioOne.org)) is a full-text database of 200 subscribed and open-access titles in the biological, ecological, and environmental sciences published by nonprofit societies, associations, museums, institutions, and presses.

Your use of this PDF, the BioOne Complete website, and all posted and associated content indicates your acceptance of BioOne's Terms of Use, available at [www.bioone.org/terms-of-use](https://www.bioone.org/terms-of-use).

Usage of BioOne Complete content is strictly limited to personal, educational, and non - commercial use. Commercial inquiries or rights and permissions requests should be directed to the individual publisher as copyright holder.

---

BioOne sees sustainable scholarly publishing as an inherently collaborative enterprise connecting authors, nonprofit publishers, academic institutions, research libraries, and research funders in the common goal of maximizing access to critical research.

## Renal Carcinoma in a Captive Edwards Lory (*Trichoglossus haematodus capistratus*)

**Gene B. Hubbard**, Veterinary Sciences Division, USAF School of Aerospace Medicine, Aerospace Medical Division, AFSC, United States Air Force, Brooks Air Force Base, Texas 78235, USA; and **Kenneth C. Fletcher**, San Antonio Zoological Gardens & Aquarium, 3903 N. St. Marys, San Antonio, Texas 78212, USA

Renal carcinomas are not common in domestic animals including chickens (Feldman and Olson, 1978, *In Diseases of Poultry*, 7th Ed., Hofstead et al. (eds.), Iowa State University Press, Ames, Iowa, pp. 897-902; Moulton, 1978, *Tumors in Domestic Animals*, 2nd Ed., University of California Press, Berkeley, California, pp. 288-294). They are relatively common in wild birds, especially psittacines (Ratcliffe, 1933, *Am. J. Cancer* 17: 116-135; Sanger, 1971, *In Infectious and Parasitic Diseases of Wild Birds*, 1st Ed., Davis et al. (eds.), Iowa State University Press, Ames, Iowa, pp. 319-322; Effron et al., 1977, *J. Natl. Cancer Inst.* 59: 185-198). This report describes a fatal renal carcinoma in a captive Edwards lory, a psittacine originating in the South Pacific.

A 16-yr-old female Edwards lory that had been acquired by the zoo in 1968, with no previous medical problems, was found moribund in the bottom of its cage in December of 1980.

The bird was administered heat therapy but died several hours later.

The bird was in good condition except for marked feather loss from the central breast region. Internally, the lungs were dark red and moist. The kidneys had bilateral, multiple, irregular, 2-4 mm diameter, pale white nodular masses within and projecting from their cortices. No other gross lesion was recognized.

Histologically, the nodular masses in the kidney were neoplasms. The component cells were variable from area to area. The interface between normal and neoplastic tissue was moderately distinct with both compression and invasion of normal tissue by the neoplastic tissue (Fig. 1). Irregular tubular structures were most common, but acinar and papillary formations and sheets of cells were also present (Fig. 2). A moderate fibrovascular stroma extended throughout the neoplasm. The tumor cells were anaplastic, round to oval or polygonal with distinct to indistinct cytoplasmic margins. The cytoplasm was generally clear to lightly eosinophilic or occasionally darkly eosinophilic, and

Received for publication 23 August 1982.



FIGURE 1. Note the compression and invasion of normal kidney by the neoplasm. H&E.  $\times 60$ .

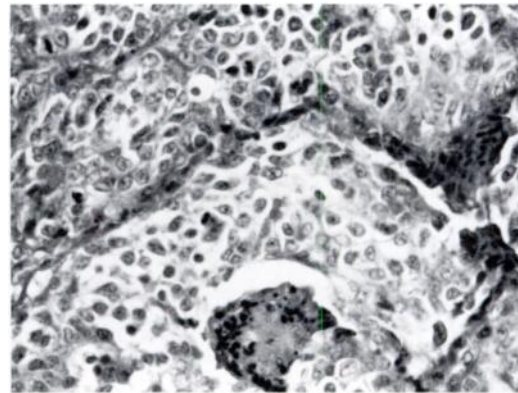


FIGURE 2. Tumor cells forming irregular tubular and acinar structures. Sheets of cells are prominent. H&E.  $\times 640$ .

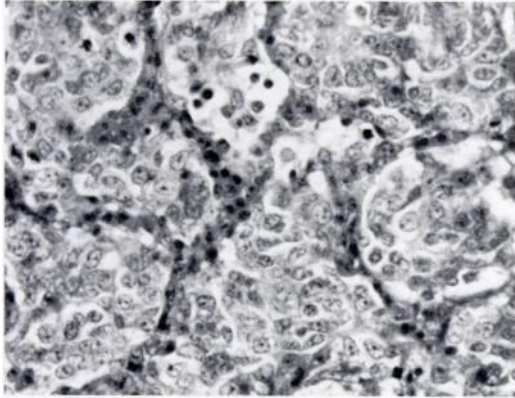


FIGURE 3. Anaplastic tumor cells displaying variability in size, shape and stain affinity. Note numerous mitotic figures. H&E.  $\times 640$ .

nuclei were round to oval, vesicular, and often had mitotic figures. The nucleoli were single or multiple, large, distinct, and frequently marginated (Fig. 3). The cells tended to pile and clump on basement membranes, and penetra-

tion into stromal connective tissues was frequent (Moulton, 1978, *op. cit.*). Occasional lymphocytes and plasma cells were present in the stroma, in necrotic foci and at the margins of the tumor nodules. Tumor cells were present in renal vessels. Multifocal mineral accumulations and bacterial colonies were in some tubular lumina. Metastatic tumor cells were in the smooth muscle wall and lamina propria of the oviduct with penetration and erosion of the epithelium. The vessels of the lung were markedly congested, and pigment-containing macrophage aggregations were adjacent to many airways. No metastatic tumor cell aggregates were found in the lung.

This renal carcinoma conformed well in both morphologic appearance and behavior to other documented cases (Ratcliffe, 1933, *op. cit.*; Sanger, 1971, *op. cit.*; Effron et al., 1977, *op. cit.*; Feldman and Olson, 1978, *op. cit.*; Moulton, 1978, *op. cit.*). It is interesting that the bird died rather suddenly with few discernable clinical signs.