



EXPERIMENTAL CONTAGIOUS ECTHYMA IN MULE DEER, WHITE-TAILED DEER, PRONGHORN AND WAPITI 1

Authors: Lance, William R., Hibler, Charles P., and DeMartini, James

Source: Journal of Wildlife Diseases, 19(3) : 165-169

Published By: Wildlife Disease Association

URL: <https://doi.org/10.7589/0090-3558-19.3.165>

BioOne Complete (complete.BioOne.org) is a full-text database of 200 subscribed and open-access titles in the biological, ecological, and environmental sciences published by nonprofit societies, associations, museums, institutions, and presses.

Your use of this PDF, the BioOne Complete website, and all posted and associated content indicates your acceptance of BioOne's Terms of Use, available at www.bioone.org/terms-of-use.

Usage of BioOne Complete content is strictly limited to personal, educational, and non - commercial use. Commercial inquiries or rights and permissions requests should be directed to the individual publisher as copyright holder.

BioOne sees sustainable scholarly publishing as an inherently collaborative enterprise connecting authors, nonprofit publishers, academic institutions, research libraries, and research funders in the common goal of maximizing access to critical research.

EXPERIMENTAL CONTAGIOUS ECTHYMA IN MULE DEER, WHITE-TAILED DEER, PRONGHORN AND WAPITI¹

William R. Lance,² Charles P. Hibler, and James DeMartini

Department of Pathology, Colorado State University, Fort Collins, Colorado 80523, USA

ABSTRACT: Hand-reared mule deer fawns (*Odocoileus hemionus*), white-tailed deer fawns (*Odocoileus virginianus*), pronghorn fawns (*Antilocapra americana*) and wapiti calves (*Cervus elaphus nelsoni*) were exposed to contagious ecthyma lesion material obtained from Rocky Mountain bighorn sheep (*Ovis canadensis canadensis*) to determine the susceptibility and pathogenesis in these species. All four species developed mucocutaneous proliferative lesions of the oral cavity, grossly and histologically compatible with contagious ecthyma. The limited clinical responses to the virus indicated that contagious ecthyma would not seriously impact free-ranging individuals.

INTRODUCTION

Contagious ecthyma (CE) is a viral disease of oral mucosa and skin, produced by members of the parapox group. Steeb described this disease among domestic sheep in Europe in 1789 (Abdussalam, 1957) but contagious ecthyma was not documented in North America until 1929 when it was first found in four flocks of domestic sheep (*Ovis aries*) in California (Howarth, 1929). Its first description in wildlife was in a herd of Rocky Mountain bighorn sheep in Canada in 1954 (Connell, 1954). Other outbreaks in wildlife species have been in chamois (*Rubricapra rubricapra*) (Kater and Hansen, 1962), steinbok (*Raphicerus campestris*) (Kater and Hansen, 1962), mountain goats (*Oreamnos americanus*) (Carr, 1968; Samuel et al., 1975; Hebert et al., 1977), California bighorn sheep (*Ovis canadensis californiana*) (Blaisdell, 1976), Dall's sheep (*Ovis dalli*) (Dieterich et al., 1981; Smith et al., 1982), musk ox (*Ovibos moschatus*) (Kummeneje and Krogsrud, 1978; Dieterich et al., 1981) and reindeer (*Rangifer tarandus*) (Kummeneje and Krogsrud, 1979).

During the fall of 1978 the Rocky Mountain bighorn sheep herds in the mountains near Saguache, Colorado, experienced an epizootic of contagious ecthyma (Lance et al., 1981). The spontaneous occurrence of this disease, previously unreported in the bighorn sheep of Colorado, prompted investigation of the potential

host range of this strain of contagious ecthyma virus for other native free-ranging ruminants of the state.

MATERIALS AND METHODS

Animal facilities

Trials were conducted at the Wild Animal Disease Center Foothills Facility, Fort Collins, Colorado. This facility consists of an 8-ha fenced enclosure containing a holding facility divided into three equal sections totaling 2.5 ha, an enclosure of 12 covered isolation pens, and four partially covered outside pens. The animals were fed a ration of leafy alfalfa hay supplemented with a specially mixed wildlife grain ration supplied by a local feed company (Ranch-Way, Inc., Fort Collins, Colorado 80523, USA). This facility had never housed animals with signs of a mucocutaneous proliferative disease.

Animals

Mule deer fawns, pronghorn fawns and wapiti calves were provided by the Colorado Division of Wildlife. They were born to free-ranging animals, picked up by private individuals as "orphans," and brought to local district game managers. All were maintained at the Wild Animal Disease Center Foothills Facility, and hand-reared.

Two white-tailed deer fawns from a captive herd were provided by the Oklahoma Cooperative Wildlife Research Unit, Stillwater, Oklahoma. The third was born to a free-ranging doe and provided by the Colorado Division of Wildlife.

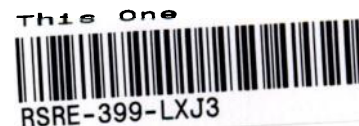Experimental exposure

In all trials, a 1-cm² area of upper oral mucosa, lateral nasal mucocutaneous junction, and axillary region were lightly scarified with a sterile 22 gauge needle and one drop of virus-containing inoculum applied. Each inoculum consisted of a 10% suspension of lesion material from a spontaneous bighorn sheep case (signal case), in sterile phosphate-buffered saline (PBS), with penicillin-G (100 IU/ml) and streptomycin (100 mg/ml). Viral particles morphologically compatible with parapox were observed in the lesion suspension, using negative contrast electron microscopy with potassium phosphotungstate stain.

Received for publication 13 September 1982.

¹ Contribution of and funded by Colorado Federal Aid in Wildlife Restoration Project and the Colorado State University Agricultural Experiment Station.

² Present address: Western Wildlife Laboratories, Inc., 1322 Webster Avenue, Fort Collins, Colorado 80524.



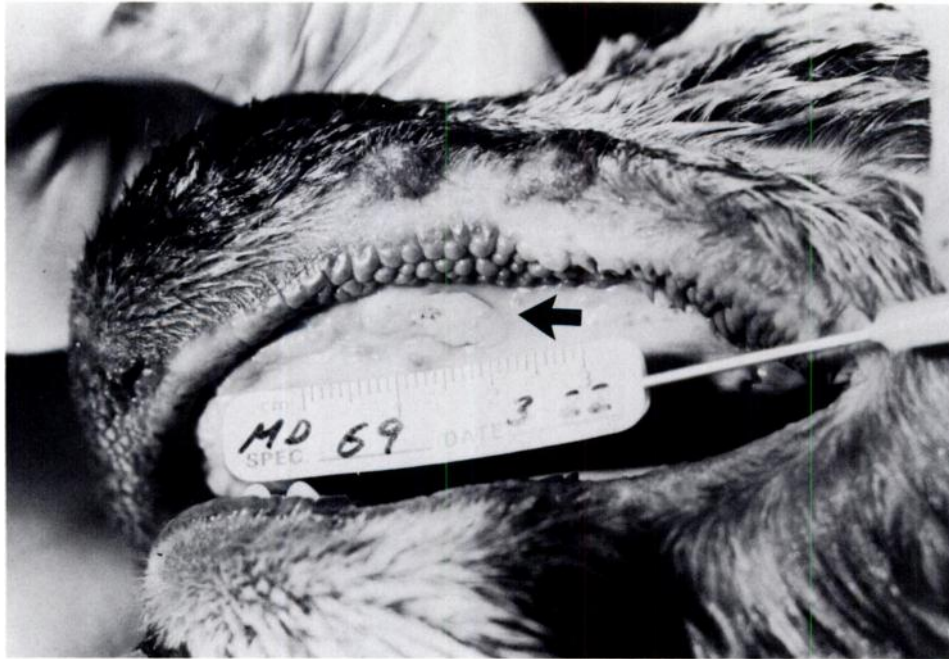

FIGURE 1. Lesions (arrow) of contagious ecthyma in oral cavity of a mule deer 10 days postexposure.

Three mule deer fawns, three pronghorn fawns, three wapiti calves and two white-tailed deer fawns were exposed to bighorn sheep signal case suspension at 10–12 wk of age. An additional animal of each of the above species of similar age was scarified only at the exposure sites and maintained separately as controls. One additional pronghorn and one mule deer were exposed to the lesion suspension and killed at the time of maximal lesion development to provide material for electron microscopy and histological examination.

Each animal was carefully examined prior to exposure for active or healed lesions of contagious ecthyma. Photographs were taken for supporting evi-

dence. All animals were observed closely for lesion development and regression.

Histological and ultrastructural pathology

Tissues for electron microscopy were trimmed to less than 1 mm thickness, fixed in buffered 3% glutaraldehyde for 2 hr, postfixed in osmium tetroxide and placed in successive changes of buffer. The tissue was embedded in Epon[®], sections cut, and stained with lead citrate and uranyl acetate. The sections were examined and photographed on a Hitachi model HU 12A electron microscope at 75 kV with a plate magnification of 2,500 to 42,000.

TABLE 1. Results of experimental exposure of 10–12 wk old wild ruminants to contagious ecthyma lesion material from bighorn sheep.

Species	Number of animals	Status	Lesion size at 9–11 days PE*	Secondary lesions
Mule deer	3	exposed	>1 cm	present
Mule deer	1	control	none	none
Wapiti	3	exposed	<1 cm	present in one individual
Wapiti	1	control	none	none
Pronghorn	3	exposed	>1 cm	present
Pronghorn	1	control	none	none
White-tailed deer	2	exposed	<1 cm	none
White-tailed deer	1	control	none	none

* PE = Postexposure.

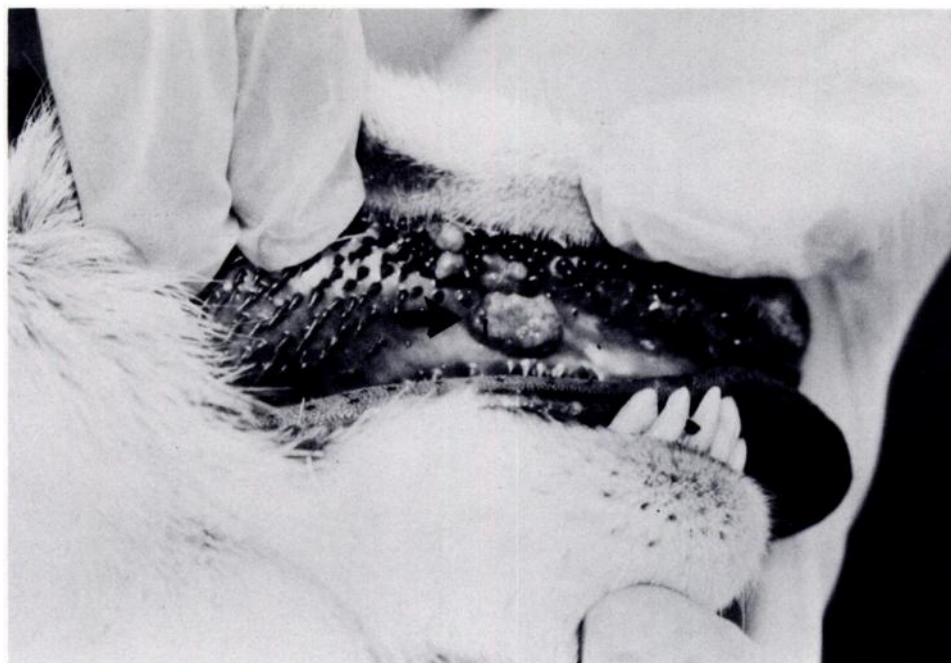


FIGURE 2. Lesions (arrow) of contagious ecthyma in oral cavity of a pronghorn 10 days postexposure.



FIGURE 3. Photomicrograph of lesion of contagious ecthyma in a mule deer 10 days postexposure. Note epidermal peg formation (arrow) (H&E). $\times 87$.

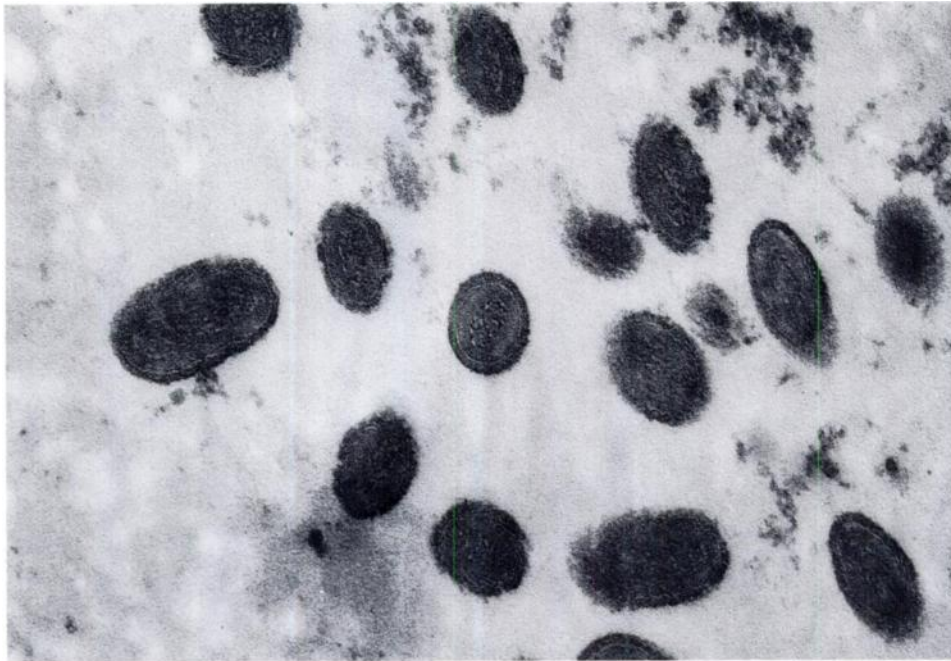

FIGURE 4. Viral particles in lesion of contagious ecthyma from a pronghorn 10 days postexposure. $\times 120,000$.

RESULTS

White-tailed deer and wapiti did not develop oral lesions larger than 0.5 cm at any exposure sites. Oral lesions reached maximum size in 9–11 days postexposure and completely regressed by 19 days postexposure. Secondary metastatic oral lesions occurred in only one wapiti. Lesions did not develop at the nasal or axillary exposure sites.

Pronghorn and mule deer developed lesions up to 1 cm in diameter at all exposure sites 9–11 days postexposure (Table 1). Grossly, oral lesions in these species were smooth, elevated, multilobulated, sharply delineated, cream-colored areas (Figs. 1, 2). Metastatic secondary lesions developed at corresponding sites on the lower lip in both species. Lesions in wapiti and white-tailed deer were of similar character but lesser in extent. Between 14–16 days postexposure, the lesions regressed. Scars or vitiliginous areas did not develop at lesion sites. Nasal and axillary exposure sites did not develop lesions. Scarified areas in control animals developed only transient inflammatory response which was completely resolved in 3–4 days.

Histologically, uncomplicated lesions in pronghorn and mule deer at 10–14 days postinfection were characterized by acanthotic epidermis with moderate epithelial peg formation penetrating the dermis (Fig. 3). Mononuclear cell infiltration of the dermis was mild to moderate. Ballooning degeneration was not prominent in any sections examined.

Pronghorn lesion material examined by electron microscopy contained epidermal cells undergoing degenerative changes with clusters of viral particles within damaged cytoplasm (Fig. 4). These large ovoid cytoplasmic particles had a dense, somewhat filamentous core surrounded by a homogeneous matrix. This core was enclosed by a narrow, clear, undulating band in some particles. A thick, dense outer shell covered the particles. Particles were not seen within the nucleus.

DISCUSSION

Results clearly indicated that white-tailed deer, mule deer, pronghorn and wapiti will develop lesions in response to lesion material containing contagious ecthyma virus (Table 1). In

pronghorn, the agent was demonstrated within lesion material by electron microscopy. Clinical response of these species is transient and very mild. The disease would probably be of minimal consequence to free-ranging animals.

Morphologically, lesions produced on oral mucosal surfaces in these animals differed grossly from those of bighorn sheep (Blaisdell, 1976) and domestic sheep (Howarth, 1929) in that they had a smooth, multilobulated, raised glistening character, compared to the more characteristic papillomatous lesion seen in the latter species. Histologically, lesions of mule deer and pronghorn differed from those described in domestic sheep by the conspicuous absence of significant areas of epidermal ballooning degeneration. Also, cytoplasmic inclusion bodies consistently described in domestic species could not be histologically demonstrated.

ACKNOWLEDGMENTS

The authors thank Dr. Stan Snyder, Dr. James England, and Dr. Len Pearson for support in electron microscopy, and Dr. A. Kocan of Oklahoma State University for assistance in obtaining white-tailed deer fawns. The valuable contribution of Dr. Robert Davies and Mr. Mike Miller of Colorado State University in assisting with animal trials is gratefully acknowledged.

LITERATURE CITED

- ABDUSSALAM, M. 1957. Contagious pustular dermatitis. II. Pathological histology. *J. Comp. Pathol.* 67: 217-222.
- BLAISDELL, J. 1976. The lava beds bighorn—So who worries? *Trans. Desert Bighorn Council.* p. 80.
- CARR, R. W. 1968. A case of orf contacted by a human from a wild Alaskan mountain goat. *Alaska Med.* 75-77.
- CONNELL, R. 1954. Contagious ecthyma in Rocky Mountain bighorn sheep. *Can. J. Comp. Med.* 18: 59.
- DIETERICH, R. A., G. R. SPENCER, D. BURGER, A. M. GALLINA, AND J. VANDERSCHALIE. 1981. Contagious ecthyma in Alaskan muskoxen and Dall sheep. *J. Am. Vet. Med. Assoc.* 179: 1140-1143.
- HEBERT, D. M., W. M. SAMUEL, AND G. W. SMITH. 1977. Contagious ecthyma in mountain goat of coastal British Columbia. *J. Wildl. Dis.* 13: 135-136.
- HOWARTH, J. A. 1929. Infectious pustular dermatitis of sheep and goats. *J. Am. Vet. Med. Assoc.* 29: 741-761.
- KATER, J. C., AND N. F. HANSEN. 1962. Contagious ecthyma in wild thar in the south island. *N.Z. Vet. J.* 10: 116-117.
- KUMMENEJE, K., AND J. KROGSRUD. 1978. Contagious ecthyma in musk ox. *Acta Vet. Scand.* 19: 461-462.
- , AND ———. 1979. Contagious ecthyma in reindeer. *Vet. Rec.* 105: 60-61.
- LANCE, W. R., W. ADRIAN, AND B. WIDHALM. 1981. An epizootic of contagious ecthyma in Rocky Mountain bighorn sheep in Colorado. *J. Wildl. Dis.* 17: 601-603.
- SAMUEL, W. M., G. A. CHALMERS, J. G. STELFOX, A. LOEWEN, AND J. J. THOMSEN. 1975. Contagious ecthyma in bighorn sheep and mountain goat in western Canada. *J. Wildl. Dis.* 11: 26-31.
- SMITH, T. C., W. E. HEIMER, AND W. J. FOREYT. 1982. Contagious ecthyma in an adult Dall sheep in Alaska. *J. Wildl. Dis.* 18: 111-112.