

## **HEMORRHAGIC ENTERITIS IN CAPTIVE AMERICAN KESTRELS (FALCO SPARVERIUS)**

Authors: Sileo, L., Franson, J. C., Graham, D. L., Domermuth, C. H., Rattner, B. A., et al.

Source: Journal of Wildlife Diseases, 19(3) : 244-247

Published By: Wildlife Disease Association

URL: <https://doi.org/10.7589/0090-3558-19.3.244>

---

BioOne Complete ([complete.BioOne.org](https://complete.BioOne.org)) is a full-text database of 200 subscribed and open-access titles in the biological, ecological, and environmental sciences published by nonprofit societies, associations, museums, institutions, and presses.

Your use of this PDF, the BioOne Complete website, and all posted and associated content indicates your acceptance of BioOne's Terms of Use, available at [www.bioone.org/terms-of-use](https://www.bioone.org/terms-of-use).

Usage of BioOne Complete content is strictly limited to personal, educational, and non - commercial use. Commercial inquiries or rights and permissions requests should be directed to the individual publisher as copyright holder.

---

BioOne sees sustainable scholarly publishing as an inherently collaborative enterprise connecting authors, nonprofit publishers, academic institutions, research libraries, and research funders in the common goal of maximizing access to critical research.

## HEMORRHAGIC ENTERITIS IN CAPTIVE AMERICAN KESTRELS (*FALCO SPARVERIUS*)

L. Sileo,<sup>1,4</sup> J. C. Franson,<sup>1</sup> D. L. Graham,<sup>2</sup> C. H. Domermuth,<sup>3</sup> B. A. Rattner,<sup>1</sup> and O. H. Pattee<sup>1</sup>

**ABSTRACT:** Hemorrhagic enteritis and hepatitis of suspected adenovirus etiology were the apparent cause of death of nine captive American kestrels. Cloacal hemorrhage was the only prominent gross lesion; disseminated hepatocellular necrosis, and intranuclear inclusion bodies were evident microscopically. Electron microscopy revealed numerous adenovirus-like particles associated with the hepatic lesions. Attempts to serologically identify the agent were unsuccessful.

### INTRODUCTION

Breeding colonies of several species of wild birds are maintained at the Patuxent Wildlife Research Center (PWRC) for experimental evaluation of environmental contaminants. In the winter of 1978, unusually high losses occurred in the colony of American kestrels and hemorrhagic enteritis and inclusion body hepatitis was diagnosed. Inclusion body hepatitis is not uncommon in raptors and other birds and is usually caused by herpesvirus infection (Leibovitz, 1971; Burki et al., 1973; Graham et al., 1975; Sileo et al., 1975; Simpson et al., 1975). This report presents data suggesting an adenovirus etiology for the observed disease in these captive kestrels.

### MATERIALS AND METHODS

About 250 kestrels were maintained in groups of two to eight birds of mixed sex and age in 15.3 × 3.1 × 1.8 m outdoor flight cages. The kestrels were fed Nebraska Bird of Prey diet (Animal Spectrum, Inc., Lincoln, Nebraska 68516, USA) and day-old chick carcasses culled from a local hatchery (Bowman's Hatchery, Westminster, Maryland 21157, USA).

The sex, age, body condition, and lesions in each carcass were recorded at necropsy. Blood smears from three kestrels were stained with Camco Quik Stain (Cambridge Chemical Products, Inc., Fort Lauderdale, Florida 33310, USA) and examined for imma-

ture erythrocytes. Scrapings of the intestinal contents of three kestrels were examined microscopically for parasites. The liver, spleen, or intestinal contents of three kestrels were submitted to the Animal Health Laboratory, Maryland Department of Agriculture, for bacteriological tests using blood and MacConkey's agar. Autolysis prevented microscopic examination of two carcasses but tissues from seven were fixed in buffered 10% formalin and were processed and stained by hematoxylin and eosin. Formalin-fixed tissue from three kestrels was transferred to 2% glutaraldehyde, post-fixed in 1% osmium tetroxide, embedded in Epon 812 resin, sectioned on an ultramicrotome, and stained with lead citrate and uranyl acetate before electron microscopic examination.

In October and November, 47 wk after the initial deaths occurred, 14 kestrels which had been residents of the colony during the epizootic were bled by jugular venipuncture and sera were tested for the presence of antibody to group II avian adenoviruses (Domermuth and Gross, 1980).

An attempt to uncover subclinical infection by chemically induced immunosuppression was made in November. Six male kestrels which had been colony residents during the epizootic were placed in 0.68 × 0.68 × 0.22 m indoor battery cages. Three of these birds received daily subcutaneous injections of 8 mg/kg dexamethasone (H-L Dex<sup>®</sup>, Cutter Laboratories, Inc., Shawnee, Kansas 66201, USA) for 7 consecutive days, and three of the birds were similarly dosed with an equal volume of sterile lactated Ringer's solution. This technique is commonly employed to unmask subclinical virus infections and is especially useful for subclinical or latent herpesvirus (Mushi et al., 1979). On day 8 the kestrels were bled by jugular venipuncture and the plasma was stored at -80 C for corticosterone determination to confirm the anti-inflammatory effect of the treatment. Plasma corticosterone concentration was quantified by radioimmunoassay (Rattner and Eastin, 1981).

At day 11 a moribund kestrel was bled and examined. On day 15 the remaining kestrels were bled and euthanatized with halothane. Packed cell volume (PCV) was determined by microhematocrit and hemoglobin (Hb) was measured by the cyanomet-hemoglobin procedure (Hycell Kits 116 and 117, Hycel, Inc., Houston, Texas 77036, USA).

Case records from the PWRC pathology files were reviewed to determine if the disease had been detected previously in the kestrel colony.

Received for publication 19 November 1982.

<sup>1</sup> Patuxent Wildlife Research Center, U.S. Fish and Wildlife Service, Laurel, Maryland 20708, USA.

<sup>2</sup> Department of Avian & Aquatic Animal Medicine, New York State College of Veterinary Medicine, Cornell University, Ithaca, New York 14853, USA.

<sup>3</sup> Virginia-Maryland Regional College of Veterinary Medicine, Virginia Polytechnic Institute and State University, Blacksburg, Virginia 24061, USA.

<sup>4</sup> Present address: National Wildlife Health Laboratory, U.S. Fish and Wildlife Service, 6006 Schroeder Road, Madison, Wisconsin 53711, USA.

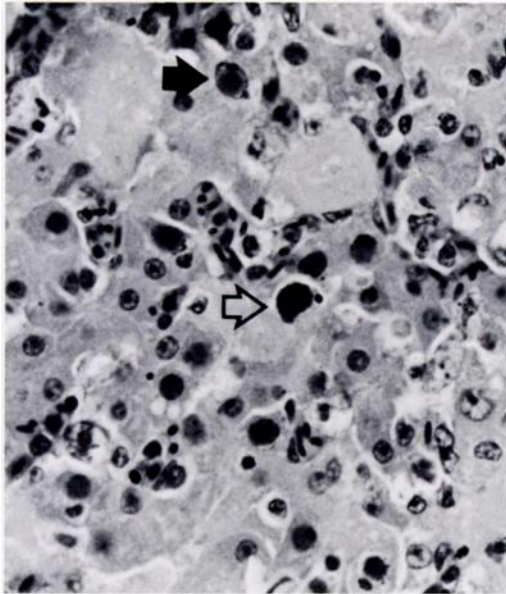


FIGURE 1. Liver with diffuse coagulation necrosis. Black arrow indicates an eosinophilic inclusion body and clear arrow indicates a basophilic inclusion body. H&E,  $\times 150$ .

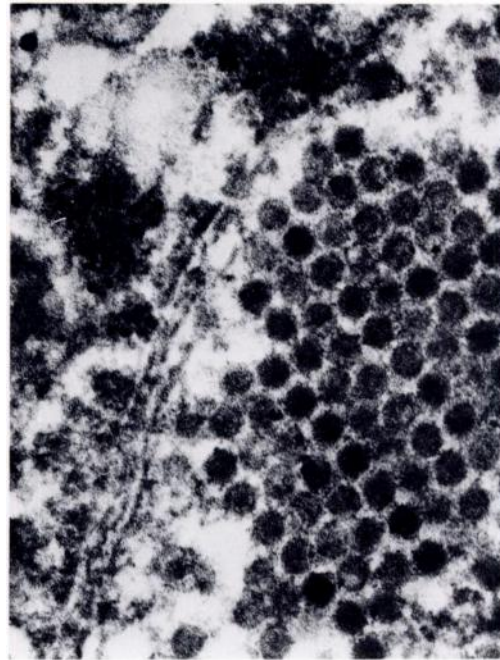


FIGURE 3. Hepatocyte nucleus with close-packed virions forming a crystalline array.  $\times 56,200$ .

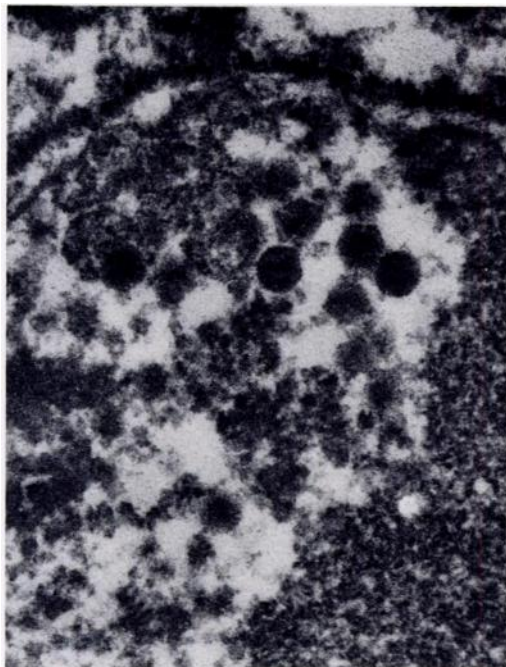


FIGURE 2. Hepatocyte nucleus with numerous intranuclear viral nucleocapsids with cubic symmetry and diameters of 73–80 nm.  $\times 82,200$ .

## RESULTS

Hemorrhagic enteritis and inclusion body hepatitis were diagnosed in eight of 13 carcasses examined during the winter of 1978 and in a kestrel which succumbed the following July. Adult and juvenile kestrels of both sexes succumbed during the epizootic. Some of the birds were in good flesh and others were in poor flesh. The pertinent gross lesions were swollen spleens with prominent white pulp, petechiae to extravasations in the colon, coprodeum, and urodeum fold, and bloody feces. In two kestrels petechiae were evident in esophageal mucosa and in a third kestrel petechiae were present in the bursa of Fabricius. Moderate to severe, diffuse, nonzonal hepatocellular necrosis associated with intranuclear inclusion bodies was present in each of seven kestrels (Fig. 1). Two types of nuclear inclusions were present. One type had a central irregular eosinophilic mass widely separated from the nuclear membrane (Cowdry Type A, Fig. 1). The second type were in enlarged nuclei with intensely basophilic, margined, chromatin and were contiguous, homogeneous, basophilic masses either completely filling the

TABLE 1. Hematological and corticosterone data for kestrels after treatment with dexamethasone.

Bird no	Treatment	1 day post-treatment	8 days post-treatment	
		Corticosterone (ng/ml)	PCV (%)	Hb (g/dl)
89	Lactated Ringer's	17.3	49.0	16.3
92	Lactated Ringer's	15.6	52.0	17.2
90	Lactated Ringer's	11.1	48.0	14.9
Mean $\pm$ SD		14.7 $\pm$ 3.2*	49.7 $\pm$ 2.1	16.1 $\pm$ 1.2*
87	8 mg/kg dexamethasone	3.2	48.0	14.2
88	8 mg/kg dexamethasone	1.5	45.0	13.8
91	8 mg/kg dexamethasone	4.3	45.0	14.2
Mean $\pm$ SD		3.0 $\pm$ 1.4*	46.0 $\pm$ 1.7	14.1 $\pm$ 0.2*

\* One-way analysis of variance revealed significant differences between means ( $P < 0.05$ ).

nuclear space or separated from the nuclear membrane by a narrow space (Cowdry Type B, Fig. 1). Some enlarged nuclei had distinctive densely basophilic, stellate, protrusions from the nuclear membranes.

No coccidia or helminths were noted in intestinal contents and only normal bacterial flora were isolated. Subjective evaluation of the high density of polychromatic erythrocytes in blood smears suggested that the kestrels had a regenerative anemia. Numerous mononuclear blast cells in vessel lumina noted in H&E sections were additional evidence of an anemia. Other microscopic lesions associated with the disease in one or more kestrels were disseminated intravascular thrombosis and bursal and myocardial necrosis.

Transmission electron microscopy of liver tissue from three kestrels revealed numerous intranuclear viral nucleocapsids with cubic symmetry and diameters of 73 to 80 nm (Fig. 2). There were occasional examples of clustering of virions into crystalline arrays (Fig. 3). No virus particles were found in the perinuclear spaces or cytoplasm and there were no enveloped virions. The size, morphology, and exclusive intranuclear location of the virus particles, and their tendency to form crystalline arrays, are characteristics most suggestive of adenoviruses.

Agar gel precipitin tests of post-epizootic sera against group II avian adenovirus were uniformly negative. The PCV and Hb were lower and plasma corticosterone concentrations were reduced in the dexamethasone treated kestrels (Table 1), but there was no clinical, gross, or microscopic evidence of the disease. Hemor-

rhagic enteritis was diagnosed for three of 98 kestrel accessions examined at PWRC between 1950 and 1975. The liver of one of these accessions was microscopically normal and there was no liver section for the second. In the third, gross and microscopic lesions, including the presence of intranuclear inclusion bodies, were essentially identical to the recent cases.

#### DISCUSSION

Several differences exist between the present PWRC kestrel disease and the previously reported inclusion body hepatitis caused by herpesviruses in raptors:

1) Macroscopically the PWRC kestrel livers were unremarkable; herpesvirus infection in birds usually produces obvious macroscopic focal necrosis (Leibovitz, 1971; Burki et al., 1973; Graham et al., 1975; Sileo et al., 1975; and Simpson et al., 1975).

2) Microscopically the PWRC kestrel liver lesions were diffuse whereas those of herpesvirus infection in raptors are usually focal (Leibovitz, 1971; Burki et al., 1973; Graham et al., 1975; Sileo et al., 1975; Simpson et al., 1975).

3) The prominent gross lesion in the PWRC kestrels was lower intestinal hemorrhage, which is not a prominent feature of falconiform herpetic disease.

4) Electron microscopy of PWRC kestrel liver tissue revealed a virus suggestive by its site, size, and morphology of an adenovirus. No virus particles of the size or morphology of herpesviruses were found.

Because the causative agent of this kestrel disease was not isolated and characterized, it is not possible to determine a definitive etiologic

diagnosis. We suggest, however, that avian group II adenovirus infection (hemorrhagic enteritis of turkeys and marble spleen disease of pheasants) be considered when differential diagnosis is made in future cases of inclusion body hepatitis in kestrels. Spleen samples obtained at necropsy should be employed for animal inoculation (kestrels, turkey poults and other Galliformes) and sera from penmates should be obtained several weeks after death of affected birds to determine if seroconversion has occurred.

#### ACKNOWLEDGMENTS

Ancillary bacteriological tests were conducted by Mrs. D. White of the Maryland Department of Agriculture.

#### LITERATURE CITED

- BURKI, F., H. BURTSCHER, AND M. SIBALIN. 1973. *Herpesvirus strigis*: A new avian herpesvirus. Arch. Gesamte Virusforsch. 43: 14-24.
- DOMERMUTH, C. H., AND W. B. GROSS. 1980. Hemorrhagic enteritis of turkeys. In Isolation and Identification of Avian Pathogens (2nd Ed.), S. B. Hitchner, C. H. Domermuth, H. G. Purchase, and J. E. Williams (eds.), Am. Assoc. Avian Pathol., College Station, Texas, pp. 106-107.
- GRAHAM, D. L., C. J. MARE, F. PRESCOTT WARD, AND M. C. PECKHAM. 1975. Inclusion body disease (herpesvirus infection) of falcons (IBDF). J. Wildl. Dis. 11: 83-91.
- LEIBOVITZ, L. 1971. Duck plague. In Infectious and Parasitic Diseases of Wild Birds, J. W. Davis, R. C. Anderson, L. Karstad, and D. O. Trainer (eds.), Iowa State University Press, Ames, Iowa, pp. 22-33.
- MUSHI, E. Z., L. KARSTAD, D. M. JESSETT, AND P. B. ROSSITER. 1979. Observations on the epidemiology of the herpesvirus of infectious bovine rhinotracheitis/infectious pustular vulvovaginitis in wildebeest. J. Wildl. Dis. 15: 481-487.
- RATTNER, B. A., AND W. C. EASTIN, JR. 1981. Plasma corticosterone and thyroxin concentrations during chronic ingestion of crude oil in mallard ducks (*Anas platyrhynchos*). Comp. Biochem. Physiol. 68C: 103-107.
- SILEO, L., H. C. CARLSON, AND S. C. CRUMLEY. 1975. Inclusion body disease in a great horned owl. J. Wildl. Dis. 11: 92-96.
- SIMPSON, C. F., J. E. HANLEY, AND J. M. GASKIN. 1975. Psittacine herpesvirus infection resembling Pacheco's parrot disease. J. Infect. Dis. 131: 390-396.