

## **Oxalate Toxicity in a Scaly-tailed Possum, a Patagonian Cavy and a Swamp Wallaby**

Authors: Ellis, T. M., Copland, M. D., and Gaynor, W. T.

Source: Journal of Wildlife Diseases, 19(3) : 290-293

Published By: Wildlife Disease Association

URL: <https://doi.org/10.7589/0090-3558-19.3.290>

---

BioOne Complete ([complete.BioOne.org](https://complete.BioOne.org)) is a full-text database of 200 subscribed and open-access titles in the biological, ecological, and environmental sciences published by nonprofit societies, associations, museums, institutions, and presses.

Your use of this PDF, the BioOne Complete website, and all posted and associated content indicates your acceptance of BioOne's Terms of Use, available at [www.bioone.org/terms-of-use](https://www.bioone.org/terms-of-use).

Usage of BioOne Complete content is strictly limited to personal, educational, and non - commercial use. Commercial inquiries or rights and permissions requests should be directed to the individual publisher as copyright holder.

---

BioOne sees sustainable scholarly publishing as an inherently collaborative enterprise connecting authors, nonprofit publishers, academic institutions, research libraries, and research funders in the common goal of maximizing access to critical research.

Research was supported by the U.S. Fish and Wildlife Service (contract #14-16-008-2079) and the University of Wisconsin, Stevens Point

The authors thank Ruth Duncan and Douglas Docherty of the National Wildlife Health Laboratory for laboratory assistance.

*Journal of Wildlife Diseases*, 19(3), 1983, pp. 290-293  
© Wildlife Disease Association 1983

## Oxalate Toxicity in a Scaly-tailed Possum, a Patagonian Cavy and a Swamp Wallaby

**T. M. Ellis, M. D. Copland**, Animal Health Laboratories, Department of Agriculture, Jarrah Road, South Perth, Western Australia 6151, Australia; **and W. T. Gaynor**, Zoological Gardens Board, 20 Labouchere Road, South Perth, Western Australia 6151, Australia

In Australia oxalate-containing plants of the families Oxalidaceae and Chenopodiaceae have been shown to be toxic to livestock (Seawright, 1982, *Animal Health in Australia*, Vol. 2, Chemical and Plant Poisons, Australian Government Printing Service, Canberra, pp. 74-76). Osteodystrophia fibrosa resulting from ingested oxalates interfering with calcium availability has occurred in horses grazing *Panicum maximum* var. *trichoglume* (green panic), *Cenchrus ciliaris* (buffet grass), *Setaria anceps* (setaria), *Brachiaria mutica* (para grass) and *Pennisetum clandestinum* (kikuyu) pastures (Groenendyk and Seawright, 1974, *Aust. Vet. J.* 50: 131-132; Walthal and McKenzie, 1976, *Aust. Vet. J.* 52: 11-16). There has been one confirmed report of oxalate nephrosis in cattle grazing *Setaria anceps* (Bua River strain) in Queensland (Seawright et al., 1970, *Aust. Vet. J.* 46: 293-296). The lesions associated with oxalate toxicity in man, cats and dogs from the ingestion of ethylene glycol (antifreeze) are oxalate nephrosis and renal failure (Kersting and Nielsen, 1965, *J. Am. Vet. Med. Assoc.* 146: 113-118; Kersting and Nielsen, 1966, *Am. J. Vet. Res.* 27: 574-582).

Three cases of oxalate toxicity occurred within a 4 mo period at the Zoological Gardens in Perth, Western Australia. The first was in a scaly-tailed possum (*Wyulda squamicaudata*), a cave-dwelling marsupial found in the Kimberley region of Western Australia and rarely ex-

hibited in captivity. The possum was one of a pair presented to the Zoological Gardens in 1977 and placed on exhibition in the nocturnal house. The male died in 1981 of undetermined causes. The female remained the sole occupant of the enclosure until a banded hare-wallaby (*Lagostrophus fasciatus*) was introduced 7 mo prior to the possum's death. The diet of the possum prior to the wallaby's arrival contained no freshly cut grasses. With the addition of the wallaby to the enclosure freshly cut grasses were included in the feed. No signs of ill health were observed in the animals prior to being housed together. The initial sign noted in the possum was lethargy. Twenty-four hr later the keeper noticed an unusual hopping gait and 48 hr later the animal was found recumbent with intermittent episodes of myoclonus. The possum became moribund and died within 90 min. The second oxalate toxicity was in a Patagonian cavy (*Dolichotis patagona*). These cavies are plain-dwellers from Argentina and the Patagonian area of South America and this animal was one of a colony at the zoo. It was found in a comatose state and was destroyed. There had been no history of ill health in this animal. The diet was similar to that provided for the possum including provision of freshly cut green grasses. A third case of oxalate toxicity occurred in a swamp wallaby (*Wallabia bicolor*) which is a forest-dwelling wallaby often found near creeks and swamps in the eastern States of Australia. This wallaby had developed lumpy jaw and was placed in an isolation pen where the jaw lesion was being treated by debridement and injec-

Received for publication 11 October 1982.

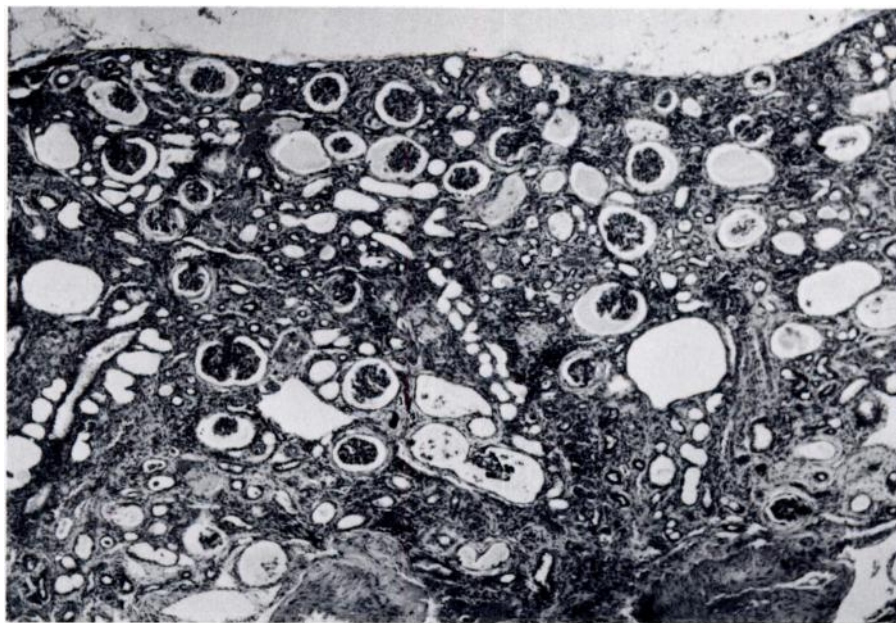


FIGURE 1. Renal cortex of scaly-tailed possum with severe nephrosis. H&E,  $\times 100$ .

tions of chloramphenicol succinate of rolitetracycline (Proterciline-V2000, Arnolds). The lesion appeared to be responding but the wallaby was found dead on the thirteenth day in the isolation pen.

Necropsy of the scaly-tailed possum revealed an area of ulcerative glossitis involving the distal third of the tongue, and a congested liver with accentuated lobular pattern throughout. No other gross changes were detected. Histological examination of the kidneys showed widespread, marked dilatation of renal tubules, distention of Bowman's capsule with proteinaceous fluid and a generalized increase of fibroblasts, collagen and mononuclear inflammatory cells in the interstitium (Fig. 1). Many of the distended renal tubules contained large masses of birefringent crystals either alone or in proteinaceous or cellular casts (Fig. 2). The crystals stained positively for calcium oxalate using Pizzolato's method (Pizzolato, 1964, *J. Histochem. Cytochem.* 12: 333-336) (Fig. 3). In the liver there was marked centrilobular congestion, some periportal bile duct proliferation, lymphocyte accumulation and vacuolation of hepatocytes. Lesions in the tongue consisted of zones of acantholysis with some necrosis and a heavy neutrophil infiltration of the mucosa. In some of these areas the lesion had progressed to form

microabscesses and in others the stratum corneum was eroded. There was also a marked neutrophil infiltrate in the submucosa and muscle layers. In the stomach some hyperplasia of the mucus neck cells was present and there were erythrocytes and proteinaceous exudate mixed with mucus on the mucosal surface. In the congested mucosa areas of suspected calcification were observed and these were confirmed using Von Kossa's technique (Mallory, 1961, *Pathological Technique*, Hafner Publishing Co., New York, pp. 144-145). In the villi of the small intestine a proteinaceous exudate and cellular debris had collected below the basement membrane of the surface epithelium. Lungs were congested and areas of fibrosis without mineralization or macrophage aggregation were observed in the myocardium. No lesions were detected in the brain and spinal cord. Bacteriologic examination of heart blood, liver and duodenal fluid resulted in isolation of *Escherichia coli* from liver and duodenal fluid. The gross pathology of the Patagonian cavy was unremarkable but it was noted that ribs and long bones appeared weaker and had thinner cortices than similar bones in small domestic animals. Histopathologic examination of the kidneys showed areas of cortical fibrosis, tubular dilatation and the presence of proteinaceous material and

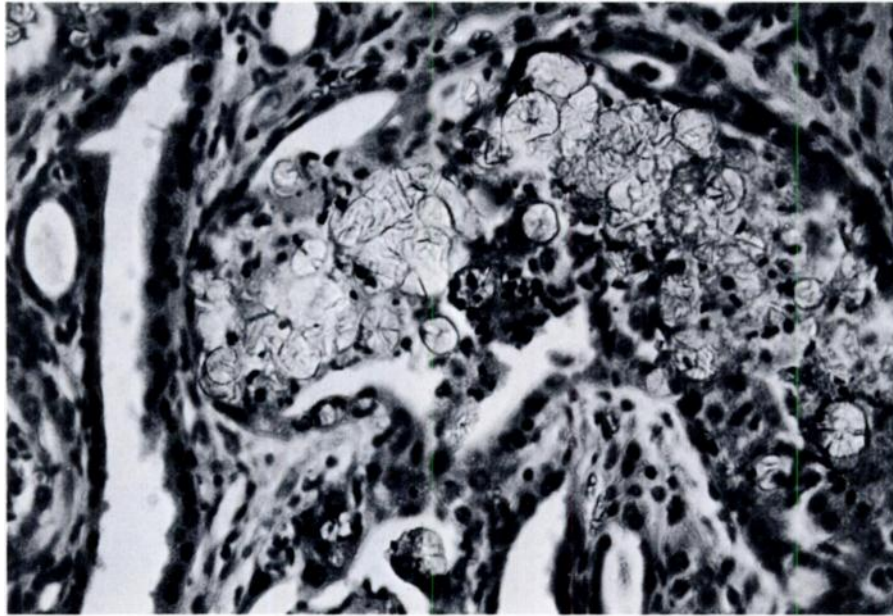


FIGURE 2. Dilated renal tubules containing oxalate crystals in scaly-tailed possum. H&E,  $\times 400$ .

crystalline deposits within some tubules. The crystalline deposits reacted positively with Pizzolato's stain for calcium oxalate (Pizzolato, 1964, *op. cit.*). In the upper small intestine nu-

merous helminth parasites were seen in both the lumen and the mucosa. Surface necrosis of villi with aggregates of macrophages in the lamina propria was observed in the lower small

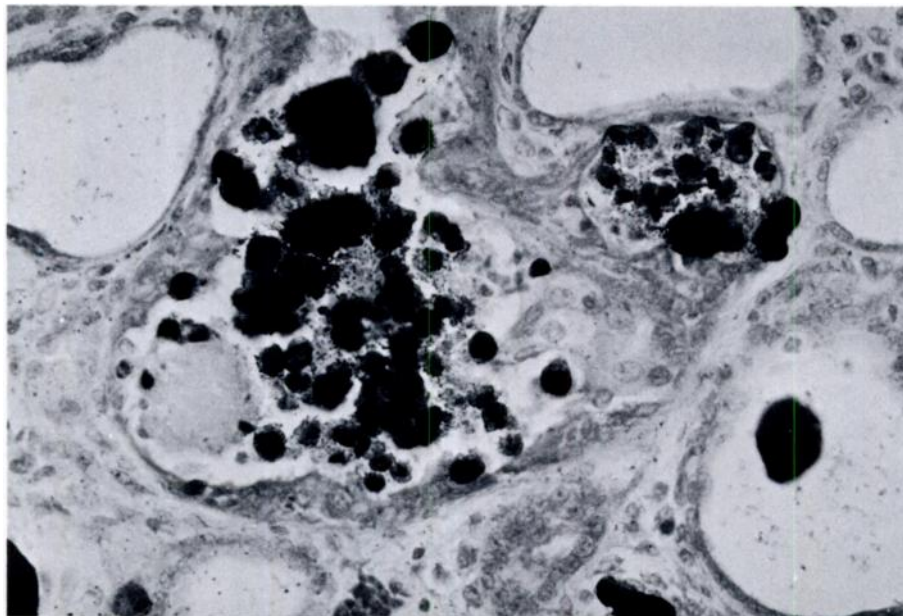


FIGURE 3. Calcium oxalate crystals in dilated renal tubules in scaly-tailed possum. Pizzolato's method,  $\times 400$ .

intestine. *Salmonella oslo* was isolated from the large intestine. Acute hyaline degeneration of many muscle fibers was observed in the hindlegs similar to exertional rhabdomyolysis (Bartsch et al., 1977, Vet. Pathol. 14: 314–324). Some affected fibers were infiltrated by macrophages. No evidence of osteodystrophia fibrosa, osteoporosis or osteomalacia was observed in the tibia. Gross pathological findings in the swamp wallaby included stippling of the surface of the kidney with streakiness of the cortex on the cut surface, and accentuated lobular markings of the liver. Histopathologic examination revealed a severe tubular nephrosis with marked hyperemia, masses of oxalate crystals in tubules and many tubules distended with proteinaceous material or necrotic debris. There was minimal inflammatory response in the interstitial areas and no evidence of fibroplasia. Congestion was marked centrilobularly in the liver and in the adrenal medulla. The superficial gastric mucosa was congested but no metastatic calcification was present in the deeper mucosa. Meningeal blood vessels were congested and there were some focal hemorrhages but no oxalate crystals in the brain. Bacteriologic examination of heart blood, liver and swabs from the lumpy jaw lesion revealed no significant pathogens.

The severity of the oxalate nephrosis and changes in the mucosa of tongue and stomach suggest the scaly-tailed possum died from uremia of renal origin (Jubb and Kennedy, 1970, Pathology of Domestic Animals, Academic Press, New York, pp. 329–332). The absence of lesions in the central nervous system suggests the neurologic signs were associated with uremia. The Patagonian cavy however had less severe lesions of oxalate nephrosis but evidence of gastrointestinal parasitism, enteritis and myopathy. The bone weakness noticed grossly

could not be confirmed histologically. In the past cavies have fractured long bones during flight, when disturbed. The swamp wallaby also had a severe oxalate nephrosis but the histology indicated a more acute course than in the case of the scaly-tailed possum. Possible sources of oxalates in the diet of the animals were examined. In the enclosures for the scaly-tailed possum and the Patagonian cavies there were no oxalate-containing plants and no source of ethylene glycol available. However, the fresh grass fed to the animals was often kikuyu and in some areas where kikuyu was cut, soursob (*Oxalis pes-caprae*) was growing also and could have been included inadvertently with the grass cuttings. The isolation pen where the swamp wallaby was being treated contained several clumps of soursob growing in the dense swath of kikuyu. No oxalate-containing plants were present in the pens where the remainder of the wallaby colony was kept. The more acute features of nephrosis in the wallaby were consistent with the duration of exposure to a source of oxalate-containing plants. The level of oxalate in soursob has been reported as reaching the equivalent of 14.6% oxalic acid (dry-basis) (Gardner and Bennets, 1956, The Toxic Plants of Western Australia, West Australian Newspapers, Perth, pp. 116–119). Kikuyu has also been reported to contain a low level of oxalate at 0.3% (dry-basis) soluble oxalate. Some other grasses, for example *Setaria anceps* (Bua River strain), have had oxalate levels up to 6.9% of which 90% was water soluble (Walthal and McKenzie, 1976, Aust. Vet. J. 52: 11–16). Evidence indicates that the three animals had a source of oxalate available in their diet which resulted in oxalate toxicity.

We thank Mrs. Julie Fry for the preparation of the histologic sections and Mrs. Julie Lloyd for the bacteriologic examinations.