



METORCHIS CONJUNCTUS (COBBOLD, 1860) INFECTION IN WOLVES (CANIS LUPUS), WITH PANCREATIC INVOLVEMENT IN TWO ANIMALS

Authors: Wobeser, Q., Runge, W., and Stewart, R. R.

Source: Journal of Wildlife Diseases, 19(4) : 353-356

Published By: Wildlife Disease Association

URL: <https://doi.org/10.7589/0090-3558-19.4.353>

BioOne Complete (complete.BioOne.org) is a full-text database of 200 subscribed and open-access titles in the biological, ecological, and environmental sciences published by nonprofit societies, associations, museums, institutions, and presses.

Your use of this PDF, the BioOne Complete website, and all posted and associated content indicates your acceptance of BioOne's Terms of Use, available at www.bioone.org/terms-of-use.

Usage of BioOne Complete content is strictly limited to personal, educational, and non - commercial use. Commercial inquiries or rights and permissions requests should be directed to the individual publisher as copyright holder.

BioOne sees sustainable scholarly publishing as an inherently collaborative enterprise connecting authors, nonprofit publishers, academic institutions, research libraries, and research funders in the common goal of maximizing access to critical research.

METORCHIS CONJUNCTUS (COBBOLD, 1860) INFECTION IN WOLVES (*CANIS LUPUS*), WITH PANCREATIC INVOLVEMENT IN TWO ANIMALS

G. Wobeser,¹ W. Runge,² and R. R. Stewart³

ABSTRACT: The trematode *Metorchis conjunctus* (Cobbold, 1860) was found in seven of 211 wolves from Saskatchewan which were examined between 1976 and 1983. The parasite caused cholangiohepatitis with periductular fibrosis in the liver of all the wolves, and chronic inflammation and fibrosis of the pancreas in two animals. The wolves with pancreatic involvement were emaciated. Five of the seven infected wolves were from one local area, and three of these were from a pack known to consume fish.

INTRODUCTION

The trematode *Metorchis conjunctus* (Cobbold, 1860) is a parasite of the gallbladder and bile ducts of a variety of fish-eating mammals in North America, including man (Cameron, 1944; Mills and Hirth, 1968). The first intermediate host is the snail *Amnicola limosa*. The white sucker (*Catostomus commersoni*) serves as second intermediate host. Mammals are infected by eating fish containing encysted metacercariae. The distribution of *M. conjunctus* was defined as the portion of Canada bounded on the south by the Canadian border and the St. Lawrence River, on the west by the height of land in Saskatchewan (the western extent of the Hudson Bay watershed), and by the border of the Northwest Territories on the north (Cameron et al., 1940). Cases have been reported occasionally from outside this area, including raccoons (*Procyon lotor*) in Maine (Meyer, 1949), a gray fox (*Urocyon cinereogentus*) and mink (*Mustela vison*) in Connecticut (Mills and Hirth, 1968) and a dog in South Carolina (Jordan and Ashby, 1957). The parasite is common in working dogs fed fish in northern Canada (Mongeau, 1961; Unruh et al., 1972). The single report of infection in a wolf (*Canis lupus*) was by Holmes and Podesta (1968), who found *M. conjunctus* in one of 98 wolves from Alberta. The infected individual came from eastern Al-

berta in a watershed draining into Hudson Bay (i.e., east of the height of land defined earlier as the western boundary of the parasite's range). This paper describes the occurrence of *M. conjunctus* in wolves in Saskatchewan with emphasis on two cases in which the pancreas, as well as the liver, was involved.

METHODS AND MATERIALS

Between January 1976 and April 1983, 211 wolves were submitted for necropsy to the Department of Veterinary Pathology, Western College of Veterinary Medicine. These came from throughout the commercial forest zone that runs diagonally across Saskatchewan between approximately 52 to 55° latitude on the east, and 54 to 57° latitude on the western side of the province. Some of the animals were submitted as diagnostic cases because of suspected disease, but the majority were collected from trappers and resource officers as part of a study of other conditions in wolves. In most instances only a gross necropsy was performed; in selected cases, tissues were fixed in neutral buffered 10% formalin and processed for histology. Representative specimens of *M. conjunctus* from the liver and pancreas of a wolf examined April 1983 have been placed in the National Museum of Canada, Invertebrate Collection (Parasites), catalogue numbers NMC IC(P)1983-0373 and NMC IC(P)1983-0372, respectively.

RESULTS

Seven of the 211 wolves had grossly visible changes in the liver and gallbladder in association with trematodes that were identified as *M. conjunctus*. All of the infected animals were judged to be more than 1 yr of age, based on size, development and dentition. Five of the infected wolves were obtained from trappers and had no history of prior disease. Two of these were submitted in 1976 from the central portion of the province, north of Prince Albert, and from sites about 60 km apart. The other

Received for publication 21 January 1983.

¹ Department of Veterinary Pathology, Western College of Veterinary Medicine, University of Saskatchewan, Saskatoon, Saskatchewan S7N 0W0, Canada.

² Department of Tourism and Renewable Resources, Prince Albert, Saskatchewan S6V 1B5, Canada.

³ Department of Tourism and Renewable Resources, Melville, Saskatchewan S0A 2P0, Canada.

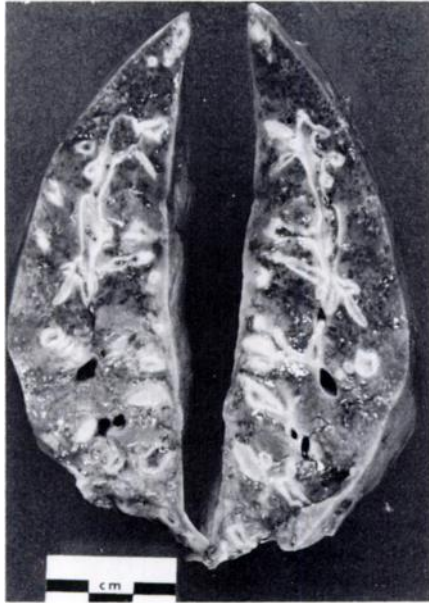


FIGURE 1. Cross sections of liver of wolf infected with *Metorchis conjunctus*. Intra-hepatic bile ducts are dilated and surrounded by fibrous tissue. Trematodes are evident in some ducts.

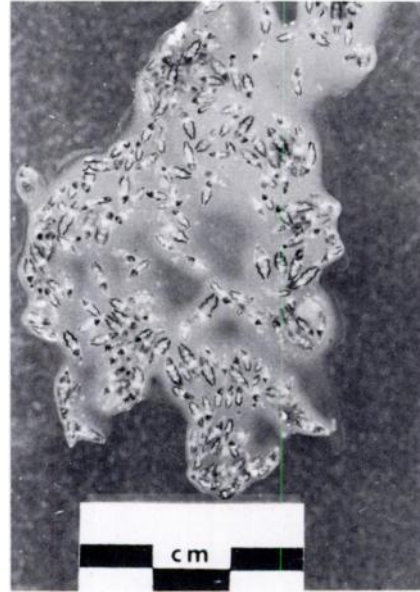


FIGURE 2. *Metorchis conjunctus* expressed with bile from liver of a wolf.

three trapped wolves were collected in 1977 by a resource officer at Pelican Narrows, and were part of a pack that had become a nuisance for local commercial fishermen on Pelican Lake because of their habit of stealing fish left to freeze on the ice. The sixth animal was collected by a resource officer on Deschambault Lake in February 1982. This lake is adjacent and connected to Pelican Lake. The animal was observed to be extremely weak and was unable to run when approached. It was killed and submitted to the laboratory. The seventh wolf was found dead in a trapper's tent at Jan Lake in April 1983. Jan Lake is adjacent, and connected, to Pelican and Deschambault Lakes and the three sites are within 25 km of each other.

The five wolves collected from trappers had no lesions other than in the liver and were in good body condition. In these, the capsular surface of the liver was irregular because of nodules or cordlike swellings within the parenchyma. On section, these swellings were greatly dilated bile ducts surrounded by a thick wall of connective tissue (Fig. 1) and containing a large volume of viscid yellow-green gelatinous fluid and many trematodes (Fig. 2). The gallbladder

and extrahepatic bile ducts were dilated, with thick walls, and contained similar material.

The wolf from Deschambault Lake was an aged male with worn teeth; it was very thin and the intact, unskinned carcass weighed 33 kg. (The average weight of the skinned carcass of 64 male wolves of any age examined in 1976–1978 was 34.3 kg, range 23.2 to 45.2 kg.) The hair coat was sparse over the sides, hips and back, but the underlying skin was normal. The liver was enlarged (weight 2,530 g), very firm and nodular. There was marked dilatation of intra- and extra-hepatic bile ducts with fibrosis, and many trematodes were present in the bile. The cut surface of the liver had a distinct mottled or "nutmeg" appearance, in addition to the obvious changes in the bile ducts. The pancreas was enlarged, white, nodular and very firm. There was one especially large (1.2 × 2.0 cm) firm, pale nodule in the left lobe of the pancreas. The pancreatic duct was enlarged greatly and dilated fibrotic ducts containing trematodes were evident throughout the pancreatic parenchyma. The right ventricle of the heart was dilated and there was thickening and retraction of the leaves of the right atrio-ventricular valves. It appeared that the combination of ventricular dilatation and endocardiosis was

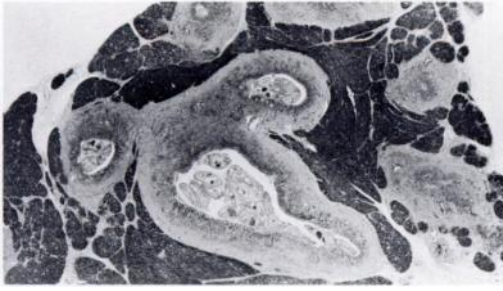


FIGURE 3. Cross section of pancreas from wolf with *Metorchis conjunctus* infection. Numerous trematodes are present in the ducts, and hyperplasia of duct epithelium and fibrosis is evident. H&E. $\times 5$.

so severe that the atrio-ventricular valves on the right would not have been competent. This was the probable cause of the lesions of chronic passive congestion in the liver. The left atrio-ventricular valves were affected less severely. The articular cartilage of the medial condyle of both femurs was roughened and abraded.

Histologically, there was marked proliferation of intra-hepatic bile ducts with deposition of large amounts of connective tissue about the portal areas. In some areas of the liver this fibrosis caused severe distortion of the hepatic architecture by surrounding small islands of hepatocytes. Plasma cells and lymphocytes were common within the connective tissue, particularly surrounding some of the larger bile ducts. There was also evidence of chronic passive congestion with dilatation of hepatic sinusoids, atrophy of hepatocytes, and limited fibrosis in the region of the central veins.

The changes in the pancreatic ducts were similar to those in the liver, with proliferation of both ductular epithelium and connective tissue, and many trematodes present (Fig. 3). There were many plasma cells within the connective tissue. Some lobules of acinar tissue were relatively normal, but most had some degree of interstitial fibrosis with atrophy of acini. In some lobules there was a marked infiltration of plasma cells and lymphocytes, and in others, much of the epithelial component consisted of ductular type cells. The large nodule in the head of the pancreas was a cystically dilated duct with a thick fibrous wall and filled with neutrophils, necrotic debris and trematode ova.

The wolf from Jan Lake was an emaciated adult female that weighed 22 kg. There was an

area of partial hair loss over the shoulder region and numerous biting lice, *Trichodectes canis*, were present on the skin. The liver resembled that described for the other wolves. There were several firm nodules within the pancreatic parenchyma and the distal 4 cm of the left lobe was 2.5 cm in diameter. This portion was composed almost entirely of fibrous tissue and greatly dilated ducts containing many trematodes. The hepatic lymph nodes were enlarged and very firm. The alimentary tract was empty. Microscopic changes in the liver and pancreas of this wolf were similar to those described in the animal from Deschambault Lake. The hepatic lymph nodes had lymphoid and reticular hyperplasia and a few trematode ova were present in the subcapsular area.

DISCUSSION

The lesions in the livers of these wolves were similar to those described in other carnivores infected with *M. conjunctus* (Mills and Hirth, 1968). The changes were dramatic in appearance, but their significance for the health of the wolves is unclear. Many dogs in northern Saskatchewan have similar infections and it is often difficult to demonstrate significant clinical abnormalities in these animals (Wobeser, unpubl. data).

Infection of the pancreas by *M. conjunctus* is apparently uncommon, and only two references to this were found. Mongeau (1961) described a case in a sled dog from Manitoba, and Jubb and Kennedy (1970) showed a photograph of *M. conjunctus* in the pancreatic duct of a cat. Pancreatic involvement occurs with other species of biliary trematodes and Dooley and Neafie (1976) stated that involvement of the pancreatic duct can be found in one-third or more of human cases with biliary fluke infection. There is little published information on the effects of trematode infection of the pancreas in animals. Penner et al. (1954) reported glycosuria in a raccoon (*Procyon lotor*) infected with *Eurytrema procyonis*. Fox et al. (1981) found that infection with *E. procyonis* in domestic cats caused severe impairment of both bicarbonate and protein secretion by the pancreas, but despite this, infected cats appeared healthy. The chronic pancreatitis and fibrosis in these wolves might have caused endocrine and/or exocrine pancreatic insufficiency, but there were no gross lesions to suggest the presence of

either diabetes mellitus or steatorrhea. The sixth wolf had evidence of cardiac insufficiency, as well as arthropathy and dental attrition, and any of these could have been responsible for its weakness and emaciation. No lesions other than those associated with the parasite were found in the seventh wolf to account for its emaciation and death.

Metorchis conjunctus is acquired through consumption of infected fish. It is interesting that three of the seven infected wolves were from a pack with a habit of eating fish. The animals from Pelican, Deschambault and Jan Lakes could conceivably have been from the same local population, because of the proximity of the sites, although collection of these animals occurred over a 6-yr period. Only five wolves have been examined from this area, and all were infected. In contrast, none of 13 and 41 wolves from the Cumberland and Hudson Bay areas, about 75 and 125 km from Pelican Lake, respectively, were infected.

The prevalence of infection reported here (3.3%) is probably minimal, as it is based upon animals with gross lesions in the liver. Holmes and Podesta (1968) reported that there were no gross lesions in the wolf from Alberta.

ACKNOWLEDGMENTS

We thank the resource officers of the departments of Tourism and Renewable Resources, and Northern Saskatchewan, for submission of these specimens; and personnel of the Department of Veterinary Microbiology, Western College of Veterinary Medicine for identification of the trematodes.

LITERATURE CITED

- CAMERON, T. W. M. 1944. The morphology, taxonomy, and life history of *Metorchis conjunctus* (Cobbold, 1860). Can. J. Res. 22D: 6-16.
- , I. W. PARNELL, AND L. L. LYSTER. The helminth parasites of sledge-dogs in northern Canada and Newfoundland. Can. J. Res. 18D: 325-332.
- DOOLEY, J. R., AND R. C. NEAFIE. 1976. Clonorchiasis and opisthorchiasis. In Pathology of Tropical and Extraordinary Disease, Vol. 2, C. H. Binford and D. H. Connor (eds.). Armed Forces Inst. Pathol., Washington, D.C., pp. 509-516.
- FOX, J. N., J. G. MOSLEY, G. A. VOGLER, J. L. AUSTIN, AND H. A. REDER. 1981. Pancreatic function in domestic cats with pancreatic fluke infection. J. Am. Vet. Med. Assoc. 178: 58-60.
- HOLMES, J. C., AND R. PODESTA. 1968. The helminths of wolves and coyotes from the forested regions of Alberta. Can. J. Zool. 46: 1193-1204.
- JORDAN, H. E., AND W. T. ASHBY. 1957. Liver flukes (*Metorchis conjunctus*) in a dog from South Carolina. J. Am. Vet. Med. Assoc. 131: 239-240.
- JUBB, K. V. F., AND P. C. KENNEDY. 1970. Pathology of Domestic Animals, 2nd Ed., Vol. 2. Academic Press, New York, 697 pp.
- MEYER, M. C. 1949. The presence of *Metorchis conjunctus* in Maine. J. Parasitol. 35(sect. 2): 39.
- MILLS, J. H. L., AND R. S. HIRTH. 1968. Lesions caused by the hepatic trematode, *Metorchis conjunctus* Cobbold, 1860. J. Small Anim. Pract. 9: 1-6.
- MONGEAU, N. 1961. Hepatic distomatosis and infectious canine hepatitis in northern Manitoba. Can. Vet. J. 2: 33-38.
- PENNER, L. R., G. F. HELMBOLDT, AND A. L. GRISWOLD. 1954. *Eurytrema procyonis* in a raccoon from Connecticut. Proc. Helminthol. Soc. Wash. 21: 34-35.
- UNRUH, D. H. A., J. E. KING, R. D. P. EATON, AND J. R. ALLEN. 1973. Parasites of dogs from Indian settlements in northwestern Canada: A survey with public health implications. Can. J. Comp. Med. 37: 25-32.