



Non 0-Group 1 *Vibrio cholerae* Infection in a Desert Tortoise (*Gopherus berlanderi*)

Authors: Schmidt, Robert E., and Fletcher, Kenneth C.

Source: Journal of Wildlife Diseases, 19(4) : 358-359

Published By: Wildlife Disease Association

URL: <https://doi.org/10.7589/0090-3558-19.4.358>

BioOne Complete (complete.BioOne.org) is a full-text database of 200 subscribed and open-access titles in the biological, ecological, and environmental sciences published by nonprofit societies, associations, museums, institutions, and presses.

Your use of this PDF, the BioOne Complete website, and all posted and associated content indicates your acceptance of BioOne's Terms of Use, available at www.bioone.org/terms-of-use.

Usage of BioOne Complete content is strictly limited to personal, educational, and non - commercial use. Commercial inquiries or rights and permissions requests should be directed to the individual publisher as copyright holder.

BioOne sees sustainable scholarly publishing as an inherently collaborative enterprise connecting authors, nonprofit publishers, academic institutions, research libraries, and research funders in the common goal of maximizing access to critical research.

tween October 2 and 13, three dead deer and one moribund deer were found at these parks. The three dead animals were too decomposed for evaluation. The moribund adult doe had severe dyspnea and a rectal temperature of 38.2 C. The animal was killed and necropsied at the Kansas City Zoological Garden. Specimens for histopathologic examination and virus isolation were submitted to the Department of Veterinary Pathology, Iowa State University and the U.S. Department of Agriculture, National Veterinary Services Laboratory, Ames, Iowa, respectively.

The gross and microscopic lesions were similar to those described above and typical of those found in hemorrhagic disease. Virus isolation attempts were conducted by inoculation of 1:5 dilution of sonicated red blood cells into cell cultures and embryonating chicken eggs. From inoculated baby hamster kidney cultures, EHD virus (not typed) was recovered. This isolation was confirmed by retesting the original blood specimen. Immunodiffusion tests with serum from the deer were positive for antibodies

against EHD virus and negative to bluetongue virus.

The effect of the 1980 epizootic cannot be completely assessed, although its impact on the state deer herd seems to have been minimal. Three hundred sixteen deer were known to have died of supposed hemorrhagic disease. However, the November firearms season yielded 49,261 deer, a near record harvest, and the bow season added another 3,661 deer to the harvest total. In 1981, the gun harvest was 50,242 deer. Also herd recruitment for the western one third of Missouri during 1979 and 1981 was not significantly different for the percent of pregnant does, the fetus-doe ratio, or calculated fawn production. A similar observation was made by Roughton (1975, *J. Wildl. Dis.* 11: 177-186) for herds of white-tailed deer in Kentucky which experienced a hemorrhagic disease outbreak.

The authors wish to thank the various staff members of the three laboratories which provided diagnostic services for their invaluable technical assistance.

Journal of Wildlife Diseases, 19(4), 1983, pp. 358-359
© Wildlife Disease Association 1983

Non O-Group 1 *Vibrio cholerae* Infection in a Desert Tortoise (*Gopherus berlanderi*)

Robert E. Schmidt, Veterinary Sciences Division, USAF School of Aerospace Medicine, Aerospace Medical Division, AFSC, United States Air Force, Brooks Air Force Base, Texas 78235, USA; and **Kenneth C. Fletcher**, San Antonio Zoological Gardens & Aquarium, 3903 N. St. Mary's, San Antonio, Texas 78212, USA

A female desert tortoise that had been donated to the zoo 3 yr ago was found dead in an outdoor tortoise exhibit. No sign of illness was seen in any other tortoise in the exhibit. The animal was necropsied and tissue specimens were fixed and processed for histologic examination using standard methods.

At necropsy, a few areas of eroded epidermis were noted on the posterior portions of the front legs. Most of the small intestinal mucosa had multifocal necrotic areas. The mucosa and serosa of the large intestine were reddened. Histologically, the intestinal necrosis involved the

entire mucosa, and there was an infiltrate of mononuclear cells (Figs. 1, 2). In sections stained by the McCallum-Goodpasture method, numerous gram negative, curved or comma-shaped rods were noted in the necrotic areas (Fig. 3). Although not noted grossly, histologic examination indicated a multifocal, necrotizing pneumonia. Mononuclear cells and bacteria similar to those noted in the intestine were present in the pulmonary lesions.

Intestinal contents were streaked on MacConkey plates and colonies were inoculated into the Analytical Profile Index (API) system, which resulted in a presumptive diagnosis of *V. cholerae*. Lung cultures were not done, as no gross lesion was seen. The isolates were sent to a re-

Received for publication 21 February 1983.

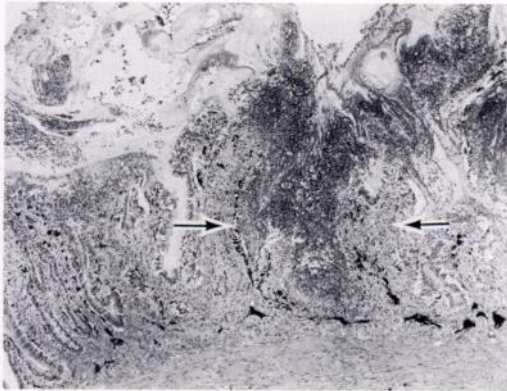


FIGURE 1. Focus of necrosis in small intestine of a desert tortoise (arrows). H&E. $\times 53$.

gional bacteriology laboratory and were identified as a non-O1 *V. cholerae*.

Non-O1 *V. cholerae* have been implicated in human disease, with an increasing prevalence since 1972 (Madden et al., 1981, *Infect. Immun.* 33: 616–619; Kelly et al., 1982, *J. Am. Med. Assoc.* 247: 1598–1599). Many of these cases apparently were associated with eating

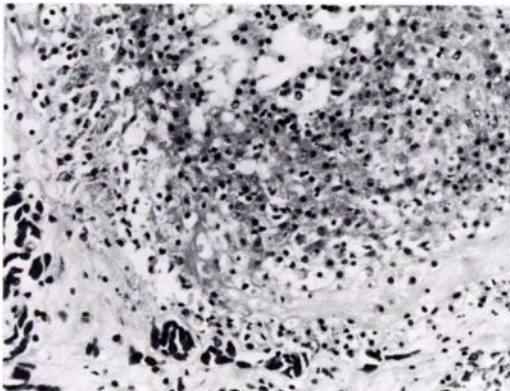


FIGURE 2. Mononuclear phagocyte infiltrate in necrotic focus in small intestine of a desert tortoise. H&E. $\times 360$.

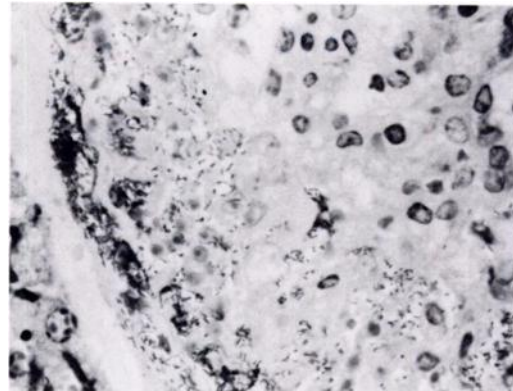


FIGURE 3. Gram negative, curved or comma-shaped bacteria seen in necrotic area in intestine of desert tortoise. MacCallum-Goodpasture. $\times 1,110$.

oysters. Extra-intestinal infection with non-O1 *V. cholerae* has also been reported in man (Floresco et al., 1981, *Arch. Roum. Pathol. Exp. Microbiol.* 40: 369–372). Non-O1 cholera organisms have been isolated from a domestic goose (*Anser anser*) (Schlater et al., 1981, *Avian Dis.* 25: 199–201), and 46 strains of non-O1 *V. cholerae* were isolated from 21 farm animals in another study (Sonyal et al., 1974, *J. Infect. Dis.* 130: 575–579). Dogs also have been reported to carry the organism, with over 14% of 500 dogs positive in one study (Sack, 1973, *J. Infect. Dis.* 127: 709–712). No reports were found of non-O1 *V. cholerae* isolation from reptiles.

The clinical features of non-O1 *V. cholerae* infection in man suggest an invasive rather than toxigenic pathogenesis (Kelly et al., 1982, *op. cit.*) as do the lesions seen in our case. Because of potential for transmission of non-O1 *V. cholerae* to man, and possible subsequent infection, personnel should take proper precautions when handling sick or dead tortoises.

Seven other tortoises of various species were present in the exhibit. All were examined and rectal swabs taken. No enteric pathogens were isolated from any of these tortoises, and all have remained healthy.