



Acid-Fast Intranuclear Inclusion Bodies in the Kidneys of Mallards Fed Lead Shot

Authors: LOCKE, L. N., BAGLEY, G. E., and IRBY, H. D.

Source: Bulletin of the Wildlife Disease Association, 2(4) : 127-131

Published By: Wildlife Disease Association

URL: <https://doi.org/10.7589/0090-3558-2.4.127>

BioOne Complete (complete.BioOne.org) is a full-text database of 200 subscribed and open-access titles in the biological, ecological, and environmental sciences published by nonprofit societies, associations, museums, institutions, and presses.

Your use of this PDF, the BioOne Complete website, and all posted and associated content indicates your acceptance of BioOne's Terms of Use, available at www.bioone.org/terms-of-use.

Usage of BioOne Complete content is strictly limited to personal, educational, and non - commercial use. Commercial inquiries or rights and permissions requests should be directed to the individual publisher as copyright holder.

BioOne sees sustainable scholarly publishing as an inherently collaborative enterprise connecting authors, nonprofit publishers, academic institutions, research libraries, and research funders in the common goal of maximizing access to critical research.

Acid-Fast Intranuclear Inclusion Bodies in the Kidneys of Mallards Fed Lead Shot

L. N. LOCKE, G. E. BAGLEY and H. D. IRBY

Patuxent Wildlife Research Center, Laurel, Maryland

Received for publication 13 June, 1966

ABSTRACT

Acid-fast intranuclear inclusion bodies were found in the cells of the proximal convoluted tubules of the kidneys of mallards fed one, two, three or eight number 6 lead shot and maintained on cracked or whole corn and on grain-duck pellet diets. No acid-fast inclusion bodies were found in mallards fed one or three lead shot but maintained on a duck pellet ration. Dietary factors may be responsible for the failure of mallards fed a duck pellet ration to develop lead inclusion bodies when treated with one or three lead shot. The authors suggest these inclusion bodies can be used as presumptive evidence for lead intoxication in mallards.

INTRODUCTION

In 1936 Blackman, working on human cases of lead poisoning, gave a description of the occurrence of intranuclear inclusion bodies in the livers and kidneys of individuals who had succumbed to lead intoxication. Wachstein (1949) called attention to the acid-fast staining properties of the intranuclear inclusion bodies of the kidney tubules associated with lead intoxication.

This paper reports the occurrence of similar acid-fast intranuclear inclusion bodies in the kidneys of mallards (*Anas platyrhynchos*) fed lead shot.

Although lead poisoning in waterfowl following the ingestion of lead shot has been known in North America since 1894 (Grinnell, 1894) and waterfowl losses attributed to this cause have been reported from many states (Anon., 1965), little work has been done to establish laboratory criteria for

the diagnosis of this condition other than chemical determination of the lead content of various organs. Coburn, *et al.* (1951) reported the occurrence of anemia in ducks fed lead acetate, and Magath in 1931 briefly reported on the histopathological aspects of naturally occurring lead poisoning in ducks in Minnesota following their ingestion of shot. More recently Trainer and his co-workers at the University of Wisconsin have reported on certain aspects of histopathology of lead poisoning in swans (*Olor columbianus*) (Trainer and Hunt, 1965) and in Canada geese (*Branta canadensis*) (Cook and Trainer, 1966). None of these workers reported the presence of the intranuclear inclusion bodies frequently seen in mammals suffering from lead intoxication.

MATERIALS AND METHODS

Number 6 lead shot was obtained from commercially available shot-

gun shells and fed to adult male and female mallards according to the dosage schedule shown in Table 1. Shot were placed directly into the gizzard by using plastic tubing. Ducks were maintained on various diets according to the demands of each experiment, and killed at specified intervals or held until death. Control mallards were maintained on a cracked corn diet and killed after ten days (Table 1). Additional kidney material from mallards, snow geese, and a domestic pigeon dying from causes other than lead poisoning was also examined for the presence of acid-fast intranuclear inclusion bodies and none was found. Tissues were collected for both histopathological study and chemical analysis. Sections for microscopic study were fixed in neutral buffered 10% formalin (4% formaldehyde), embedded in paraffin, sectioned and stained with hematoxylin and eosin or with the Ziehl-Neelson acid-fast technique (Anon., 1957).

RESULTS

The results of the examination of the sectioned kidneys from several mallards that were stained with the Ziehl-Neelson technique are shown in Table 1. Acid-fast intranuclear inclusion bodies were found in the proximal convoluted tubules in both male and female mallards fed one, two, three, or eight lead shot (Fig. 1).

Sections of kidney from a male mallard (L-44) fed two number 6 shot and maintained on a diet of whole corn with sand as a source of grit contained numerous intranuclear inclusions in the cells of the proximal convoluted tubules, and the following description of the inclusion bodies is based on material from this duck. The inclusion bodies were pale yellowish-pink when stained with hematoxylin and eosin and exhibited a metallic sheen. Nuclear membrane of affected cells stained darker with hematoxylin and the nucle-

TABLE 1. Occurrence of Acid-Fast Inclusion Bodies in Mallard Kidney Tissue.

No. Ducks Tested	Sex	No. Lead Shot Given	Died or Killed	Lead in Liver ppm	Acid-Fast Inclusion	Length of Test (Days)	Diet
5	M	8	4K 1D	43 - 55 76	+	10	Cracked corn Cracked corn
5	M	0	K	0.7 - 0.9	0 ¹	10	Cracked corn
4	F	8	2K 2D	20 - 54 39 - 71	+	6 - 8	Cracked corn
4	F	1	K	22 - 27	+	7 - 8	Cracked corn
4	M	3	D	16 ²	+	14 - 16	Mixed grains & pellets
2	F	3	D	*	+	14 - 16	
3 (306,313,316)	M	3	K	3 - 5	0 ¹	60	Duck pellet
2 (326,328)	M	1	K	5 - 7	0 ¹	60	Duck pellet
1 (L-44)	M	2	K	*	+	60	Whole corn

¹Following examination with low (100X), high dri (500X), 100 consecutive fields were examined with oil immersion lens (900X) without finding any inclusion bodies.

²Lead content in the liver was determined for only one of these four ducks.

*Lead analysis not available.

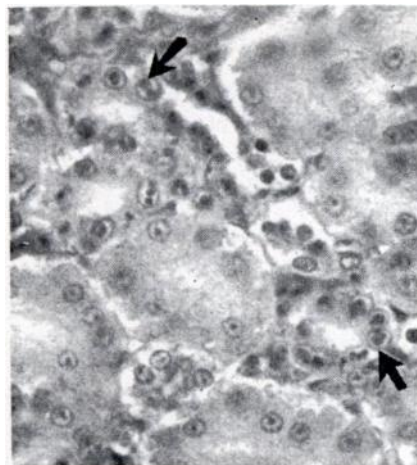


FIGURE 1. Acid-fast intranuclear inclusion bodies (arrows) in renal tubule cells, Mallard L-44. (X125).

olus was frequently seen near the nuclear membrane. Many of the affected cells were enlarged.

When stained with the Ziehl-Neelson technique these intranuclear inclusion bodies were reddish violet to scarlet in color (depending on the freshness of the stain), homogenous, and varied in size and shape, ranging from small discrete spheres 1-3 microns in diameter to irregular bands, 10x6 micron. Two, three, or at times four, inclusion bodies were found in a single nucleus and in some nuclei these appeared to have fused to form large band-like or circular inclusions up to 9-10 microns in diameter or length (Fig. 2). The inclusion body would then occupy almost the entire nucleus, emarginating the chromatin and the nucleolus. Such nuclei were often greatly enlarged, e.g., one measured 19.2x9.6 microns, whereas normal unaffected nuclei were 8x6 microns in size.

In all the mallard drakes and hens fed eight lead shot, but ex-

amined 8-10 days after post treatment, the inclusion bodies were usually smaller than those described above. In ducks dying 14-16 days after being fed three lead shot, the inclusion bodies were similar in size to those seen in L-44. The four mallard hens fed one lead shot remained normal for 7 or 8 days and were then sacrificed. Inclusion bodies in three of these hens were usually extremely small, often 1-3 microns in diameter and frequently very few, and were located only after prolonged examination with the oil immersion lens. In the fourth hen, many small inclusion bodies were present, and they were quite readily found with the oil immersion lens.

DISCUSSION

The number of acid-fast inclusion bodies apparently varies with the dosage of lead, the length of time the birds are exposed to the

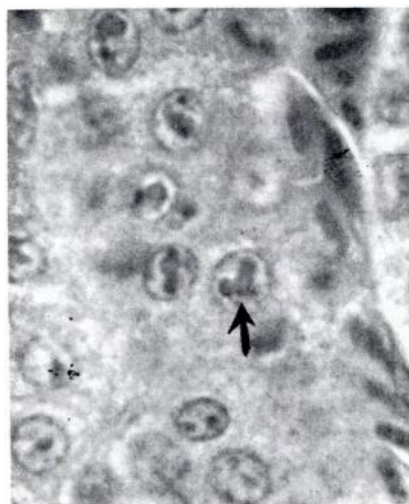


FIGURE 2. Acid-fast intranuclear inclusion body (arrow) in renal tubule cell, Mallard L-44. (X500).

lead shot, and perhaps with certain dietary factors. Mallard L-44, fed whole corn, had 1145 affected nuclei in 100 consecutive oil immersion fields (900X). Many of these inclusion bodies in L-44 were visible with the low power lens (100X), while in the female mallards given one shot and maintained on whole corn for 1 week the inclusions were quite small and frequently were found only after prolonged searching with the oil immersion lens.

Four drakes and two hens fed three lead shot and maintained on a mixed grain and duck pellet diet succumbed to lead poisoning and were found to have typical acid-fast inclusion bodies. However, three drakes fed three lead shot, and two fed one lead shot, but maintained on a duck pellet ration remained healthy and had no acid-fast inclusion bodies at necropsy.

Time since dosage is another factor that determines whether acid-fast inclusion bodies are present in the kidney at the time of necropsy, for the cellular pathology due to lead poisoning may disappear when the animal is returned to a lead-free diet (Haas, et al, 1964). As ducks frequently will expel ingested lead shot, this could explain the lack of acid-fast inclusions in some of our ducks (306-328 in Table 1). Although ducks 306, 313, and 316 were given three lead shot, no shot was recovered at necropsy.

Perhaps dietary factors are the reason that the ducks maintained on a duck pellet ration did not have the acid-fast inclusions. Jordan and Bellrose (1951) have shown that diet is a critical factor

in determining whether a mallard will develop toxic signs of lead poisoning. Certain green feeds such as coontail (*Ceratophyllum demersum*) will prevent the development of signs of lead intoxication in mallards fed levels of lead shot which will kill birds maintained on cracked or whole corn. The commercial duck pellets would be considered as an optimal diet.

Presence of acid fast intranuclear inclusion bodies in the cells lining Henle's loop and the proximal convoluted tubules of the kidney is regarded as being very strong evidence of lead intoxication in man (Blackman, 1936; Haas, et al, 1964; Wachstein, 1949); only bismuth produces similar inclusions, and these have slightly different refractile and staining properties.

Too frequently in the past, diagnosis of lead poisoning in waterfowl were based solely on field evidence without any laboratory support. The authors suggest that, when lead poisoning is suspected among waterfowl, kidney tissue be examined for the presence of acid-fast intranuclear inclusion bodies, and if found, that they should be regarded as strong presumptive evidence of lead exposure. A presumptive diagnosis of lead poisoning can then be made prior to obtaining the definitive results from chemical analysis. Whenever these acid-fast intranuclear inclusion bodies are found in the kidney tissues of waterfowl, the concentration of lead in the liver, brain, and tibia should be determined for confirmative evidence of lead poisoning.

LITERATURE CITED

- ANON. 1957. Manual of Histologic and Special Staining Technics. Armed Forces Institute of Pathology, Washington, D.C. pp. 1-206.
- ANON. 1965. Wasted Waterfowl. Mississippi Flyway Council Planning Committee. pp. 1-72.
- BLACKMAN, S. S., Jr. 1936. Intranuclear inclusion bodies in the kidney and liver caused by lead poisoning. Bull. Johns Hopkins Hospital, 58: 384-403.
- COBURN, D. R., D. W. METZLER and R. TREICHLER. 1951. A study of absorption and retention of lead in wild waterfowl in relation to clinical evidence of lead poisoning. Jour. Wildl. Mgmt., 15(2): 186-192.
- COOK, R. S. and D. O. TRAINER. 1966. Experimental lead poisoning of Canada geese. Jour. Wildl. Mgmt., 30(1): 1-8.
- GRINNELL, G. R. 1894. Lead poisoning. Forest and Stream, 42(6): 117-118.
- HAAS, G. M., D. V. L. BROWN, R. EISENSTEIN and A. HEMMENS. 1964. Relations between lead poisoning in rabbit and man. Amer. Jour. Path., 45(5): 691-727.
- JORDAN, J. S. and F. C. BELLROSE. 1951. Lead poisoning in wild waterfowl. Ill. Nat. Hist. Survey. Biol. Notes, 26: 1-27.
- MAGATH, T. B. 1931. Lead poisoning in wild ducks. Proc. Staff Meetings of the Mayo Clinic, 6: 749-752.
- TRAINER, D. O. and R. A. HUNT. 1965. Lead poisoning of whistling swans in Wisconsin. Avian Dis., 9: 252-264.
- WACHSTEIN, M. 1949. Studies on inclusion bodies. I. Acid-fastness of nuclear inclusion bodies that are induced by ingestion of lead and bismuth. Amer. Jour. Clin. Path., 19: 608-614.

INDEXES TO VOLUMES 1 AND 2 (1965-1966) OF THE BULLETIN¹

SUBJECT	Vol.-Page	
<i>Acanthocephala</i> from birds, 2-78		<i>Cerus canadensis</i> , <i>Pneumostrongylus tenuis</i> from, 2-79
Florida Cyprinodontiform, 1(no.2)-4		elaeophariasis in, 1-48
<i>Agelaius phoeniceus</i> L., endoparasites of, 2-80		chicken, domestic, neoplasma in, 2-67
acid-fast inclusion bodies in duck kidneys, 2-127		cholera, avian, in Trumpeter Swan, 1-54
agglutinins, leptospiral, in herpetofauna sera, 1-55		<i>Clostridium botulinum</i> food poisoning, 1-37
<i>Alces alces</i> , <i>Pneumostrongylus tenuis</i> in, 1 (no.2)-7		<i>Cnephia invenusta</i> , vector of <i>Leucocytozoon</i> in geese, 1 (no.2)-10
anthrax in buffalo, 1 (no.1)-2		<i>Cyathostoma lari</i> , changes of blood in gulls and fowl by, 2-41
antibodies to <i>Myxovirus parainfluenza</i> 3 in deer sera, 1-31		Cyprinodontiform, <i>Acanthocephala</i> of, 1 (no.2)-4
antibody activity of fish serum protein, 2-23		deer, antibodies to <i>Myxovirus parainfluenza</i> 3 in, 1-31
<i>Aquila chrysaetos</i> , <i>Isospora buteonis</i> in, 2-20		microfilaria of <i>Wehrdikmansia cervi</i> in, 1-44
bird hosts, wild, for pox virus, 2-30		Deer, White Tailed, brain abscess in, 1 (no.1)-3
birds, <i>Acanthocephala</i> from, 2-78		helminth infections in, 2-100
blood parasites from, 2-6		mastitis in, 1,35
passerine, blood protozoa of, 2-53		<i>Dictyocaulus</i> sp. in elk, 2-5
wild, cnemidocoptic mite infestations in, 2-86		disease and infections of snakes, 2-111
Blackbirds, Red-winged, endoparasites of, 2-80		parasites of caribou, 1 (no.2)-5
Rusty, <i>Sarcocystis</i> in, 1-36		Doves, White winged, <i>Trichomonas gallinae</i> in, 2-13
brain abscess in a deer, 1 (no.1)-3		Duck, Mallard, acid-fast inclusion bodies in kidneys of, 2-127
buffalo, anthrax in, 1 (no.1)-2		leucocytozoonosis in, 1-33
caribou, diseases and parasites of, 1 (no.2)-5		Eagle, Golden, <i>Isospora buteonis</i> in, 2-20

¹Compiled by F. O. Glaser, National Animal Disease Laboratory, USDA, ARS, Ames, Iowa