

## **Hepatozoon sp. in Wild Carnivores in Texas**

Authors: Mercer, Susan H., Jones, L. P., Rappole, John H., Twedt, Daniel, Laack, Linda L., et al.

Source: Journal of Wildlife Diseases, 24(3) : 574-576

Published By: Wildlife Disease Association

URL: <https://doi.org/10.7589/0090-3558-24.3.574>

---

BioOne Complete ([complete.BioOne.org](https://complete.BioOne.org)) is a full-text database of 200 subscribed and open-access titles in the biological, ecological, and environmental sciences published by nonprofit societies, associations, museums, institutions, and presses.

Your use of this PDF, the BioOne Complete website, and all posted and associated content indicates your acceptance of BioOne's Terms of Use, available at [www.bioone.org/terms-of-use](https://www.bioone.org/terms-of-use).

Usage of BioOne Complete content is strictly limited to personal, educational, and non - commercial use. Commercial inquiries or rights and permissions requests should be directed to the individual publisher as copyright holder.

---

BioOne sees sustainable scholarly publishing as an inherently collaborative enterprise connecting authors, nonprofit publishers, academic institutions, research libraries, and research funders in the common goal of maximizing access to critical research.

## Hepatozoon sp. in Wild Carnivores in Texas

Susan H. Mercer,<sup>1,4</sup> L. P. Jones,<sup>2</sup> John H. Rappole,<sup>3</sup> Daniel Twedt,<sup>3</sup> Linda L. Laack,<sup>3</sup> and T. M. Craig,<sup>1,5</sup>

<sup>1</sup> Department of Veterinary Microbiology and Parasitology, Texas A&M University, College Station, Texas 77843, USA; <sup>2</sup> Texas Veterinary Medical Diagnostic Laboratory, College Station, Texas 77843, USA; <sup>3</sup> Caesar Kleberg Wildlife Research Institute, Texas A&I University, Kingsville, Texas 78363, USA. <sup>4</sup> Present address: College of Veterinary Medicine, The Ohio State University, Columbus, Ohio 43210, USA. <sup>5</sup> Author to whom reprint requests should be addressed

**ABSTRACT:** Twelve coyotes (*Canis latrans*), three bobcats (*Lynx rufus*) and six ocelots (*Felis pardalis*) from the Gulf Coast of Texas were infected with *Hepatozoon* sp. The geographic distribution of infected wild animals coincides with the highest prevalence of *Hepatozoon canis* infection in domestic dogs for which the wild species may act as a reservoir.

**Key words:** *Hepatozoon* sp., coyote, *Canis latrans*, bobcat, *Lynx rufus*, ocelot, *Felis pardalis*, *Dermacentor variabilis*, survey.

The first report of *Hepatozoon* sp. in the United States was in a coyote (*Canis latrans*) found on the Aransas National Wildlife Refuge in Texas by Davis et al. (1978). Subsequently, it has been incriminated as the cause of musculoskeletal disease in domestic dogs (Craig et al., 1978; Barton et al., 1985) and has been reported in bobcats (*Lynx rufus*) from California (Lane and Kocan, 1983). The geographic distribution of *Hepatozoon* sp. in dogs is primarily the Gulf Coast of Texas (Craig, 1984) and the parasite was reported recently in a dog from Louisiana (Gossett et al., 1985). However, the parasite has the potential to be wide spread because its only known vector, the brown dog tick (*Rhipicephalus sanguineus*), is cosmopolitan. This study was undertaken to determine possible reservoirs of infection and the geographic distribution of this parasite in Texas.

Skeletal and/or cardiac muscle samples were taken from 59 coyotes, one bobcat and one red fox (*Vulpes vulpes*) by trappers from the Rodent and Predatory Animal Control Service of Texas (Texas A&M University, College Station, Texas 77843, USA). These animals were trapped in Robertson, Brazoria, Refugio, Wharton and Calhoun counties, Texas (Fig. 1). Tissues were fixed in 10% formalin within 12 hr

of trapping and processed for light microscopy, sections were stained with hematoxylin and eosin (H&E) and examined microscopically for parasites.

Venous blood was taken from 20 bobcats trapped in Aransas, LaSalle, Cameron, Starr and Willacy counties and 13 ocelots trapped in Cameron and Willacy counties, Texas. Both species of cats were individually marked and released. On several occasions the same bobcat or ocelot was resampled. Thin blood films, stained with Diff-Quik (American Scientific Products, McGaw Park, Illinois 60085, USA) or Giemsa stain (Harleco, Gibbstown, New Jersey 08027, USA), were examined for gamonts. Representative specimens of *Hepatozoon* sp. from the three hosts collected in the study were deposited in the U.S. National Parasite Collection (Beltsville, Maryland 20705, USA; Accession Numbers 80043 to 80045).

The use of muscle rather than blood in attempting to demonstrate the organism in coyotes was chosen because our observations in domestic dogs indicate that muscle biopsy is generally superior to blood in finding the organism (Craig et al., 1984). It was not practical to perform field surgery on the felids but it was possible to obtain blood samples from them. The parasitaemias were low in the felids as in domestic dogs with <0.1% of the neutrophils infected.

Although few counties were surveyed, positive animals were only identified in the coastal region of Texas (Fig. 1). In this study 12 coyotes, three bobcats and six ocelots were infected with *Hepatozoon* sp. With the exception of a single female coyote that was nursing a litter, the coyotes were judged to be "in good physical con-

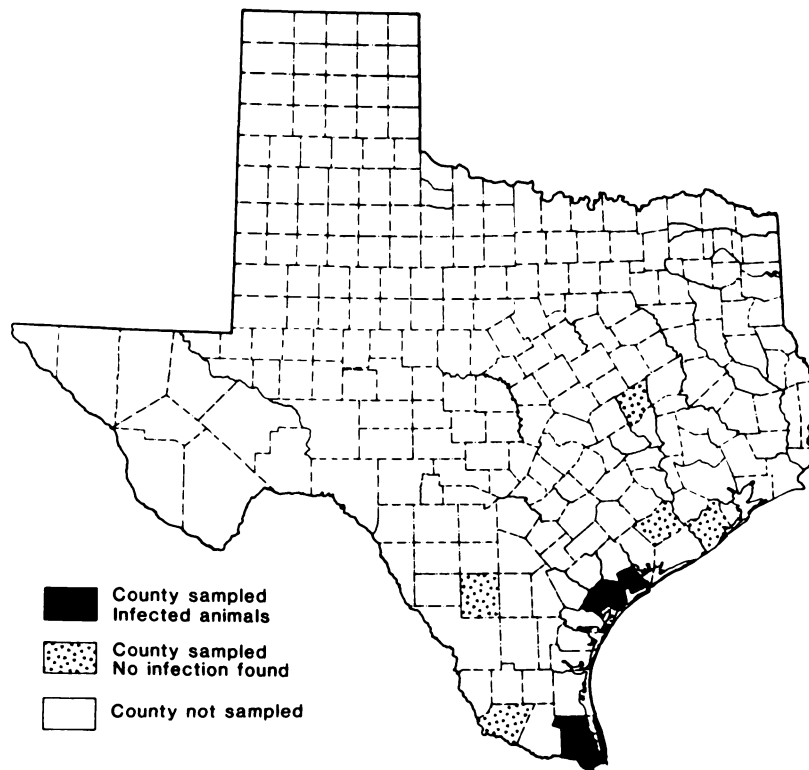


FIGURE 1. Geographic distribution of *Hepatozoon* sp. in wild carnivores from Texas, USA.

dition" by the trappers. The emaciated coyote was negative for *Hepatozoon* sp. as were her pups. All bobcats and ocelots were in good physical condition at the time of capture. Although it was not possible to examine ectoparasites from many of the animals collected, a representative sample of ticks and fleas were collected from 10 bobcats and six ocelots. All of the bobcats and ocelots were infested with fleas (*Pulex* sp.) at the time of collection. All cats were infested with the American dog tick (*Dermacentor variabilis*) with from one to 61 adult ticks collected from each individual. *Amblyomma inornatum*, *A. maculatum* and *A. cajennense* were collected also from both bobcats and ocelots. Representative samples of fleas and ticks collected from both bobcats and ocelots were deposited in the U.S. National Parasite Collection (Beltsville, Maryland 20705, USA; Accession Numbers 80037 to 80042 and 80136 to 80137). None of the ticks were examined for *Hepatozoon* sp. oocysts. Cy-

*tauxzoon* sp. was identified in the erythrocytes of one bobcat and three ocelots.

Although only 10 counties were surveyed, 12 coyotes, three bobcats and six ocelots were infected with *Hepatozoon* sp. Coyotes and bobcats have already been identified as infected with the parasite in the United States (Davis et al., 1978; Lane and Kocan, 1983); however, this is the first report of *Hepatozoon* sp. in ocelots. Several carnivores including the domestic cat (Ewing, 1977), red fox (*Vulpes vulpes*) (Maede et al., 1982), genet (*Genetta* sp.), lion (*Panthera leo*), leopard (*Panthera pardus*), cheetah (*Acinomyx jubatus*), jackal (*Canis aureus*), hyaenas (*Crocuta crocuta*) (McCully et al., 1975) and various mustelids (Presidente and Karstad, 1975; Von Geisel et al., 1979; Novilla et al, 1980) are hosts of *Hepatozoon* sp. The host specificity of the genus is unknown. If transmission is limited to the single vector (*Rhipicephalus sanguineus*), it seems unlikely that the *Hepatozoon* sp. of carni-

vores is shared among hosts because of the host specificity of *R. sanguineus* in North America (Strickland et al., 1976). However, if other vectors or carnivorism (Landau et al., 1972; Nordgren and Craig, 1984) are involved there may be a single species and transmission may be accomplished by *D. variabilis* or *Pulex* sp., common ectoparasite species in this region.

The geographic distribution of *Hepatozoon* sp. on the Gulf Coast of Texas, coincides with the highest prevalence of the parasite in domestic dogs (Craig, 1984). Therefore, wild carnivores may serve as reservoir hosts for the parasite. The fact that none of the infected wild carnivores had clinical signs suggestive of hepatozoonosis does not mean they did not have the disease. Further surveys and cross infection studies are necessary to determine the extent of the infection in wild and domestic carnivores in North America, and the host range of *Hepatozoon* sp. in both mammals and ticks or other arthropods.

The authors thank Robert Beach of the Texas Rodent and Predatory Control Service of Texas for coordinating the collection of samples from the coyotes; Pete Teel and Darrel Bay, Department of Entomology, Texas A&M University for identification of arthropods and Jack Bordon of the Texas Veterinary Medical Diagnostic Laboratory for technical support.

#### LITERATURE CITED

- BARTON, C. L., E. A. RUSSO, T. M. CRAIG, AND R. W. GREENE. 1985. Canine hepatozoonosis: A retrospective study of 15 naturally occurring cases. *Journal of the American Animal Hospital Association* 21: 125-134.
- CRAIG, T. M. 1984. Hepatozoonosis. In *Clinical microbiology and infectious diseases of the dog and cat*, C. E. Green (ed.), W. B. Saunders, Philadelphia, Pennsylvania, pp. 771-779.
- CRAIG, T. M., L. P. JONES, AND R. M. NORDGREN. 1984. Diagnosis of *Hepatozoon canis* by muscle biopsy. *Journal of the American Animal Hospital Association* 20: 301-303.
- CRAIG, T. M., J. E. SMALLWOOD, K. E. KNAUER, AND J. P. McGRATH. 1978. *Hepatozoon canis* infection in dogs: Clinical, radiographic and hematologic findings. *Journal of the American Veterinary Medical Association* 173: 967-972.
- DAVIS, D. S., R. M. ROBINSON, AND T. M. CRAIG. 1978. Naturally occurring hepatozoonosis in a coyote. *Journal of Wildlife Diseases* 14: 244-246.
- EWING, G. O. 1977. Granulomatous cholangiohepatitis in a cat due to a protozoan parasite resembling *Hepatozoon canis*. *Feline Practice* 7: 37-40.
- GOSSETT, K. A., S. D. GAUNT, AND D. S. AJA. 1985. Hepatozoonosis and ehrlichiosis in a dog. *Journal of the American Animal Hospital Association* 21: 265-267.
- LANDAU, I., J. C. MICHAEL, AND A. G. CHABAUD. 1972. Cycle biologique d'*Hepatozoon domerqueti*; discussion sur les caracteres fondamentaux d'un cycle de coccidie. *Zeitschrift für Parasitenkunde* 38: 250-270.
- LANE, J. R., AND A. A. KOCAN. 1983. *Hepatozoon* sp infection in bobcats. *Journal of the American Veterinary Medical Association* 183: 1323-1324.
- MAEDE, Y., T. OHSUGI, AND N. OHOTAISHI. 1982. *Hepatozoon* infection in a wild fox (*Vulpes vulpes schrencki* Kishida) in Japan. *Japanese Journal of Veterinary Science* 44: 137-142.
- MCCULLY, R. M., P. A. BASSON, R. G. BIGALKE, V. DEVOS, AND E. YOUNG. 1975. Observations on naturally acquired hepatozoonosis of wild carnivores and dogs in the Republic of South Africa. *Onderstepoort Journal of Veterinary Research* 42: 117-134.
- NORDGREN, R. M., AND T. M. CRAIG. 1984. Experimental transmission of the Texas strain of *Hepatozoon canis*. *Veterinary Parasitology* 16: 207-214.
- NOVILLA, M. N., J. W. CARPENTER, AND R. P. KWAPIEN. 1980. Double infection of Siberian polecats (*Mustela eversmanni satunini*) with *Encephalitozoon cuniculi* and *Hepatozoon mustelis* n. sp. In *The comparative pathology of zoo animals*, R. J. Montali and G. Migaki (eds.), Smithsonian Press, Washington, D.C., pp. 353-363.
- PRESIDENTE, P. J. A., AND L. H. KARSTAD. 1975. *Hepatozoon* sp. infection in mink from Southwestern Ontario. *Journal of Wildlife Diseases* 11: 479-481.
- STRICKLAND, R. K., R. R. GERRISH, J. L. HOURRIGAN, AND G. O. SCHUBERT. 1976. Ticks of Veterinary Importance. United States Department of Agriculture, Animal and Plant Health Inspection Service, Beltsville, Maryland, Agriculture Handbook No. 485, 122 pp.
- VON GEISEL, O., H. E. KRAMPITZ, AND A. POSTSCHILL. 1979. Zur Pathomorphologie einer *Hepatozoon*-infektion bei Musteliden. *Berliner und Münchener Tierärztliche Wochenschrift* 92: 421-425.

Received for publication 4 September 1987.