

AN ADENOVIRUS INFECTION OF THE KIDNEY OF FRANKLIN'S GROUND SQUIRRELS (SPERMOPHILUS FRANKLINI) IN SASKATCHEWAN, CANADA

Authors: Durham, P. J. K., LEIGHTON, F. A., and Wobeser, G. A.

Source: Journal of Wildlife Diseases, 24(4) : 636-641

Published By: Wildlife Disease Association

URL: <https://doi.org/10.7589/0090-3558-24.4.636>

The BioOne Digital Library (<https://bioone.org/>) provides worldwide distribution for more than 580 journals and eBooks from BioOne's community of over 150 nonprofit societies, research institutions, and university presses in the biological, ecological, and environmental sciences. The BioOne Digital Library encompasses the flagship aggregation BioOne Complete (<https://bioone.org/subscribe>), the BioOne Complete Archive (<https://bioone.org/archive>), and the BioOne eBooks program offerings ESA eBook Collection (<https://bioone.org/esa-ebooks>) and CSIRO Publishing BioSelect Collection (<https://bioone.org/csiro-ebooks>).

Your use of this PDF, the BioOne Digital Library, and all posted and associated content indicates your acceptance of BioOne's Terms of Use, available at www.bioone.org/terms-of-use.

Usage of BioOne Digital Library content is strictly limited to personal, educational, and non-commercial use. Commercial inquiries or rights and permissions requests should be directed to the individual publisher as copyright holder.

BioOne is an innovative nonprofit that sees sustainable scholarly publishing as an inherently collaborative enterprise connecting authors, nonprofit publishers, academic institutions, research libraries, and research funders in the common goal of maximizing access to critical research.

AN ADENOVIRUS INFECTION OF THE KIDNEY OF FRANKLIN'S GROUND SQUIRRELS (*SPERMOPHILUS FRANKLINI*) IN SASKATCHEWAN, CANADA

P. J. K. Durham,¹ F. A. Leighton,² and G. A. Wobeser²

¹ Department of Veterinary Microbiology, Western College of Veterinary Medicine, University of Saskatchewan, Saskatoon, Saskatchewan, Canada S7N 0W0

² Department of Veterinary Pathology, Western College of Veterinary Medicine, University of Saskatchewan, Saskatoon, Saskatchewan, Canada S7N 0W0

ABSTRACT: During routine pathological studies of Franklin's ground squirrels (*Spermophilus franklini*) collected during a predator control program, basophilic intranuclear inclusions were found in the collecting tubule epithelium of the renal papillae in seven of 13 squirrels. This was associated with marked karyomegaly in affected cells. An inflammatory response was not seen in the adjacent tissues. Electron microscopic examination of affected cells demonstrated that the enlarged nuclei contained numerous virus-like particles. Autoculture and serial passage of renal medullary cells resulted in the isolation of virus particles producing intranuclear inclusions and cytopathic effect. The virus possessed properties typical of adenoviruses, but showed no evidence of hemagglutinating activity with a range of species of erythrocytes tested under several temperature conditions. The isolates were relatively host-cell specific; they failed to grow in hamster and rabbit kidney cell lines and in ground squirrel kidney cortical cells.

Key words: Adenovirus, Franklin's ground squirrel, *Spermophilus franklini*, subclinical infection, kidney, pathology.

INTRODUCTION

The Franklin's ground squirrel (*Spermophilus franklini*) is an inhabitant of the tall grass prairie and parklands of the great plains of North America. It has gained some notoriety among waterfowl managers because of its omnivorous diet which includes eggs and young birds (Banfield, 1974). Disease in this species has not been studied extensively; a high prevalence of adiaspiromycosis has been reported (Tobon et al., 1976; Leighton and Wobeser, 1978). In this paper we report infection of the kidneys of Franklin's ground squirrels with an adenovirus.

MATERIALS AND METHODS

Franklin's ground squirrels were collected from May to August 1986 and 1987 in the vicinity of St. Denis, approximately 40 km east of Saskatoon, Saskatchewan, Canada (52°00'N, 106°30'W). An additional two squirrels were collected along the South Saskatchewan River on the outskirts of Saskatoon. The squirrels were caught in wire mesh live traps by personnel of the Canadian Wildlife Service (Saskatoon, Saskatchewan, Canada S7N 0X4) as part of a study of predator reduction on duck reproductive success. After capture, the squirrels were trans-

ported to the Western College of Veterinary Medicine (Saskatoon, Saskatchewan, Canada S7N 0W0), where they were killed with halothane (M.T.C. Pharmaceuticals, Mississauga, Ontario, Canada M4W 2S5) and examined post-mortem. A selection of tissues, including kidneys, was fixed in neutral buffered formalin and embedded in paraffin. Sections 5 µm thick were stained with hematoxylin and eosin (H&E). Blocks of one formalin-fixed renal medulla were post-fixed in osmium tetroxide and embedded in Jembed 812 (J.B.EM Services Inc., Dorval, Quebec, Canada H9R 4S8). Ultrathin sections were cut, stained with uranyl acetate and lead citrate, and viewed in a Philips 410LS electron microscope (Philips Electronics, Eindhoven, The Netherlands).

Following initial observation of virus inclusion body-like structures in renal medullary cells, a small segment of each newly received renal medulla was fixed in formalin and processed for histological study. The remainder was used for virological studies.

Virus isolation and culture

Autocultures were prepared by mincing the kidney cortex and medulla with scalpels, washing with sterile phosphate-buffered saline (PBS) and then digesting with sterile 0.5% trypsin saline at 37 C for 20 min. Several harvests were pooled from each tissue, washed with PBS three times and resuspended at 1% concentration in

growth medium consisting of Dulbecco's minimal essential medium (Flow Laboratories Inc., McLean, Virginia 22102, USA), with 100 IU of penicillin and 100 μ g of streptomycin (Sigma Chemical Co., St Louis, Missouri 63178, USA) per ml, and 10% heat-inactivated fetal calf serum (FCS) (BDH Chemicals Canada Ltd., Saskatoon, Saskatchewan, Canada S7L 5Z9). They were then dispensed into several plastic tissue culture flasks and incubated at 37 C.

Following establishment of the cultures, cells were detached using a trypsin-versene mixture (0.05% trypsin and 0.02% versene in PBS) and subcultured into further flasks and culture slides (Lab-Tek Flaskettes; Miles Laboratories, Naperville, Illinois 60566, USA). Confluent cultures were maintained in medium as above but with only 2% FCS.

Slide cultures were examined for virus inclusions after each passage, following washing with PBS, fixation with acetone and staining with H&E. Samples of each passage also were stored at -90 C, following suspension in growth medium containing 10% dimethyl sulfoxide.

Fifth passage kidney medulla cells were frozen and thawed three times, clarified by centrifugation at 1,000 *g* for 10 min, and the supernatant inoculated into near-confluent cultures of secondary ground squirrel kidney cortex cells and into two continuous cell lines of rabbit and hamster kidney origin (RK₁₃ and BHK₂₁; American Type Culture Collection, Rockville, Maryland 20852, USA), all in maintenance medium. Inoculated cells were subcultured once after 7 days incubation; slide cultures from both passages were examined for inclusions after 7 days. The final passage was checked for virus content by electron microscopic examination as below, together with the initial inoculum.

To determine the nucleic acid type of the virus, fourth passage medullary cell cultures were grown in the presence and absence of 100 μ g per ml of bromodeoxyuridine (BUDR) (Sigma Chemical Co., St. Louis, Missouri 63178, USA) using bovine embryonic tracheal cells infected with a local strain of bovine herpesvirus 1 as a control.

Electron microscopy

Fourth and fifth passage cultures of medullae were lysed by repeated freezing and thawing, and clarified by centrifugation at 1,000 *g* for 10 min. They were then ultracentrifuged at 122,000 *g* for 10 min in an airfuge (Beckman Instruments, Palo Alto, California 94304, USA). The resultant pellets were resuspended in small volumes of saline, stained with 2% sodium phosphotungstate (pH 6.8) (BDH Chemicals Canada Ltd., Saskatoon, Saskatchewan, Canada S7L 5Z9)

on carbon and formvar coated grids and examined.

Hemagglutination testing

Clarified supernatants from fifth passage medullary cultures were tested for hemagglutinating activity by a microtiter procedure (Hierholzer et al., 1969) using PBS with 0.5% bovine serum albumin (BDH Chemicals Canada Ltd., Saskatoon, Saskatchewan, Canada S7L 5Z9) as diluent, and 0.5% triple washed erythrocytes. The test was carried out at 37 C, 25 C and 4 C, using locally obtained cow, rabbit, sheep, pig, horse, goat, fowl, dog, guinea pig, hamster, rat and human type O erythrocytes.

Buoyant density

Fifth passage cultures were frozen and thawed three times, clarified by centrifugation at 1,000 *g* for 10 min, and then centrifuged at 90,000 *g* for 2 hr in an ultracentrifuge (Beckman Instruments, Palo Alto, California 94304, USA). The resultant pellet was resuspended in a small volume of saline, and checked for virus content by electron microscopy. The viral concentrate was then overlaid on a preformed 20% to 45% continuous cesium chloride gradient (Rowlands et al., 1971) and centrifuged at 90,000 *g* for 15 hr. Fractions were collected by puncturing the bottom of the tube, and their densities determined from their refractive indices, using an Abbe type refractometer. Virus content was determined by electron microscopy.

RESULTS

Pathology

No important lesions were evident upon gross inspection or histological examination, except in the kidneys. In these organs, a few to many cells of collecting duct epithelium of the renal papilla were greatly enlarged due to karyomegally (Fig. 1). Enlarged nuclei contained large basophilic inclusions which sometimes occupied the entire nucleus. Affected cells protruded into the tubule lumen. In many instances, the cells were detached from their basement membrane and were attached instead to the luminal surface of epithelial cells that had apparently filled the space left by previous detachment of the inclusion-bearing cells (Figs. 2, 3). There was no inflammation associated with these lesions. In electron micrographs of medullary tissue, the enlarged nuclei contained

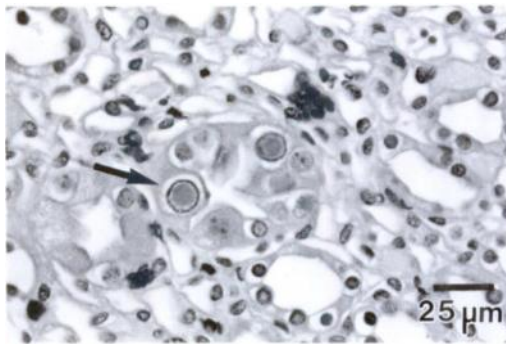


FIGURE 1. Collecting duct of ground squirrel renal papilla infected with adenovirus. Enlarged nuclei with dense intranuclear inclusions (arrow) are evident in epithelial cells. H&E.

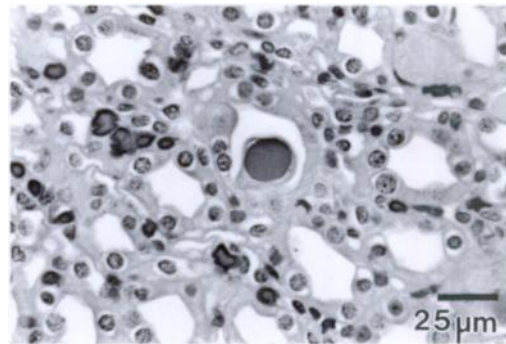


FIGURE 2. Collecting duct of ground squirrel renal papilla infected with adenovirus. A single large cell with a very large intranuclear inclusion is present in the lumen of the duct, apparently attached to the intact epithelium. H&E.

numerous virus particles with an approximate mean diameter of 60 nm. Virus particles had cubic symmetry and no envelope, and were seen only in the nucleus (Fig. 3).

Prevalence

Both kidneys of 13 squirrels were assessed histologically. Virus inclusion bodies were seen in at least one kidney of seven (54%) animals: six from St. Denis, one from Saskatoon.

Virology

Cortical cell cultures were readily established from kidneys from four separate animals and were passed through five subcultures with no evidence of cytopathic effect. Intranuclear inclusions were not detected in H&E stained cultured cells at any passage level.

Medullary cell cultures were attempted from two animals and were established successfully on both occasions, though they took somewhat longer to establish than cortical cells. They retained an epithelial character. Very occasional basophilic intranuclear inclusions were detected in stained second passage cells. These increased in numbers with passage level. At the fourth passage, some degeneration of the monolayer was seen, with rounding up and detachment of scattered cells. On the

fifth passage, the monolayer failed to reach confluence and gradually deteriorated in a diffuse fashion. Inclusions were seen in about 5% of the stained monolayer cells at this stage, and were present in a multifocal distribution. Because many cells appeared to have detached prior to and during staining, the true proportion of affected cells was probably much higher.

Affected cells generally had little cytoplasmic change, apart from increased cytoplasmic eosinophilia and minor vacuolation. The nuclei had marginated chromatin and contained large single round to ovoid basophilic inclusions (Fig. 4). Some inclusions had a highly irregular shape. Most affected nuclei were of normal size, though some were enlarged up to three diameters and were occupied almost entirely by the inclusion. The inclusions appeared to become more basophilic as they matured and the marginated chromatin became progressively more dense and fragmented.

Inoculation of frozen and thawed clarified fifth passage medullary cultures into secondary ground squirrel kidney cortex cultures, and into RK₁₃ and BHK₂₁ cell lines failed to produce cytopathic effect or inclusions after two passages. Virus was not detected by electron microscopic examination of negatively stained ultracentrifuged second passage cell sediments from

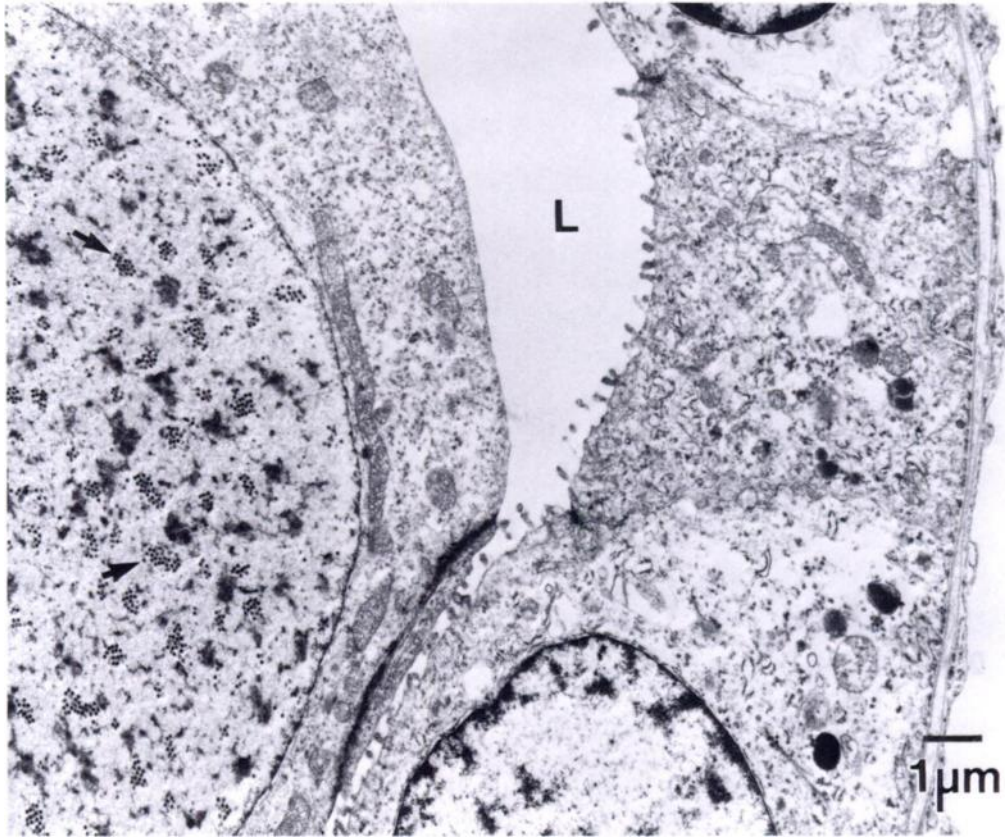


FIGURE 3. Electron micrograph of a ground squirrel collecting duct and enlarged cell similar to that in Figure 2. The large cell in the duct lumen (L) contains numerous clusters of virus particles (arrows) in its nucleus.

these cultures, although virus was readily demonstrated in the original inoculum.

Electron microscopic examination of negatively stained ultracentrifuged medullary cell sediments revealed numerous icosahedral virus particles with a mean diameter of 75 nm. The viruses were unenveloped, and a minority appeared to be empty defective particles. Many of the viruses had pronounced triangular facettation, with six capsomeres visible per side (Fig. 5).

Although the viruses were tested against erythrocytes from a wide range of species at three different temperatures, no evidence of hemagglutinating activity could be detected. Addition of BUDR to fourth passage medullary cell cultures caused marked suppression of inclusion body for-

mation, indicating that virus replication involved DNA synthesis.

The complete virus particles were found to have a density of 1.34 g/ml by isopycnic density gradient centrifugation in cesium chloride. Empty particles had a density of 1.30 g/ml.

DISCUSSION

The isolated viruses were identified as typical adenoviruses; their morphology, size, density, sensitivity to BUDR and cultural characteristics were in close agreement with published reports of adenoviruses in other species (Philipson et al., 1975; Andrewes et al., 1978; Ishibashi and Yasue, 1984). It was not possible to conduct a lipid solvent sensitivity test in the present studies due to the lack of a suitable uninfected

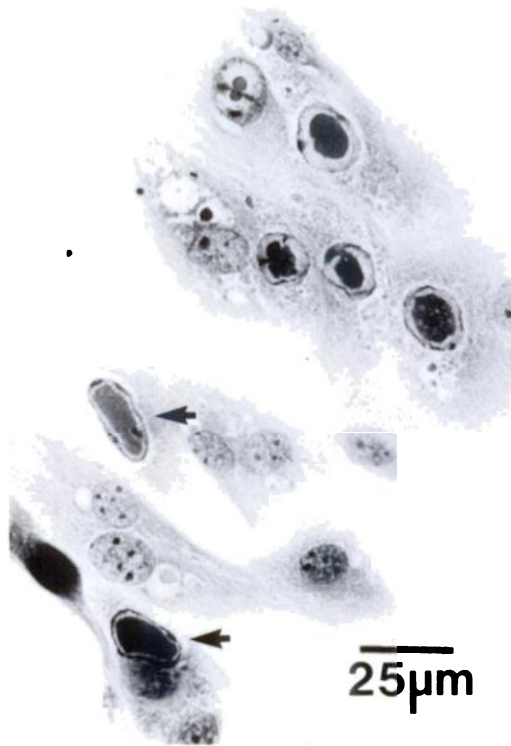


FIGURE 4. Fourth passage cells from ground squirrel kidney medulla showing numerous basophilic intranuclear inclusions (arrows). H&E.

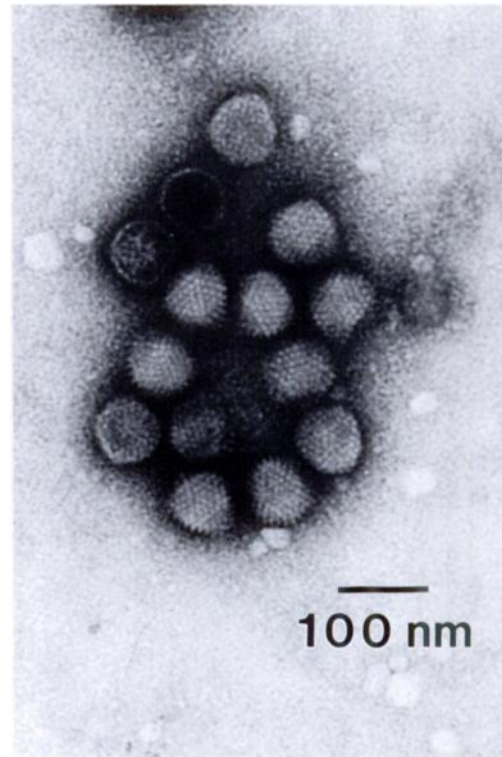


FIGURE 5. Electron micrograph of adenovirus isolated from a ground squirrel, showing complete and empty particles, and the pronounced triangular facies.

cell culture system, but repeated electron microscopic studies clearly indicated that the virus was unenveloped. Although the diameter of the virus particles seen in the sectioned kidney tissues was somewhat smaller than that of negatively stained virus, the difference was considered to be a consequence of tissue processing; both sizes measured were consistent with those reported with other adenoviruses (Andrewes et al., 1978; McFerran, 1981).

Many mammalian adenoviruses are known to have hemagglutinating activity with erythrocytes from various animal species (Philipson et al., 1975; Andrewes et al., 1978). However, this was not detected with the two isolates in the present study, despite reasonably high virus titers, as determined by electron microscopy. This was rather surprising, considering the extensive range of species of erythrocyte

tested and the three temperature conditions. Nevertheless, such lack of detectable hemagglutinating activity has been recognized with other adenoviruses, such as some of those found in the chimpanzee, pig and mouse (Andrewes et al., 1978).

There appear to be no previous reports of adenovirus infection in ground squirrels. Cytomegalic inclusion disease has been reported in the salivary glands of ground squirrels (*Citellus citellus*) in Rumania (Diosi et al., 1967), but this was attributed to a herpesvirus infection. Adenovirus was demonstrated only in the kidney medulla in the present study, but it may have been present in some other organs; the intestinal tract and tonsillar tissues were not examined histologically. Adenovirus infections have been demonstrated in the tonsils, lung, liver and intestinal tract of a variety of

species of diseased animals, and isolations also have been made from organs (including kidneys) of apparently healthy animals including cattle, pigs, sheep, horses, dogs, mice, monkeys and birds (McFerran, 1981; Ishibashi and Yasue, 1984). It is clear that subclinical infections are relatively common in some species of animals, especially in epithelial cells.

Adenoviruses frequently have been reported to exhibit a narrow host range, both within the animal host and in cell culture (Ishibashi and Yasue, 1984). Therefore, the lack of growth of the isolates in ground squirrel kidney cortical cells and in the two cell lines is not surprising.

The persistence of adenovirus infection is indicative of a failure of immune clearance mechanisms (Straus, 1984), as is the lack of inflammatory response. The reason for this failure is not clear, although it is accepted that viral growth and pathogenic effect in animals can be modified by such factors as age and immune status at challenge and the genetic background of the host animal (Ishibashi and Yasue, 1984). Adenovirus infections are also known to be reactivated during immunodeficiency syndromes (Straus, 1984).

Although the number of ground squirrels sampled was fairly small, the prevalence of subclinical adenovirus infection appeared to be high. Whether this is typical of the host species throughout its range, or only represents a local phenomenon is unknown. Transmission of adenovirus in other species is usually horizontal, and it is considered that high population densities predispose to high rates of infection (Ishibashi and Yasue, 1984). When excreted in urine or feces, adenoviruses do not seem to lose infectivity immediately, hence food and drinking water can easily become contaminated (Ishibashi and Yasue, 1984), further aiding spread of the virus. The significance of this adenovirus to the health of its host species or to other sympatric species remains to be determined.

ACKNOWLEDGMENTS

We thank L. Hassard, L. Stevenson and I. Shirley for their technical assistance with part of this work. We also thank R. Clark, Canadian Wildlife Service, for collecting many of the ground squirrels.

LITERATURE CITED

- ANDREWS, C., H. G. PEREIRA, AND P. WILDY. 1978. Viruses of vertebrates, 4th ed. Bailliere Tindall, London, England, 420 pp.
- BANFIELD, A. W. F. 1974. The mammals of Canada. University of Toronto Press, Toronto, Ontario, Canada, 438 pp.
- DIOSI, P., M. RADU, AND G. BRAN. 1967. Cyto-megalic inclusions in animals in south-west Rumania. *Journal of Comparative Pathology* 77: 41-44.
- HIERHOLZER, J. C., M. T. SUGGS, AND E. C. HALL. 1969. Standardized viral hemagglutination and hemagglutination-inhibition tests. *Applied Microbiology* 18: 824-833.
- ISHIBASHI, M., AND H. YASUE. 1984. Adenoviruses of animals. In *The adenoviruses*, H. Ginsberg (ed.). Plenum Press, New York, New York, pp. 497-562.
- LEIGHTON, F. A., AND G. A. WOBESER. 1978. The prevalence of adiaspiromycosis in three sympatric species of ground squirrels. *Journal of Wildlife Diseases* 14: 362-365.
- McFERRAN, J. B. 1981. Adenoviruses of vertebrate animals. In *Comparative diagnosis of viral diseases*, Vol. III, part A., E. Kurstak and C. Kurstak (eds.). Academic Press, New York, New York, pp. 102-165.
- PHILIPSON, L., U. PETERSSON, AND U. LINDBERG. 1975. Molecular biology of adenoviruses. In *Virology monographs*, Vol. 14, S. Gard, C. Hallaver, and K. F. Meyer (eds.). New York, New York, pp. 1-89.
- ROWLANDS, D. J., D. V. SANGAR, AND F. BROWN. 1971. Buoyant density of picornaviruses in caesium salts. *Journal of General Virology* 13: 141-152.
- STRAUS, S. E. 1984. Adenovirus infection in humans. In *The adenoviruses*, H. Ginsberg (ed.). Plenum Press, New York, New York, pp. 464.
- TOBON, J. L., T. M. YUILL, AND W. M. SAMUEL. 1976. Adiaspiromycosis in the Franklin's ground squirrel (*Spermophilus franklini*) and Pica (*Ochotona princeps*) from Alberta, Canada. *Journal of Wildlife Diseases* 12: 97-100.

Received for publication 21 March 1988.