

A VISCERAL MYCOSIS IN CULTURED MASU SALMON (ONCORHYNCHUS MASOU) CAUSED BY A SPECIES OF OCHROCONIS

Authors: Hatai, K., and Kubota, S. S.

Source: Journal of Wildlife Diseases, 25(1) : 83-88

Published By: Wildlife Disease Association

URL: <https://doi.org/10.7589/0090-3558-25.1.83>

The BioOne Digital Library (<https://bioone.org/>) provides worldwide distribution for more than 580 journals and eBooks from BioOne's community of over 150 nonprofit societies, research institutions, and university presses in the biological, ecological, and environmental sciences. The BioOne Digital Library encompasses the flagship aggregation BioOne Complete (<https://bioone.org/subscribe>), the BioOne Complete Archive (<https://bioone.org/archive>), and the BioOne eBooks program offerings ESA eBook Collection (<https://bioone.org/esa-ebooks>) and CSIRO Publishing BioSelect Collection (<https://bioone.org/csiro-ebooks>).

Your use of this PDF, the BioOne Digital Library, and all posted and associated content indicates your acceptance of BioOne's Terms of Use, available at www.bioone.org/terms-of-use.

Usage of BioOne Digital Library content is strictly limited to personal, educational, and non-commercial use. Commercial inquiries or rights and permissions requests should be directed to the individual publisher as copyright holder.

BioOne is an innovative nonprofit that sees sustainable scholarly publishing as an inherently collaborative enterprise connecting authors, nonprofit publishers, academic institutions, research libraries, and research funders in the common goal of maximizing access to critical research.

A VISCERAL MYCOSIS IN CULTURED MASU SALMON (*ONCORHYNCHUS MASOU*) CAUSED BY A SPECIES OF *OCHROCONIS*

K. Hatai and S. S. Kubota

Department of Fish Diseases, Nippon Veterinary and Zootechnical College, 1-7-1 Kyonan Cho,
Musashino, Tokyo 180, Japan

ABSTRACT: *Ochroconis* sp. infection was found in masu salmon (*Oncorhynchus masou*) with visceral mycosis in Japan. The external and internal clinical signs were reddening of the anal area, swelling of the abdomen due to accumulation of ascitic fluid in the abdominal cavity and extensive swelling of the posterior kidney. Many pale brown, septate hyphae were found in the kidney by direct microscopical examination; these were usually not found in the other organs of infected fish. Histopathological examination of the kidney revealed large granulomas with the fungal hyphae and giant cells. The isolated fungus was identified as a species of the genus *Ochroconis* and was compared with *O. tshawytschae*, a known fish pathogen. Based on morphological and growth characteristics, we believe that these cases resulted from infection with a different species.

Key words: Visceral mycosis, masu salmon, *Oncorhynchus masou*, *Ochroconis* sp., granuloma, case report.

INTRODUCTION

A visceral mycosis in fish due to the genus *Ochroconis* was first reported from kidneys of chinook salmon (*Oncorhynchus tshawytschae*) by Doty and Slater (1946), and named as *Heterosporium tshawytschae*. Subsequently, there have been no further reports on this fungus as a fish pathogen. This species was first described as *Heterosporium tshawytschae* and transferred to the genus *Scolecobasidium* by McGinnis and Ajello (1974) and subsequently recognized as *O. tshawytschae* by Kirilenko and All-Achmed (1977). Conidia of this species are characteristically four-celled and verrucose. Alternatively, *Ochroconis humicola* also was reported as a fish pathogen from the kidney of coho salmon (*Oncorhynchus kisutch*) and rainbow trout (*Salmo gairdneri*) by Ross and Yasutake (1973) and Ajello et al. (1977). The latter authors reported this fungus as belonging to the genus *Scolecobasidium*, but it was transferred to the new genus *Ochroconis* by de Hoog and von Arx (1973). Conidia of this species are characteristically two-celled and smooth-walled.

A mycosis similar to that described by the above authors was found in cultured

masu salmon (*Oncorhynchus masou*) at a farm in Kumamoto Prefecture, Japan (32°50'N, 131°10'E) in 1984. The disease tended to occur chronically in 2-yr-old fish. Deaths were first noticed at the beginning of the year, and mortality continued until the fish were shipped or used for spawning in the late autumn of the same year. Approximately 2,000 of 5,000 fish died of the disease during that epizootic. These fish were reared in a pond supplied with spring water with a fairly constant temperature of 14 C. Preliminary observations of moribund fish revealed that their kidneys were seriously infected with a fungus similar to *Ochroconis tshawytschae*; no other causative agents were found in those fish. This paper describes a hitherto unrecorded visceral mycosis in Japan caused by a species of the genus *Ochroconis* which is similar to, but apparently different from, *O. tshawytschae*.

MATERIALS AND METHODS

Seven fish averaging 30 cm in body length and 350 g in body weight, dying from mycosis, were collected from the infected pond on 24 July 1984. Tissues from the kidney, spleen, liver, intestine, gills and lateral musculature were fixed in 10% phosphate-buffered formalin solution. The fixed tissues were processed into paraffin and 3 to 5 μ m sections were stained with haema-

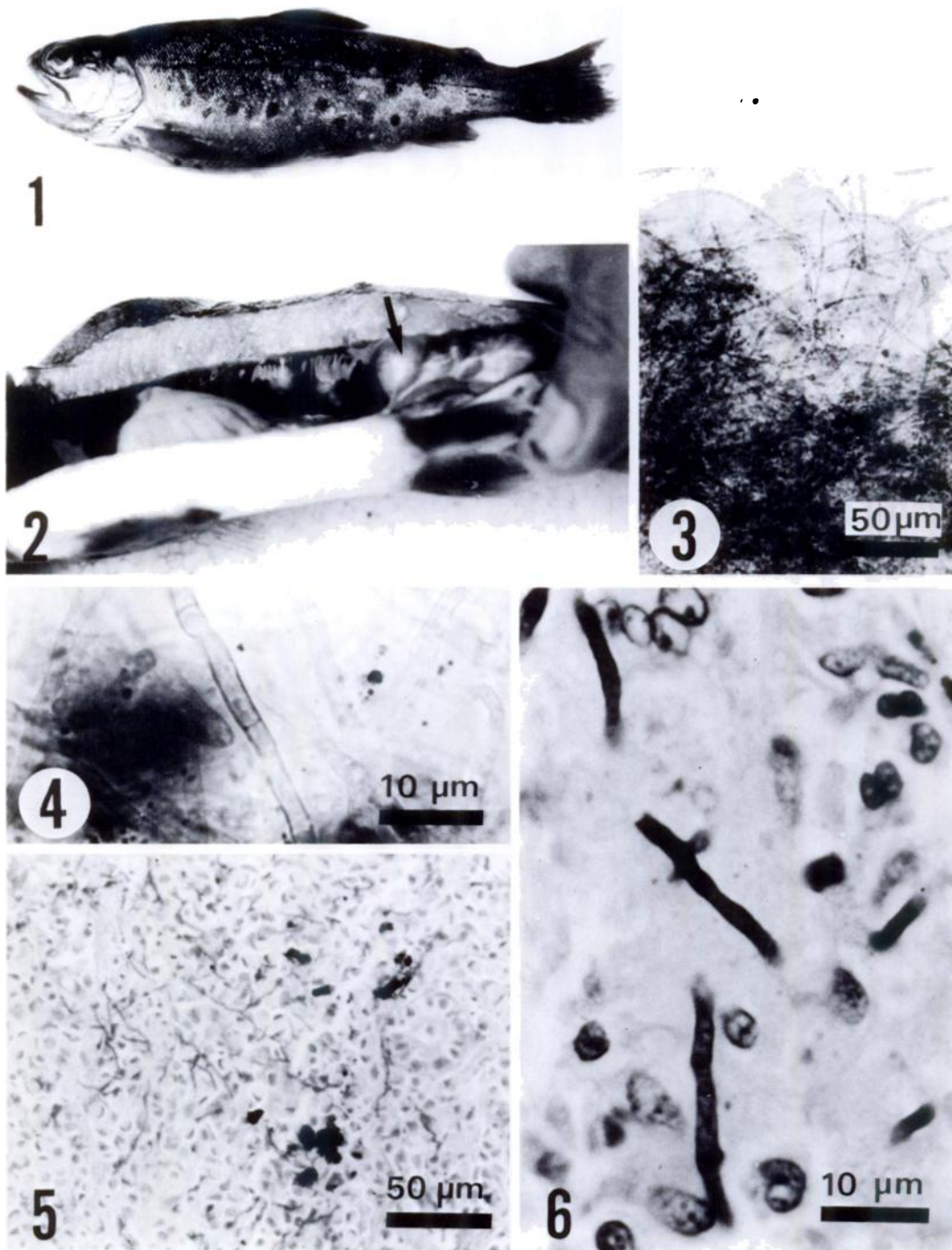


FIGURE 1. Gross lesions of masu salmon infected with *Ochroconis* sp. in Japan. Note reddening of the anal area and swelling of the abdomen. Body length 30 cm.

FIGURE 2. Gross lesions of masu salmon infected with *Ochroconis* sp. Note the posterior kidney (arrow) showing swelling and discolouration.

FIGURE 3. Hyphae of *Ochroconis* sp. from an infected kidney of masu salmon.

toxylin and eosin (H&E), Giemsa or periodic-acid schiff (PAS).

The fungus was isolated by inoculating a piece of kidney, a block of approximately 2 mm in diameter, from a dying masu salmon onto Sabouraud dextrose agar "Eiken" (SDA) and glucose-yeast extract (GY) agar (Hatai and Egusa, 1979) and incubating at 15 C. For inhibition of most bacterial growth, the addition of 500 µg/ml each of penicillin and streptomycin to the media was required. Growing fungal colonies were subcultured onto GY agar to obtain pure cultures. The isolated fungus was maintained at 15 C on GY agar, and transferred to fresh GY agar once every 3 mo for maintenance. A typical isolated strain, NJM 8404, was used for all experiments. *Scolecobasidium tshawytschae* (ATCC 9915), which is now transferred to the genus *Ochroconis*, was used as a reference fungus. The isolated fungus was identified according to von Arx (1981) and Howard (1983). Five different media, PYGS agar (peptone, 1.25 g; yeast extract, 1.25 g; glucose, 3.00 g; agar, 15 g; artificial sea water, 1,000 ml) (Bian et al., 1979), Sabouraud dextrose agar "Eiken" (SDA), nutrient agar "Eiken" (NA), potato dextrose agar "Eiken" (PDA) and GY agar were made up with distilled water (except for PYGS) and 20 ml were dispensed into plastic petri dishes established in two replicates. The inoculum consisted of PYGS agar blocks, 5.5 mm in diameter, which were cut from the edges of actively growing colonies. These were transferred to the centers of 8.25 cm diameter plastic petri dishes. Each inoculated petri dish was incubated at 25 C and the growth rate of the fungus was determined by making two measurements of colony diameter with vernier calipers.

For measurements of conidial dimensions, the isolates NJM 8404 and *Ochroconis* (= *Scolecobasidium*) *tshawytschae* ATCC 9915 were inoculated onto PYGS agar and incubated at 25 C for 30 days.

RESULTS

In almost all cases, the external clinical signs in infected fish were reddening of the anal area, swelling of the abdomen due to accumulation of pale red ascitic fluid (Fig. 1) and anaemia of the gills. The characteristic internal sign was a swollen and

discoloured posterior kidney (Fig. 2). In some cases, white nodular foci containing many septate hyphae, were found in the kidney, and rarely in the liver and spleen. Many pale brown septate hyphae, 1.5 to 2.5 µm in diameter, were observed microscopically in the kidney (Figs. 3, 4); rarely were they observed in other organs of infected fish.

Histopathological examination showed fungal hyphae present in the kidneys of all moribund fish (Figs. 5, 6), and in the spleen and liver in rare cases. In some of the fish examined, hyphae also were found in the musculature adjacent to the posterior kidney, but not to the anterior kidney. Infiltration of inflammatory cells including lymphocytes, neutrophils and macrophages were usually found adjacent the fungal hyphae. Many inflammatory cells, necroses and large granulomas with fungal hyphae were found in the posterior kidney (Fig. 7). The granulomas consisted of mononuclear cells including neutrophils and macrophages, epithelioid cells and fibrillar structures. Langhans's giant cells were often observed in the granulomas. Small granulomas also were found in the liver and spleen in rare cases. The extensive swelling of the posterior kidney, where it occurred, was due to the large granulomas.

Fungal colonies on both media used for the isolation were slow-growing; colonies were slightly domed, felt-like to velvety and pale dark brown in colour (Fig. 8). Conidia were usually sparse, four-celled, verrucose, pale brown in colour and cylindrical with rounded ends (Fig. 9). The reproductive mode of the conidia was sympodial. The fungus was identified as a species of the genus *Ochroconis* according to de Hoog and von Arx (1973) and Howard (1983) from the characteristics as men-

←
FIGURE 4. Higher magnification of septate hyphae of *Ochroconis* sp. from masu salmon.

FIGURE 5. Section of granuloma in kidney of masu salmon section showing numerous fungal hyphae of *Ochroconis* sp. PAS.

FIGURE 6. Section of granuloma in kidney of masu salmon showing high-power view of septate hyphae of *Ochroconis* sp. PAS.

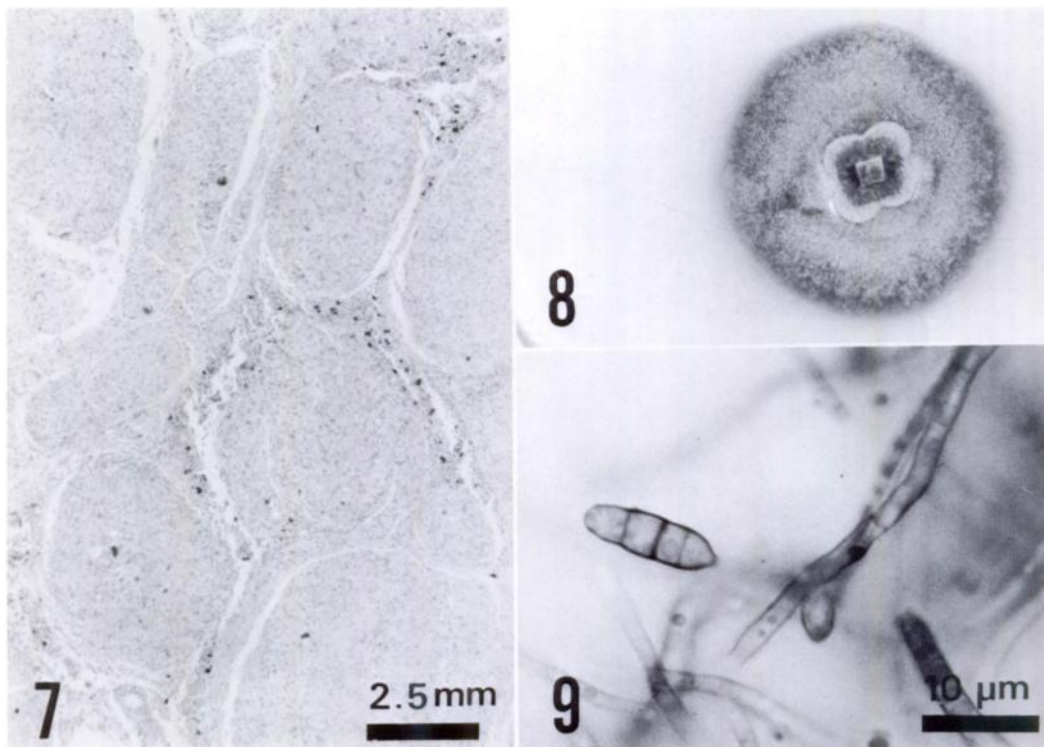


FIGURE 7. Section of kidney showing numerous granulomas from masu salmon infected with *Ochroconis* sp. H&E.

FIGURE 8. 30-day-old colony of isolate NJM 8404 on PYGS agar incubated at 25 C. Colony radius 18.3 mm.

FIGURE 9. Four-celled conidia of the isolate NJM 8404 on PYGS agar.

tioned above. De Hoog and von Arx (1973) listed seven valid species in the genus *Ochroconis*. Comparison of the characteristics of these seven species and the isolate NJM 8404, the fungus we isolated more closely resembled *O. variabilis*, which has four-celled conidia rather than *O. humicola* known as a fish pathogen, which has two-celled conidia. However, *O. variabilis* is now classified as synonym of *O. tshawytschae* by Kirilenko and All-Achmed (1977).

The effect of various media on the growth of the isolate NJM 8404 and of *O. tshawytschae* ATCC 9915 was compared. The mean colony radii of the isolate NJM 8404 were 18.3, 16.8, 14.0, 17.9 and 18.1 mm on PYGS agar, SDA, NA, PDA and GY agar, respectively, after 30 days growth at 25 C. Radii of the isolate ATCC

9915 were 13.2, 17.0, 13.2, 18.9 and 16.6 mm on PYGS agar, SDA, NA, PDA and GY agar, respectively, after 30 days growth at 25 C (Table 1). Both of the isolates were slow-growing on the various media. However, isolate NJM 8404 characteristically grew faster than isolate ATCC 9915 on the PYGS agar with artificial sea water. The best media was PYGS agar, PDA and GY agar for the isolate NJM 8404 and PDA for the isolate ATCC 9915.

The conidial dimensions are shown in Table 2. Conidia of both isolates were two- to four-celled (usually four-celled) and verrucose. However, the production of conidia were more abundant in isolate ATCC 9915 than in isolate NJM 8404. Also, the conidia of isolate NJM 8404 were shorter than those of isolate ATCC 9915 (Table 2).

TABLE 1. Comparison of growth rates based on mean colony radii (mm) using various media between the *Ochroconis* sp. isolate NJM 8404 from dying masu salmon (*Oncorhynchus masou*) with visceral mycosis and *Ochroconis tshawytschae* ATCC 9915. Incubation was at 25 C.

Media	<i>Ochroconis</i> sp. NJM 8404			<i>O. tshawytschae</i> ATCC 9915		
	Days after incubation			Days after incubation		
	10	20	30	10	20	30
PYGS agar	8.1	12.2	18.3	5.3	8.6	13.2
Sabouraud dextrose agar (SDA)	6.1	10.7	16.8	7.5	11.4	17.0
Nutrient agar (NA)	5.8	9.5	14.0	6.7	10.4	13.2
Potato dextrose agar (PDA)	7.5	12.0	17.9	7.6	11.9	18.9
GY agar	7.7	12.0	18.1	7.0	11.2	16.6

DISCUSSION

In Japan, some visceral mycoses in fish due to Fungi Imperfecti have been reported. They are the gastro-tympanities in amago salmon (*Onchorhynchus rhodurus*) caused by *Candida sake* (Hatai and Egusa, 1975), visceral mycosis in amago salmon fry caused by an unidentified filamentous fungus with septa (Hatai and Egusa, 1977) and visceral mycosis in ayu fry (*Plecoglossus altivelis*) caused by a species of *Phoma* (Hatai et al., 1986). Therefore, the occurrence of a visceral mycosis caused by a species of *Ochroconis* is the first report of this infection in Japan. However, we could not define the reason why the *Ochroconis* sp. infection had occurred only at a farm in Kumamoto Prefecture. Following the initial epizootic, we made an effort to find the visceral mycosis in masu salmon at other farms, but without success. The disease usually occurred in 2-yr-old fish, but not in the young fish; this suggests that the disease was probably chronic. The disease

only occurred in masu salmon, not in amago salmon and rainbow trout reared at the same farm. This showed that masu salmon had a high sensitivity to this particular infection.

The histopathological observations suggest that the main site of infection was the posterior kidney. *Exophiala* sp. (Fungi Imperfecti) infection of fish, characterized by swollen kidneys, is well known (Ross and Yasutake, 1973; Ajello et al., 1977; Richards et al., 1978; Alderman and Feist, 1985; Otis and Wolke, 1985). It was interesting that the histopathological findings observed in the visceral mycosis of masu salmon resembled those of *Exophiala* sp. infection and giant cells also were observed in the granulomas of the kidney of rainbow trout with *Exophiala* sp. infection (Alderman and Feist, 1985). The distribution of fungal hyphae in the masu salmon strongly suggests that the fungus developed first in the kidney, formed large granulomas and then penetrated through the kidney into the liver, spleen and mus-

TABLE 2. Comparison of conidial dimension (length × width) expressed as ranges and (means) in μm between *Ochroconis* sp. isolate NJM 8404 from dying masu salmon (*Oncorhynchus masou*) with visceral mycosis and *Ochroconis tshawytschae* ATCC 9915. The fungi were grown on PYGS agar for 30 days at 25 C.

Number of cells in conidia	<i>Ochroconis</i> sp. NJM 8404		<i>O. tshawytschae</i> ATCC 9915	
	Conidial dimension	Frequency (%)	Conidial dimension	Frequency (%)
2	5.5–10 (8.1) × 3.0–4.5 (3.4)	27	8.0–14.8 (11.1) × 2.8–4.5 (3.4)	26
3	7.5–10.5 (9.3) × 3.0–4.8 (3.3)	11	11.3–17.5 (14.6) × 2.8–4.5 (3.3)	25
4	10.0–17.5 (11.9) × 2.8–4.5 (3.7)	62	15.0–18.8 (17.0) × 2.8–5.0 (3.9)	50

culature. A functional disorder due to the formation of large granulomas and necroses in the kidney was thought to be the cause of death.

The isolate NJM 8404 from masu salmon showed a close resemblance to *O. tshawytschae* ATCC 9915. However, it differed in some biological characteristics and conidial size. Therefore, the fungus was regarded as a new species of the genus *Ochroconis*. The detailed and formal description of the new pathogenic *Ochroconis* sp., isolated from masu salmon, will be presented elsewhere.

ACKNOWLEDGMENTS

The authors would like to express their thanks to L. G. Willoughby, Freshwater Biological Association, Ambleside, Cumbria, United Kingdom for his critical review of the manuscript. They also would like to express their gratitude to S. Sumida, Kumamoto Prefectural Fisheries Experimental Station for his assistance while sampling, and N. Kuroda, their student, for his technical assistance.

LITERATURE CITED

- AJELLO, L., M. R. MCGINNIS, AND J. CAMPER. 1977. An outbreak of phaeohyphomycosis in rainbow trout caused by *Scolecobasidium humicola*. *Mycopathologia* 62: 15-22.
- ALDERMAN, D. J., AND S. W. FEIST. 1985. *Exophiala* infection of kidney of rainbow trout recovering from proliferative kidney disease. *Transactions of the British Mycological Society* 84: 157-185.
- BIAN, B. Z., K. HATAI, G. L. PO, AND S. EGUSA. 1979. Studies on the fungal diseases in crustaceans—I. *Lagenidium scyllae* sp. nov. isolated from cultivated ova and larvae of the mangrove crab (*Scylla serrata*). *Transactions of the Mycological Society of Japan* 20: 115-124.
- DE HOOG, G. S., AND J. A. VON ARX. 1973. Revision of *Scolecobasidium* and *Pleurophragmium*. *Kavaka* 1: 55-60.
- DOTY, M. S., AND D. W. SLATER. 1946. A new species of *Heterosporium* pathogenic on young chinook salmon. *American Midland Naturalist* 36: 663-665.
- HATAI, K., AND S. EGUSA. 1975. *Candida sake* from gastro-tympanites of amago, *Oncorhynchus rhodurus*. *Bulletin of the Japanese Society of Scientific Fisheries* 41: 993.
- , AND ———. 1977. Studies on visceral mycosis of salmonids fry—II. Characteristics of fungi isolated from the abdominal cavity of amago salmon fry. *Fish Pathology* 11: 187-193. [in Japanese.]
- , AND ———. 1979. Studies on the pathogenic fungus of mycotic granulomatosis—III. Development of the medium for MG-fungus. *Fish Pathology* 13: 147-152. [in Japanese.]
- , Y. FUJIMAKI, S. EGUSA, AND Y. JO. 1986. A visceral mycosis in ayu fry, *Plecoglossus altivelis* Temminck & Schlegel, caused by a species of *Phoma*. *Journal of Fish Diseases* 9: 111-116.
- HOWARD, D. H. 1983. Fungi pathogenic for human and animals, Part A. Biology. Marcel Dekker, Inc., New York, New York, 652 pp.
- KIRILENKO, T. C., AND M. A. ALL-ACHMED. 1977. *Ochroconis tshawytschae* (Doty et Slater) comb. nov. *Mikrobiologichnii Zhurnal* 39: 303-306.
- MCGINNIS, M. R., AND L. AJELLO. 1974. *Scolecobasidium tshawytschae*. *Transactions of the British Mycological Society* 63: 202-203.
- OTIS, E. J., AND R. E. WOLKE. 1985. Infection of *Exophiala salmonis* in Atlantic salmon (*Salmo salar* L.). *Journal of Wildlife Diseases* 21: 61-64.
- RICHARDS, R. H., A. HOLLIMAN, AND S. HELGASON. 1978. *Exophiala salmonis* infection in Atlantic salmon, *Salmo salar* L. *Journal of Fish Diseases* 1: 357-368.
- ROSS, A. J., AND W. T. YASUTAKE. 1973. *Scolecobasidium humicola*, a fungal pathogen of fish. *Journal of the Fisheries Research Board of Canada* 30: 994-995.
- VON ARX, J. A. 1981. The genera of fungi. J. Cramer, Vaduz, Federal Republic of Germany, 424 pp.

Received for publication 8 February 1988.