



FUSOBACTERIUM NECROPHORUM AND ACTINOMYCES PYOGENES ASSOCIATED FACIAL AND MANDIBULAR ABSCESSSES IN BLUE DUIKER

Authors: Roeder, B. L., Chengappa, M. M., Lechtenberg, K. F.,
Nagaraja, T. G., and Varga, G. A.

Source: Journal of Wildlife Diseases, 25(3) : 370-377

Published By: Wildlife Disease Association

URL: <https://doi.org/10.7589/0090-3558-25.3.370>

BioOne Complete (complete.BioOne.org) is a full-text database of 200 subscribed and open-access titles in the biological, ecological, and environmental sciences published by nonprofit societies, associations, museums, institutions, and presses.

Your use of this PDF, the BioOne Complete website, and all posted and associated content indicates your acceptance of BioOne's Terms of Use, available at www.bioone.org/terms-of-use.

Usage of BioOne Complete content is strictly limited to personal, educational, and non - commercial use. Commercial inquiries or rights and permissions requests should be directed to the individual publisher as copyright holder.

BioOne sees sustainable scholarly publishing as an inherently collaborative enterprise connecting authors, nonprofit publishers, academic institutions, research libraries, and research funders in the common goal of maximizing access to critical research.

FUSOBACTERIUM NECROPHORUM AND ACTINOMYCES PYOGENES ASSOCIATED FACIAL AND MANDIBULAR ABSCESSSES IN BLUE DUIKER

B. L. Roeder,¹ M. M. Chengappa,² K. F. Lechtenberg,³
T. G. Nagaraja,³ and G. A. Varga⁴

¹ Department of Veterinary Science, Pennsylvania State University, University Park, Pennsylvania 16802, USA

² Department of Laboratory Medicine, Kansas State University, Manhattan, Kansas 66506, USA

³ Department of Animal Science and Industry, Kansas State University, Manhattan, Kansas 66506, USA

⁴ Department of Dairy and Animal Science, Pennsylvania State University, University Park, Pennsylvania 16802, USA

ABSTRACT: Anaerobic and aerobic cultures of facial and mandibular abscesses were made from 12 blue duiker (*Cephalophus monticola fuscicolor*) housed at the Deer and Duiker Research Facility of the Pennsylvania State University (USA). Increases in concentrations of total protein and serum globulin occurred in all cases. *Actinomyces pyogenes* was isolated from nine animals. *Fusobacterium necrophorum* was present in eight and *Bacteroides* sp. was found in seven animals; other genera of isolated bacteria included: *Streptococcus* (from two animals), *Lactobacillus* (one), *Staphylococcus* (one) and *Actinomyces* (two). Eight (67%) of affected animals were ≤ 2 yr of age. Facial soft tissues and mandibles were the tissues most often affected. Tissues within the oral cavity were not affected at the time of presentation. A common finding, not reported in other host species with necrobacillosis, was the presence of nondestructive mandibular proliferation.

Key words: Blue duiker, *Cephalophus monticola fuscicolor*, *Fusobacterium necrophorum*, *Actinomyces (Corynebacterium) pyogenes*, staphylococcal and streptococcal abscesses, case reports, pathology.

INTRODUCTION

Fusobacterium necrophorum infection, commonly called necrobacillosis, occurs in many species and in domestic ruminants causes infectious pododermatitis, liver abscessation, necrotic laryngitis, necrotic stomatitis, ulcerative rumenitis and omphalophlebitis (Egerton et al., 1969; Roberts and Egerton, 1969; Berg and Scanlan, 1982; Scanlan and Hathcock, 1983; Blood et al., 1985; Wass et al., 1986; Whitlock, 1986). This bacterium has been identified from oral abscesses in white-tailed deer (*Odocoileus virginianus*) (Wobeser et al., 1975; Rosen, 1981) and in necrobacillosis syndromes found in white-tailed deer and pronghorn antelope (*Antilocapra americana*) (Wobeser et al., 1975). Oral lesions commonly affect the tongue, oral mucosa at the angle of the mandible, and the mandibular symphysis and its adjacent soft tissue. The interalveolar area, premolar and molar region, hard palate, and pharynx are less commonly affected (Wobeser et al., 1975). Oral necrobacillosis affects primar-

ily soft tissue, but secondary extension to the sphenoid bones and mandible producing necrosis and osteomyelitis has been documented (Wobeser et al., 1975; Blood et al., 1985). Invasive lesions frequently result in the loss of incisors, premolars or molars. In this report, we describe the clinical findings and bacterial isolates from facial and mandibular abscesses in 12 blue duiker antelope (*Cephalophus monticola fuscicolor*) exhibiting atypical necrobacillosis.

MATERIALS AND METHODS

Between March 1987 and January 1988, facial or mandibular abscesses occurred in 12 blue duiker antelope housed at the Deer and Duiker Research Facility, Pennsylvania State University (PSU; University Park, Pennsylvania 16802, USA). Animals were kept in 2.44 × 1.22 × 1.83 m enclosures (one male and two females per pen, with or without nursing offspring) with sanichip flooring on cement, covered by 12 cm of clean grass hay. The average herd size during this period was 75 animals. The diet consisted of a pelleted ration (PSU formulation), quality alfalfa hay, trace mineral salt block, and fresh water ad libitum. All animals in the herd were

TABLE 1. Signalment and clinical findings in 12 blue duiker with facial and mandibular necrobacillosis.

Animal number	Sex ^a	Age	Body temperature at presentation ^b	Clinical signs
1	F	4.5 yr	101.2	Abscessed left mandible, normal attitude with small drainage opening
2	F	2.5 yr	103.7	Closed abscess on right side of face involving mandible, slightly depressed
3	M	1 yr	103.2	Closed abscess right side of face and mandible, slightly depressed
4	M	11 mo	103.5	Closed abscess left mandible, slightly depressed
5	F	1 yr	105.9	Closed right facial swelling, moderate depression
6	M	2 yr	107.3	Draining large abscess right mandible, moderate depression
7	F	1 yr	102.4	Right facial abscess open and draining, purulent exudate, slight depression
8	F	6 wk	103.9	Draining abscess extending from left jugular furrow up to base of left ear, quiet attitude
9	F	5 yr	103.6	Right submandibular abscess, normal attitude, purulent exudate and submandibular salivary fistula present
10	F	2 yr	103.9	Right submandibular abscess, normal attitude
11	F	2 yr	103	Left lower facial swelling at maxilla, slight depression
12	M	3.5 yr	102	Right mandibular abscess, normal attitude

^a F, female; M, male.

^b Degrees Fahrenheit.

weighed and their temperatures recorded on a weekly basis. Daily observations of each animal were made by animal caretakers during routine pen cleaning. Any animal exhibiting a facial or mandibular swelling with or without signs of exudate was included in the study. Pre-treatment blood samples were collected from each animal by jugular venipuncture. Complete blood counts (CBC) and serum chemistry profiles (Technicon SMAC 23/30, Upsher Laboratories, Inc., Kansas City, Missouri 64106, USA), some including sorbitol dehydrogenase (SDH) and magnesium, were performed on each animal prior to initiation of antimicrobial therapy.

Affected animals were weighed and the rectal temperature recorded. Duikers were manually restrained in lateral recumbency for collection procedures. After aseptic preparation of the affected tissue, a sterile 18 gauge needle attached to a sterile 3 cc Monoject® (Monoject® Division of Sherwood Medical, St. Louis, Missouri 63103, USA) syringe was used to enter the swollen site at its ventral midpoint to facilitate adequate drainage and collection of aspirates for bacteriologic studies. After collection of the specimen all air bubbles were expelled from the syringe and needle, and the needle tip was inserted into a rubber stopper to prevent the admission of air. Specimens were immediately shipped on ice to the laboratory (Breathitt Veterinary Center, Murray State University, Hopkinsville, Kentucky 42240, USA) in styrofoam containers.

Aspirates were cultured on 5% sheep blood

agar aerobically and anaerobically at 37 C for up to 5 days. Direct examination of smears stained with Gram-stain from infected tissues was performed on all samples. Bacterial isolates were identified based on Gram-stain reaction, cultural characteristics, morphologic appearance, and the results of standard biochemical tests (Carter, 1984; Krieg and Holt, 1984).

Animals were given systemic antimicrobial agents as well as local treatment of lesions based on bacterial culture and sensitivity results, and the degree of tissue involvement. Local therapy included debridement, flushing with antimicrobial solutions and placement of drains. These results will be reported elsewhere.

RESULTS

Twelve blue duiker antelope (both male and female), aged 6 wk to 5 yr, had moderate to severe facial or mandibular inflammation with purulent exudate present. Eight (67%) of the affected animals were ≤ 2 yr of age. All animals had tissue swelling, slight to moderate depression, and mild to moderate temperature elevation (Table 1). Facial soft tissues and the bony mandible were most often affected (Figs. 1, 2). Eight of the abscesses were on the right side of the face or jaw. Radiographs revealed marked fusiform thickening of

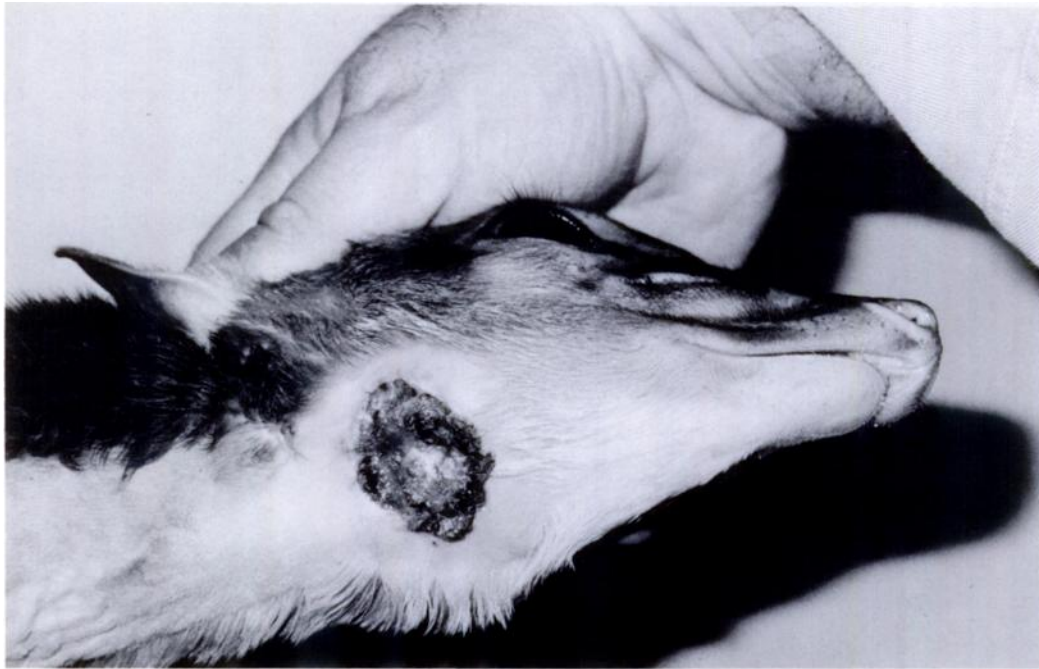

FIGURE 1. Draining right submandibular abscess from a blue duiker with a submandibular salivary gland fistula and extensive soft tissue necrosis.

mandibular bone; some were approximately four times normal thickness, primarily in mid shaft, tapering toward both ends with no gross abnormality of the associated dental arcade (Fig. 3). One duiker had a submandibular salivary fistula associated with the abscess site.

Fusobacterium necrophorum was isolated from eight animals, and presumptive evidence of its presence in the other cases was indicated by the observation of gram-negative, beaded filamentous organisms in impression smears from necrotic lesions. A variety of other organisms were also isolated from the lesions (Table 2). The most commonly isolated organism was *Actinomyces pyogenes*. This bacterium was present in nine of the specimens, and was the only bacterium isolated in three of the cases.

Total plasma protein concentration was elevated in all affected duiker. Neutrophilic leukocytosis was present in one case while other total white blood cell counts were within normal reference range (B. L.

Roeder, unpubl. data) or exhibited a leukocytosis characterized by shifts in the L:N ratio above or below the usual 70:30 range. The total protein and globulin concentration were elevated above normal ranges in all cases. One animal succumbed to disseminated sepsis and died. The other animals responded to therapy (antimicrobial agents and local treatment of lesions including debridement, flushing with antimicrobial solutions and placement of drains), and except for remaining mandibular proliferation, returned to the breeding herd and were healthy.

DISCUSSION

Epizootics of necrobacillosis have been described in wild ungulates including reindeer (*Rangifer tarandus*), white-tailed deer, elk (*Cervus elaphus nelsoni*) and pronghorn (*Antilocapra americana*) (Murie, 1930; Wobeser et al., 1975; Rosen, 1981). Overcrowding at waterholes or feeding areas, overbrowsing, weather extremes, and introduction to pastures shared

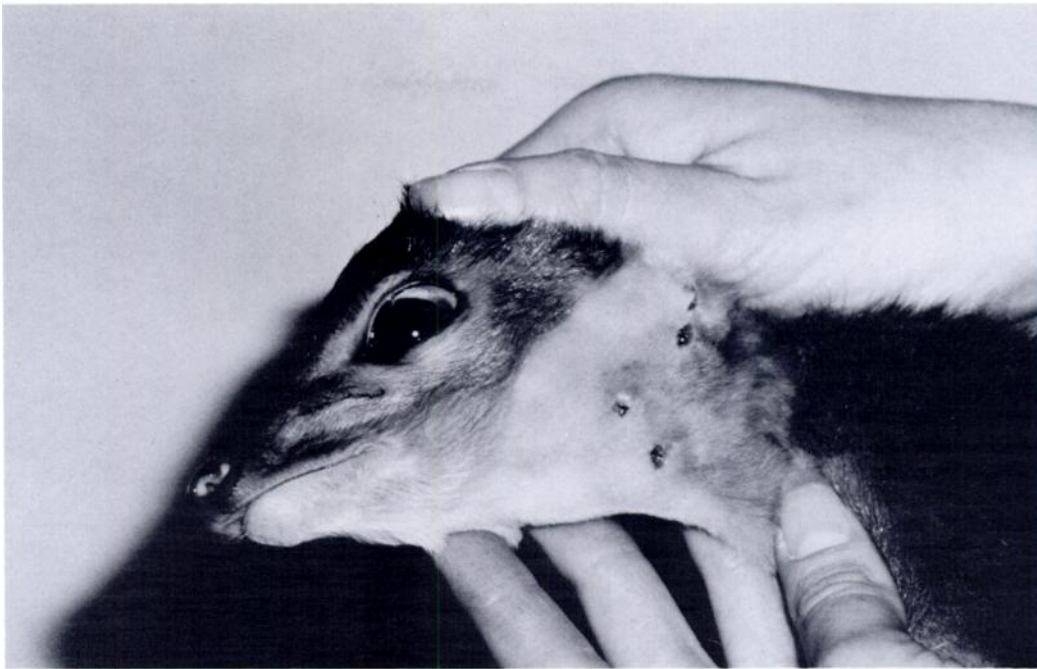

FIGURE 2. A young duiker exhibiting multiple draining sites of left facial abscessation extending from the base of the ear to the left jugular furrow.

by domestic livestock with footrot infections have been cited as contributing factors (Wobeser et al., 1975; Rosen, 1981; Carter, 1984). The blue duikers affected at our facility may have been overcrowded, especially when housed as an adult trio with nursing offspring. However, facial and mandibular abscesses in this herd appear to be related to the introduction of infected carrier animals brought to the PSU Deer and Duiker Research Facility from another zoological garden, coarse feed texture and masticatory behavior. Abscesses were most often on the right side of the face or jaw which correlates with observed patterns of mastication. The majority of duikers in the herd chew with a clockwise motion in which most of the food is kept on the right side of the oral cavity as the mandible is shifted (B. L. Roeder, unpubl. obs.). *Fusobacterium necrophorum* is usually considered to be unable to penetrate the intact mucosa (Jubb et al., 1985) and sharp or coarse plant material such as grass awns or forage particles are implicated as im-

portant in the pathogenesis of these lesions (Murie, 1930; Rosen, 1981; Jubb et al., 1985). Several previously affected members of this herd had lesions which contained plant material inside closed abscesses of the face or jaw.

Mixed populations of bacteria were present in most lesions. The common occurrence of *A. pyogenes* and *F. necrophorum* together in the mixed infections is supportive of the pathogenic synergism that exists between these two organisms (Roberts, 1967a, b; Carter, 1984; Smith and Williams, 1984). *Fusobacterium necrophorum* may also enhance the growth of certain *Bacteroides* spp., (Price and McCallum, 1986) apparently by producing a growth factor that provides a nutritional synergy between the two organisms.

Fusobacterium necrophorum is an obligate anaerobic commensal in the alimentary tract and on mucous membranes of man and animals (Smith and Williams, 1984), and has been recognized as a pathogen for many years (Murie, 1930; Roberts,

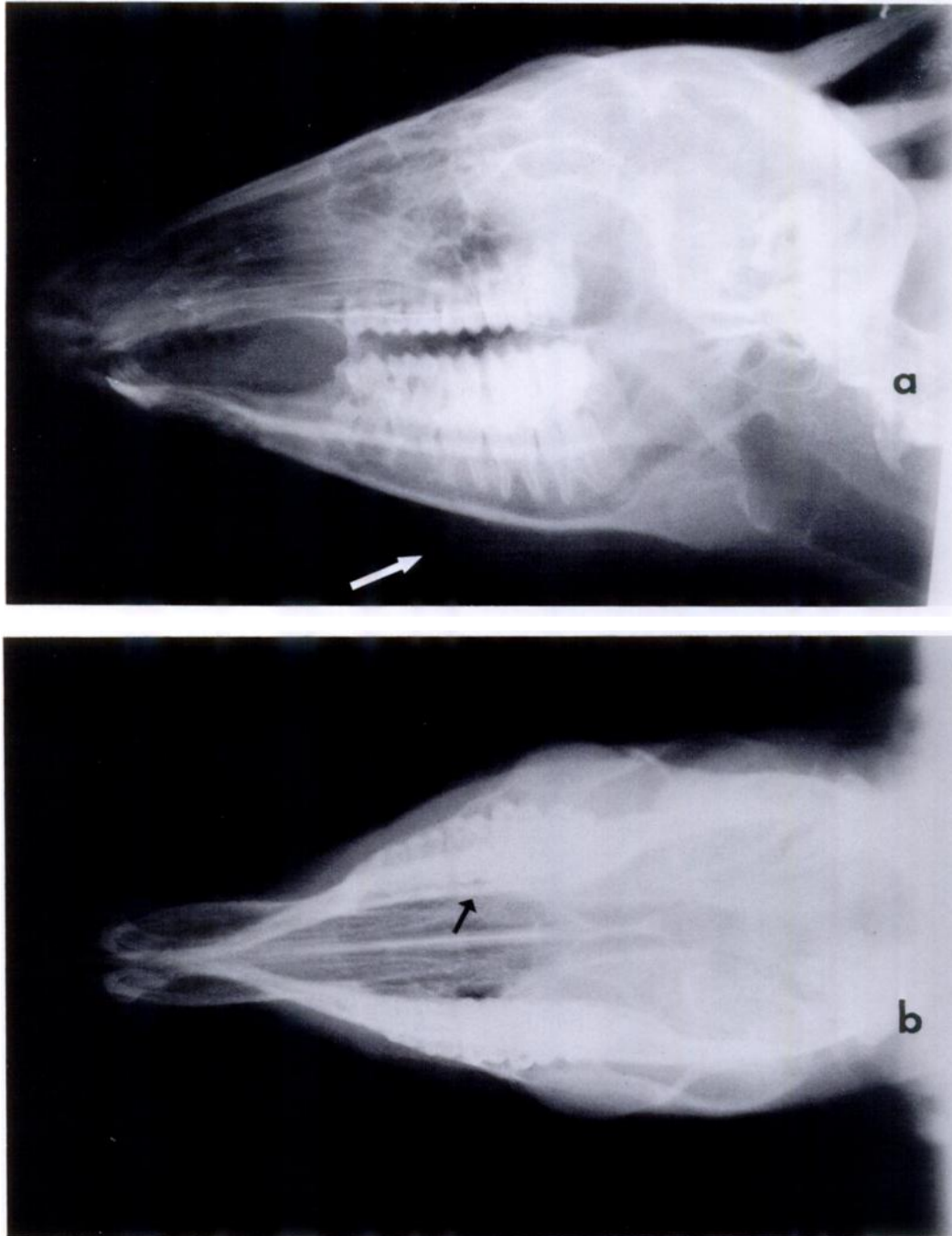


FIGURE 3. Ventrodorsal (a) and lateral (b) radiographic views of proliferative right mandibular osteomyelitis associated with a mixed bacterial granulomatous infection which included *F. necrophorum* and *A. pyogenes* in a duiker showing nondestructive mandibular proliferation.

TABLE 2. Results of bacterial cultures from 12 blue duiker with facial and mandibular abscesses.

Animal number	Abscess	Bacterial isolates
1	Mandible	<i>A. pyogenes</i> , <i>F. necrophorum</i> , <i>B. bivius</i> , α <i>Streptococcus</i> , <i>Lactobacillus</i> sp.
2	Mandible	<i>A. pyogenes</i> , <i>F. necrophorum</i> , <i>Staphylococcus</i> sp.
3	Mandible	<i>A. pyogenes</i>
4	Facial	<i>A. pyogenes</i>
5	Facial	<i>A. pyogenes</i> , <i>F. necrophorum</i> , <i>B. bivius</i>
6	Mandible	<i>F. necrophorum</i> , <i>B. bivius</i>
7	Facial	<i>A. pyogenes</i> , <i>F. necrophorum</i> , <i>B. bivius</i>
8	Facial	<i>A. pyogenes</i> , <i>F. necrophorum</i>
9	Mandible	<i>B. intermedius</i> , <i>B. asacharalyticus</i> , <i>A. meyeri</i>
10	Mandible	<i>A. pyogenes</i>
11	Facial	<i>A. pyogenes</i> , <i>F. necrophorum</i> , <i>Bacteroides</i> sp., <i>A. meyeri</i>
12	Mandible	<i>F. necrophorum</i> , <i>B. bivius</i> , <i>S. dysgalactiae</i>

^a *Actinomyces*.

^b *Fusobacterium*.

^c *Bacteroides*.

^d *Actinomyces*.

^e *Streptococcus*.

1967a, b; Langworth, 1977; Carter, 1984; Smith and Williams, 1984; Jubb et al., 1985; Price and McCallum, 1986). It can be difficult to isolate in vitro because of strict anaerobic requirements and overgrowth by less fastidious bacteria (Carter, 1984; Smith and Williams, 1984). Most infections are considered to be endogenous in origin (Carter, 1984); however, carrier animals have been implicated in the spread of this bacterium to previously uninfected animals (Wobeser et al., 1975; Langworth, 1977; Rosen, 1981; Carter, 1984). In mixed infections, *F. necrophorum* is probably the primary invasive and necrotizing agent that facilitates the establishment and growth of other bacteria such as *A. pyogenes* and *Bacteroides* spp. in the affected tissues (Roberts, 1967a, b; Langworth, 1977; Smith and Williams, 1984; Price and McCallum, 1986).

The lesions in blue duiker represent an atypical form of necrobacillosis as compared to other ungulates. Although *F. necrophorum* can cause mandibular osteomyelitis in other species (Murie, 1930), usually as a sequella to chronic bacterial infection, it is considered to be rare in domestic animals (Blood et al., 1985). The

infections in these duikers, however, often involved the bony mandible with no prior history of chronic infection at the site. Also, in other species in which *F. necrophorum* mandibular osteomyelitis has been confirmed, the lesion is nearly always a soft tissue and bony destructive process while nondestructive proliferation was an uncommon clinical finding (Jubb et al., 1985). Necrobacillosis or "lumpy jaw" attributed to *F. necrophorum*, *Nocardia* spp., *Actinomyces* spp., or *Bacteroides* spp. infection in captive macropods, including red kangaroo (*Macropus rufus*), eastern gray kangaroo (*M. giganteus*), agile wallaby (*M. agilis*) and parma wallaby (*M. parma*) have been described (Butler, 1981). Lesions seen in these macropods differ from those found in the blue duiker, the former having an acute disease exhibiting necrotic foci, often containing sequestra and extensive osteolysis (Butler, 1981). The initiation of mandibular osteomyelitis by *F. necrophorum* in other species is usually attributed to spread from adjacent periodontitis with resultant loss of teeth (Murie, 1930; Wobeser et al., 1975; Blood et al., 1985). The primary focus of oral necrobacillosis in other animals is most commonly the tongue, oral

mucosa at the angle of the mandible, and the mandibular symphysis and its adjacent soft tissue (Murie, 1930; Wobeser et al., 1975; Rosen, 1981).

The facial and mandibular abscesses due to *F. necrophorum* in blue duiker antelope had few characteristics shared by other species infected with necrobacillosis, except that younger animals comprised a large proportion of the cases (Wobeser et al., 1975; Rosen, 1981; Jubb et al., 1985). It is not known whether the age difference is due to greater susceptibility of young duikers to infection by *F. necrophorum* and *A. pyogenes* microorganisms, or their selection of particular portions of dried forage in the ration causing oral cavity injury, or some other factor. It has been shown that circulating antibodies to *F. necrophorum* do occur in adult animals and humans who have been exposed to this bacterium but have no overt signs of disease (Dack et al., 1938). However, experimental evidence indicates that these antibodies offer little or no protection against infection (Langworth, 1977). Eruption of teeth might provide a portal of entry for microbes in the initiation of oral necrobacillosis (Cass, 1947; Wobeser et al., 1975; Rosen, 1981). This possibility exists, but radiographic and physical examination revealed the affected region to be distal to fully erupted teeth.

ACKNOWLEDGMENTS

Robert C. Mothersbaugh and Roxie Maddux are gratefully acknowledged for their technical assistance. This paper is published as contribution Number 7982, Department of Veterinary Science, The Pennsylvania State University, and contribution Number 88-261-J from the Kansas Agricultural Experiment Station.

LITERATURE CITED

- BERG, J. N., AND C. M. SCANLAN. 1982. Studies of *Fusobacterium necrophorum* from bovine hepatic abscesses: Biotypes, quantitation, virulence, and antibiotic susceptibility. *American Journal of Veterinary Research* 43: 1580-1586.
- BLOOD, D. C., J. A. HENDERSON, AND O. M. RADOSTITS. 1985. Diseases caused by bacteria. V. *In Veterinary medicine: A textbook of the diseases of cattle, sheep, pigs, goats, and horses*, 6th ed., D. C. Blood and O. M. Radostits (eds.). Bailliere Tindall, London, England, 1,310 pp.
- BUTLER, R. 1981. Epidemiology and management of "lumpy jaw" in macropods. *In Wildlife diseases of the Pacific Basin and other countries*, M. E. Fowler (ed.). Proceedings of the 4th International Conference of the Wildlife Disease Association, Sydney, Australia. Fruitridge Printing, Sacramento, California, pp. 58-61.
- CARTER, G. R. 1984. Diagnostic procedures in veterinary bacteriology and mycology, 3rd ed. Charles C. Thomas, Springfield, Illinois, 515 pp.
- CASS, J. S. 1947. Buccal food impaction in white-tailed deer and *Actinomyces necrophorus* in big game. *The Journal of Wildlife Management* 11: 91-94.
- DACK, G. M., L. R. DRAGSTEDT, AND R. JOHNSON. 1938. Comparison of *Bacterium necrophorum* from ulcerative colitis in man with strains isolated from animals. *Journal of Infectious Disease* 62: 169-180.
- EGERTON, J. R., D. S. ROBERTS, AND I. M. PARSONSON. 1969. The aetiology and pathogenesis of ovine foot-rot. I. A histological study of the bacterial invasion. *Journal of Comparative Pathology* 79: 207-216.
- JUBB, K. V. F., P. C. KENNEDY, AND N. PALMER. 1985. *Pathology of Domestic Animals*, Vol. 1, 3rd ed. Academic Press, New York, New York, 574 pp.
- KRIEG, N. R., AND J. G. HOLT. 1984. *Bergey's manual of systematic bacteriology*, Vol. 1. Williams and Wilkins, Baltimore, Maryland, 964 pp.
- LANGWORTH, B. F. 1977. *Fusobacterium necrophorum*: Its characteristics and role as an animal pathogen. *Bacteriological Reviews* 41: 373-390.
- MURIE, O. J. 1930. An epizootic disease of elk. *Journal of Mammalogy* 11: 214-222.
- PRICE, S. B., AND R. E. MCCALLUM. 1986. Enhancement of *Bacteroides intermedius* growth by *Fusobacterium necrophorum*. *Journal of Clinical Microbiology* 23: 22-28.
- ROBERTS, D. S. 1967a. The pathogenic synergy of *Fusiformis necrophorus* and *Corynebacterium pyogenes*. I. Influence of the leukocidal exotoxin of *F. necrophorus*. *British Journal of Experimental Pathology* 48: 665-673.
- . 1967b. The pathogenic synergy of *Fusiformis necrophorus* and *Corynebacterium pyogenes*. II. The response of *F. necrophorus* to a filterable product of *C. pyogenes*. *British Journal of Experimental Pathology* 48: 674-679.
- , AND J. R. EGERTON. 1969. The aetiology and pathogenesis of ovine foot-rot. II. The pathogenic association of *Fusiformis nodosus* and *F. necrophorus*. *Journal of Comparative Pathology* 79: 217-226.

- ROSEN, M. N. 1981. Necrobacillosis. *In* Infectious diseases of wild mammals, 2nd ed, J. W. Davis, L. H. Karstad, and D. O. Trainer (eds.). The Iowa State University Press, Ames, Iowa, pp. 332–338.
- SCANLAN, C. M., AND T. L. HATHCOCK. 1983. Bovine rumenitis–liver abscess complex: A bacteriological review. *Cornell Veterinarian* 73: 288–297.
- SMITH, L. D. S., AND B. L. WILLIAMS. 1984. The pathogenic anaerobic bacteria, 3rd ed, Charles C. Thomas, Springfield, Illinois, 331 pp.
- WASS, W. M., J. R. THOMPSON, AND E. W. MOSS. 1986. Diseases of the ruminant stomach. *In* Current veterinary therapy: Food animal practice, 2nd ed., J. L. Howard (ed.). W. B. Saunders, Co., Philadelphia, Pennsylvania, pp. 741–743.
- WHITLOCK, R. H. 1986. Liver disease (hepatitis). *In* Current veterinary therapy: Food animal practice, 2nd ed., J. L. Howard (ed.). W. B. Saunders, Co., Philadelphia, Pennsylvania, pp. 741–743.
- WOBESER, G., W. RUNJE, AND D. NOBLE. 1975. Necrobacillosis in deer and pronghorn antelope in Saskatchewan. *Canadian Veterinary Journal* 16: 3–9.

Received for publication 6 September 1988.