



Parasitic Infection of the Seahorse (*Hippocampus erectus*)— A Case Report

Authors: Vincent, Amanda C. J., and Clifton-Hadley, Richard S.

Source: Journal of Wildlife Diseases, 25(3) : 404-406

Published By: Wildlife Disease Association

URL: <https://doi.org/10.7589/0090-3558-25.3.404>

BioOne Complete (complete.BioOne.org) is a full-text database of 200 subscribed and open-access titles in the biological, ecological, and environmental sciences published by nonprofit societies, associations, museums, institutions, and presses.

Your use of this PDF, the BioOne Complete website, and all posted and associated content indicates your acceptance of BioOne's Terms of Use, available at www.bioone.org/terms-of-use.

Usage of BioOne Complete content is strictly limited to personal, educational, and non - commercial use. Commercial inquiries or rights and permissions requests should be directed to the individual publisher as copyright holder.

BioOne sees sustainable scholarly publishing as an inherently collaborative enterprise connecting authors, nonprofit publishers, academic institutions, research libraries, and research funders in the common goal of maximizing access to critical research.

Parasitic Infection of the Seahorse (*Hippocampus erectus*)— A Case Report

Amanda C. J. Vincent¹ and Richard S. Clifton-Hadley,² ¹ Department of Zoology, Large Animal Research Group, University of Cambridge, Cambridge, England CB2 3EJ; ² Institute of Aquaculture, University of Stirling, Stirling, England FK9 4LA

ABSTRACT: This report details the development of a microsporidan infection in a colony of seahorses (*Hippocampus erectus*) caused by *Glugea heraldi*. Of 76 animals imported from Florida Bay (USA), two survived. A myxosporidan (*Sphaeromyxa* sp.) and an unidentified nematode infection were also diagnosed in the same colony, but these infections were not considered important, causative factors in the mortalities.

Key words: Seahorse, *Hippocampus erectus*, Microspora, *Glugea heraldi*, Myxosporea, *Sphaeromyxa* sp., case report.

This report describes disease conditions associated with the maintenance of a captive colony of seahorses (*Hippocampus erectus*). The seahorses, consisting of 45 females and 31 males, originated from Florida Bay between the Florida Keys and mainland Florida (USA, exact locality unknown). They were flown to England and introduced to a recirculating marine holding facility at the Department of Zoology, University of Cambridge (Cambridge, England CB2 3EJ). Each animal was examined for external signs of parasitic or fungal infection. As none was apparent, the seahorses were divided into nine random groups and added to 216 litre and 432 litre tanks. Water for this system was prepared by adding marine salt to tap water, which was then left to stand for 7 days before use. The water was maintained at 26 to 28 C, pH 8.3 and flow rate 1.25 litres/min. Used water was passed through biological and mechanical sand filters before ultraviolet light sterilization and return to the holding tanks. The seahorses were fed with frozen mysids and a live *Artemia* sp. Other seahorse species in the genus *Hippocampus*, including *H. reidi* (sympatric with *H. erectus*), *H. kuda* and *H. histrix* (both Indo-Pacific species), were introduced into the

system before and after the arrival of the *H. erectus* colony. At times they were held in the same tanks as *H. erectus*.

Thirty days after introduction to the holding tanks pinhead-sized cysts were observed on the abdomens and dorsal fins of *H. erectus* in two of the tanks. Although these animals were removed to a separate tank, similar cysts developed in other seahorses. The cysts were discrete initially but subsequently coalesced to produce white, raised areas ≥ 2 mm in diameter. These remained superficial in most cases but were overlaid with dermis and epidermis in the later stages of development (Fig. 1). As the condition progressed, individual cysts enlarged and further cysts appeared, spreading over the body. Affected animals exhibited no loss of appetite, despite rubbing areas with numerous lesions, especially in the lower tail region, such that the underlying bone was sometimes exposed. Seahorses with these lesions usually died shortly thereafter. Over a period of 6 mo, during which there was an apparent remission in some animals only to be followed by recurrence, all but two of the *H. erectus* died.

Necropsy of five seahorses showed that the cysts did not penetrate into the body cavity. Although similar cysts were associated with the ovaries of two specimens, these were subsequently shown to contain unidentified nematode larvae.

On histological examination the superficial cysts were identified as xenomas confined to the stratum compactum of the dermis. They contained developing and mature microsporidan spores (Fig. 1). Fresh preparations of the mature spores showed them to be similar in form and dimension to those of *Glugea heraldi* de-

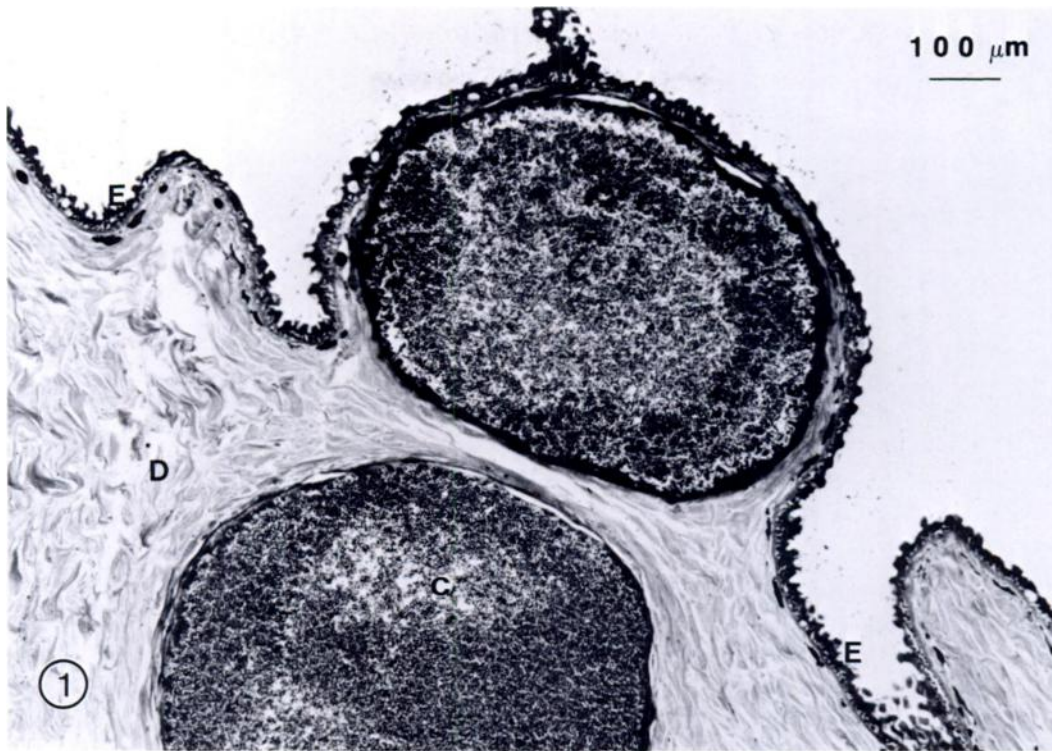


FIGURE 1. *Glugea heraldi* cysts within the stratum compactum of the dermis of *Hippocampus erectus*. C, cyst; D, dermis; E, epidermis. Giemsa.

scribed by Blasiola (1979) (Fig. 2). Where cysts had ruptured there was histological evidence of secondary bacterial invasion of surrounding tissues. There was no evidence of glugeal infection of internal organs. However, within two of the five gall bladders examined there were numerous *Sphaeromyxa* sp. spores (Fig. 3). There was no inflammatory response associated with these spores. *Sphaeromyxa sabralesi* has previously been described from both *H. guttulatus* and *H. brevisrostris* (Bellomy, 1969), but it has not been possible to find a previous record of this or any other species of sphaeromyxan in *H. erectus*.

No other species of seahorse in the holding tanks developed dermal cysts, despite close contact with diseased *H. erectus*. This may indicate that *G. heraldi* is species specific, although the possibility of a carrier state in another species cannot be excluded. In an early report of the disease in *H.*

erectus (Herald and Rakowicz, 1951) the seahorses were, as in the present case, from the Florida coast in North America. So although the initial examination of *H. erectus* stock on arrival in the United

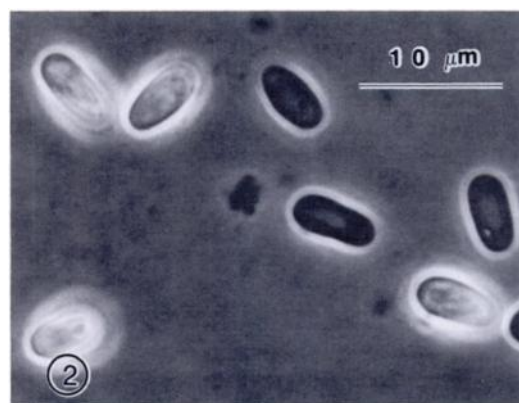


FIGURE 2. Phase contrast photomicrograph of viable and non-viable *Glugea heraldi* spores.

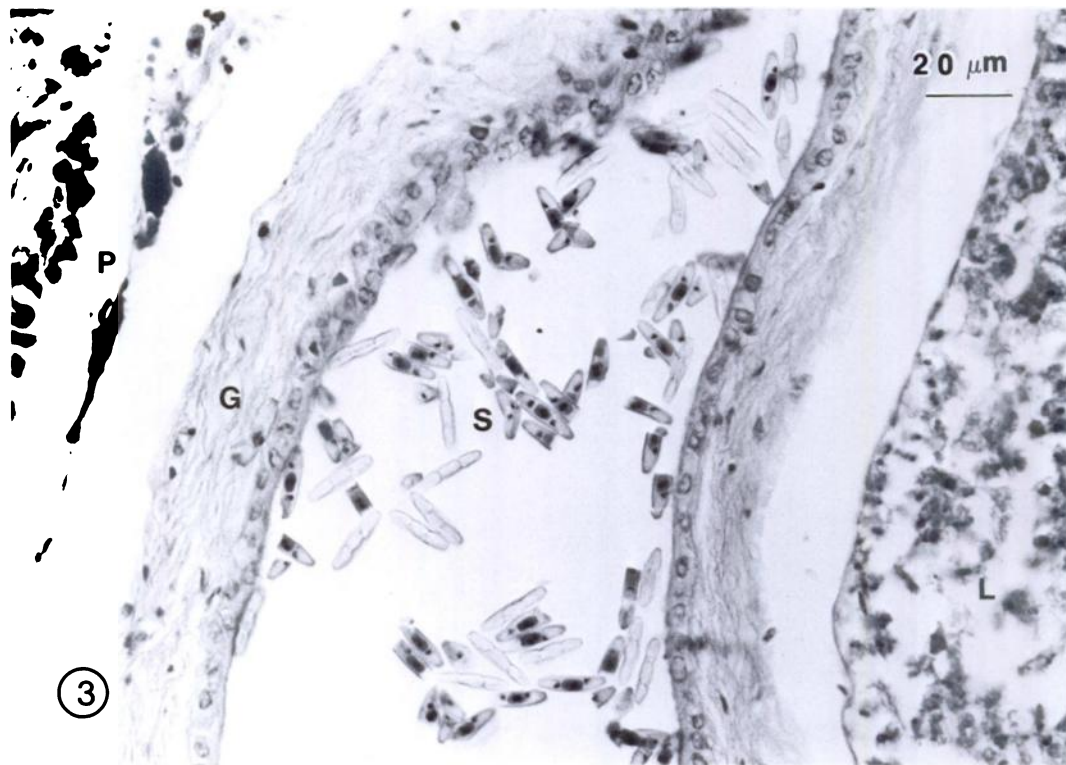


FIGURE 3. Sphaeromyxan spores within the gall bladder of *Hippocampus erectus*. G, gall bladder wall; L, liver; P, pancreatic tissue; S, spores. H&E.

Kingdom revealed no apparent, glugeal infection, it is likely that the animals were carrying the organism at the time of capture. These findings suggest that the disease may be endemic in Florida Bay. In the present case the animals were infected with several species of parasites. This indicates that new stock should be subjected to more than a visual examination before addition to established colonies. A quarantine period in excess of 28 days is also advisable.

LITERATURE CITED

- BELLOMY, M. D. 1969. Encyclopaedia of seahorses. Tropical Fish Hobbyist Publications, Reigate, Surrey, England, 192 pp.
- BLASIOLA, G. C. 1979. *Glugea heraldi* n. sp. (Microsporidia, Glugeidae) from the seahorse *Hippocampus erectus* Perry. *Journal of Fish Diseases* 2: 493-500.
- HERALD, E. S., AND M. RAKOWICZ. 1951. Stable requirements for raising sea horses. *Aquarium Journal* 22: 234-242.

Received for publication 13 September 1988.