

INTRACYTOPLASMIC NEURONAL INCLUSIONS IN WOODCHUCK BRAIN STEM

Authors: Pierce, Virginia, Snyder, Robert L., and McGrath, John T.

Source: Journal of Wildlife Diseases, 26(1) : 62-66

Published By: Wildlife Disease Association

URL: <https://doi.org/10.7589/0090-3558-26.1.62>

BioOne Complete (complete.BioOne.org) is a full-text database of 200 subscribed and open-access titles in the biological, ecological, and environmental sciences published by nonprofit societies, associations, museums, institutions, and presses.

Your use of this PDF, the BioOne Complete website, and all posted and associated content indicates your acceptance of BioOne's Terms of Use, available at www.bioone.org/terms-of-use.

Usage of BioOne Complete content is strictly limited to personal, educational, and non - commercial use. Commercial inquiries or rights and permissions requests should be directed to the individual publisher as copyright holder.

BioOne sees sustainable scholarly publishing as an inherently collaborative enterprise connecting authors, nonprofit publishers, academic institutions, research libraries, and research funders in the common goal of maximizing access to critical research.

INTRACYTOPLASMIC NEURONAL INCLUSIONS IN WOODCHUCK BRAIN STEM

Virginia Pierce,^{1,2} Robert L. Snyder,^{1,2,3} and John T. McGrath²

¹ Penrose Research Laboratory, Philadelphia Zoological Garden, Philadelphia, Pennsylvania 19104, USA

² Department of Pathobiology, University of Pennsylvania School of Veterinary Medicine, Philadelphia, Pennsylvania 19104, USA

³ Department of Pathology, School of Medicine, University of Pennsylvania, Philadelphia, Pennsylvania 19104, USA

ABSTRACT: Homogenous eosinophilic intracytoplasmic inclusion bodies were found within the large reticular neurons of the brain stems of 57 captive woodchucks (*Marmota monax*). Light microscopy was consistent with a proteinaceous nature, while electron microscopy suggested a non-viral origin. The woodchucks with inclusions were older than the general population that was studied. It is hypothesized that the neuronal inclusions in the brain stem are indicative of nonspecific ageing changes.

Key words: *Marmota monax*, woodchuck, brain stem, neuronal inclusion bodies, nonspecific ageing changes, prevalence, captive study.

INTRODUCTION

The Penrose Research Laboratory (Philadelphia Zoological Garden, 34th St. and Girard Ave., Philadelphia, Pennsylvania 19104, USA) established a colony of woodchucks (*Marmota monax*) in 1960 to study disease patterns in relation to ageing and nutrition (Snyder, 1985). In this colony woodchucks trapped as young of the year in Pennsylvania and New Jersey are housed one or two per cage and allowed to complete a natural lifespan. Routine examination of the brains at necropsy revealed eosinophilic inclusion bodies in neuronal cytoplasm that resembled the classic Negri body associated with rabies (Negri, 1903). While Negri bodies are found mostly in the Purkinje cells of the cerebellum and in the cells of the horn of Ammon, they are found also in other nerve cells and within intercellular spaces; the inclusion bodies in woodchucks were found only within the brain stem. Herein we describe the histochemistry and light and electron microscopic properties of these inclusion bodies and discuss their possible etiology.

MATERIALS AND METHODS

The woodchucks (*Marmota monax*) under study were captured as young of the year (approximately 6-mo-old) in Pennsylvania and New Jersey, housed one or two per cage at the Penrose Laboratory (Philadelphia Zoological Garden, 34th St. and Girard Ave., Philadelphia,

Pennsylvania 19104, USA), and allowed to complete a natural life span (Snyder, 1985). Each animal received an individual identification number with matching metal ear tag and skin tattoo. Detailed records were kept of health status and nutrition until the animals died.

The necropsy protocols, clinical histories and histological preparations of 445 woodchucks which died between 1961 and 1987 were reviewed. These data are available at the Penrose Laboratory, Philadelphia Zoological Garden. All woodchucks from which brain sections were taken ($n = 309$) were considered. Spinal sections were not routinely collected; those that were preserved were surveyed. Statistical analyses of age and sex data were performed using Wilcoxon Ranked Sums.

Ten woodchucks were examined for rabies. Half of each brain was submitted unfixed to the Commonwealth of Pennsylvania Bureau of Animal Industry Laboratory (Harrisburg, Pennsylvania 17105, USA) for possible detection of rabies virus antibody by fluorescent antibody technique (FAT). The remaining portions of each brain and the brains from the remaining 299 woodchucks were fixed in 10% neutral buffered formalin and examined as follows.

For light microscopy, blocks of tissue fixed in buffered 10% formalin were embedded in paraffin, sectioned at 6 μ m, and stained with hematoxylin and eosin (H&E). When inclusions were present, selected slides were prepared using the following special staining techniques: Periodic Acid Schiff (PAS)—H&E, Perl's Iron, Schorr, Ziehl-Neelsen Acid Fast, Alcian Blue, Congo Red, Mallory's Trichrome, Luxol Blue—PAS—H&E, Oil-Red-O—H&E, Feulgen and Menzies' Nucleic Acid (Luna, 1968).

The brain of an aged (79 mo) woodchuck, scheduled for euthanasia because of debilita-

tion, was prepared for electron microscopic study of the inclusions. The animal was anesthetized with ether and perfused through the left ventricle with 4% glutaraldehyde in 440 mM phosphate buffer for 1 hr, then postfixed in 2% osmium tetroxide for 1 hr at 4 C. The brain was embedded in Araldite (Durcupan; Ciba Products Corporation, Fair Lawn, New Jersey 07410, USA) after dehydration in graded alcohols. Blocks were sectioned to 70 nm on a Sorvall MT-2B ultramicrotome (DuPont Company, Instrument Products, Biomedical Division, Newton, Connecticut 06470, USA). Thin sections from suitable blocks were placed on an uncoated grid and stained with lead citrate and uranyl acetate and examined on a Zeiss EM 9-S electron microscope (Carl Zeiss, Inc., One Zeiss Drive, Thornwood, New York 10594, USA).

RESULTS

In a survey of 309 woodchuck brains, 57 had homogenous eosinophilic intracytoplasmic inclusions in neurons in the mid-brain. The inclusions appeared throughout the length of the brain stem, and were located in perikarya lying on or immediately lateral to the midline, from the medulla to the diencephalon. They were ventrally located in relation to the central canal and aqueduct of Sylvius, and were ventrolateral to the third ventricle.

The animals possessing the lesions had all reached sexual maturity. Fourteen were under middle age (approximately 40 mo of age; Snyder, 1976), the rest were over middle age. The median age of the total population was 34 mo; the affected population was significantly older (median age was 62 mo, $P < 0.001$). The prevalence of inclusion bodies was greatest among the oldest animals (Table 1). There was no sex predilection ($P > 0.05$).

The brains of 10 woodchucks were examined for evidence of rabies virus antigen by FAT. Each brain was negative for rabies. Seven of these brains had neurons which contained intracytoplasmic inclusions.

Four animals with neuronal inclusion bodies showed neurological signs preceding death (head tilt, posterior paresis), but these could not be correlated with the presence of inclusions. Each of these animals

TABLE 1. Age-specific prevalence of intracytoplasmic neuronal inclusion bodies in brains of woodchucks from the Penrose Laboratory research colony.

| Age (months) | Affected % | Affected/total population |
|--------------|------------|---------------------------|
| 1-10 | 0 | 0/47 |
| 11-20 | 3 | 1/29 |
| 21-30 | 13 | 5/40 |
| 31-40 | 33 | 10/31 |
| 41-50 | 13 | 4/30 |
| 51-60 | 18 | 8/44 |
| 61-70 | 29 | 7/24 |
| 71-80 | 36 | 9/25 |
| 81-90 | 13 | 2/16 |
| 91-100 | 47 | 7/15 |
| 101-110 | 40 | 2/5 |
| 111-120 | 67 | 2/3 |
| Totals | 18 | 57/309 |

was rabies antibody negative by FAT. The causes of death of these four animals were chronic pyelonephritis ($n = 2$), bronchopneumonia ($n = 1$) and ruptured aorta ($n = 1$).

Seven animals were euthanized due to debilitation at old age (60, 65, 72, 79, 84, 96, and 115 mo). The causes of death of the other animals were medial necrosis and rupture of the aorta ($n = 6$), neoplasia ($n = 11$), systemic infection ($n = 8$), infection associated with chronic viral hepatitis ($n = 11$) or glomerulonephritis ($n = 14$). Viral hepatitis was caused by woodchuck hepatitis virus, one of the hepadna viruses (Summers et al., 1978).

The light microscopic appearance of the inclusion bodies is shown in Figure 1. Stained with hematoxylin and eosin, they appeared as eosinophilic (or homogenous hyaline) intracytoplasmic bodies of variable size and shape. Of the 57 brains affected, 48 had an inclusion body in most of the periaqueductal neurons; the remaining brains had only a few neurons with inclusion bodies. Most neurons contained one inclusion; some brains had neurons containing up to four intracytoplasmic inclusion bodies.

None of the 57 brains with neuronal inclusions showed evidence of encephalitis

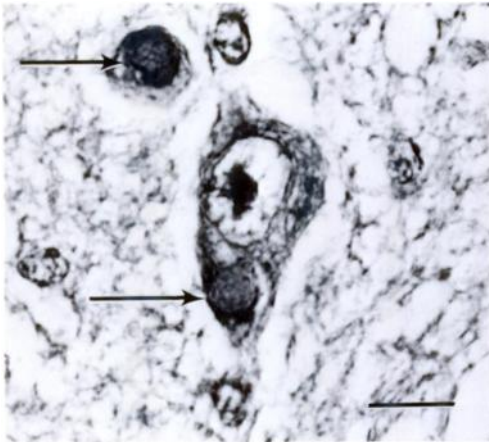


FIGURE 1. Eosinophilic intracytoplasmic inclusion bodies (arrows) in a 115-mo-old female woodchuck (*Marmota monax*). H&E. Bar = 20 μ m.

(perivascular lymphoplasmacytic cuffing, gliosis) or neoplasia. From one to several neurons containing yellow-brown cytoplasmic granules of lipofuscin were found in 22 brains which also contained neuronal inclusion bodies. None of the lipofuscin-containing neurons also contained the eosinophilic inclusion bodies.

The inclusions were 2.5 to 5.0 μ m and usually round in cross-section with definite curvilinear boundaries. Infrequently, the cross-sections were more oval and the boundaries were slightly indented.

The perikarya in which the inclusions were found showed no signs of degeneration. Inclusions were generally seen within large reticular cells of the brain stem.

Menzies, Schorr and Feulgen stains for nucleic acids were each negative. Oil-Red-O stain for neutral lipids was negative. Congo Red stain for amyloid was negative. Special stains for iron (Perl's), glycogen (PAS), and mucopolysaccharides (Alcian Blue) were each negative. Mallory's Trichrome stain for collagen was negative.

The intracytoplasmic inclusions were weakly positive with Acid Fast and Luxol Blue. The inclusions were acidophilic (pink with H&E) and compatible with protein.

Electron microscopy of the brain stem

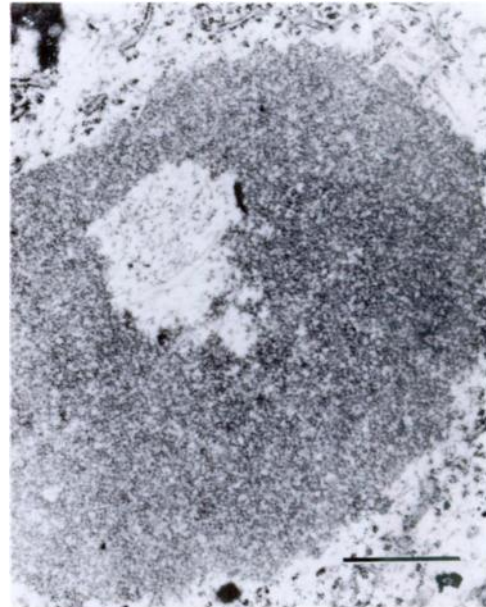


FIGURE 2. Electron micrographs of eosinophilic intracytoplasmic inclusions in a 115-mo-old female woodchuck (*Marmota monax*). Approximate magnification 15,700 \times . Bar = 1 μ m.

sections of the sacrificed woodchuck revealed the presence of inclusions. Again, they were found in the cytoplasm, were not enclosed by a limiting membrane, and appeared to have a homogenous, crystalline-like structure (Fig. 2). There is no evidence of viral structure or particles within the inclusions.

DISCUSSION

Woodchucks, commonly called groundhogs or marmots, are native to eastern North America (Nowak and Paradiso, 1983). About one-half of female woodchucks in natural populations reach sexual maturity at 11-mo-old; 100% of female woodchucks are sexually mature by 23 mo (Snyder and Christian, 1960). Male woodchucks are sexually mature at 22 mo (Snyder and Christian, 1960). In the wild, most woodchucks die before middle age (approximately 40 mo; Snyder, 1976). Kept in captivity, their longevity is 130–144 mo (Snyder, 1976).

Inclusions in neuronal cytoplasm have

been seen in aged human and mouse brains. In the course of routine human autopsies, Takei and Mirra (1971) found intracytoplasmic eosinophilic hyaline inclusions in neurons of the hypoglossal nuclei. Although the neurons exhibiting the inclusions were all functional and viable, they considered it to be a sign of nerve cell disintegration. The inclusions were described as an example of senile change in the brain, as there was a high prevalence of these inclusion bodies in the aged population they studied.

Similar inclusions were described in human autopsy material by Mendell and Markesbery (1971) as an incidental finding. The inclusions were most prevalent in the large multipolar neurons of the brain stem and spinal cord. They were proteinaceous, intracytoplasmic, hyaline, eosinophilic and had no apparent pathological or clinical effect on the cell. Electron microscopy revealed a limiting membrane of probable filamentous nature. They could find no consistent pattern relating to age, sex, underlying disease, cause of death or medications received.

Fraser (1969), while studying the brains of mice, found eosinophilic homogenous cytoplasmic oval to disc-shaped inclusions in the thalamus (dorsal and ventral thalamic nuclei). Staining showed evidence of protein in parallel fibrillar crystalline bundles with transverse and longitudinal striations. It was suggested (Fraser, 1969) that this represented the normal ageing process in cells since all of the mice were aged (>1-yr-old).

Lipofuscin, sometimes called the “wear and tear” pigment (Jubb et al., 1985), may represent pigments derived from the oxidation of tissue lipids or lipoproteins and may be considered a sign of senile atrophy (Jones and Hunt, 1983). It is sudanophilic, usually acid fast positive, and iron negative (Jones and Hunt, 1983). Under light microscopy, lipofuscin appears as finely granular yellow-brown cytoplasmic storage material (Jubb et al., 1985). Lipofuscin granules were observed in the cytoplasm

of several neurons in each of 22 brains with eosinophilic inclusion bodies, but no single neuron contained both eosinophilic inclusions and lipofuscin granules.

Leighton and Williams (1983) described prominent round to oval eosinophilic intracytoplasmic inclusion bodies in neurons in or adjacent to the pyramidal layer of the hippocampus in five nonrabid moose (*Alces alces*). Four of the animals showed abnormal behavior or clinical disease (chronic enteritis, severe keratoconjunctivitis). The inclusions were 2 to 20 μm in diameter and were homogenous masses of finely granular electron dense material.

Cameron and Conroy (1974) report finding ovoid to crescent-shaped 3 to 9 μm diameter eosinophilic intracytoplasmic inclusion bodies in Purkinje cells of the cerebellum and in neurons of the lateral geniculate body, pulvinar, the superior colliculi and the basal ganglia of a 6-yr-old cocker spaniel bitch with neoplastic reticulosis of the central nervous system. They suggested that the inclusions resulted from an aberrant formation of the rough endoplasmic reticulum.

Bestetti and Rossi (1980) described cytoplasmic lamellar bodies in brains of cattle, goat, sheep, dog, cat, rabbit, rat and mouse. The lamellar bodies are stacks of parallel unit membrane-bound cisternae of approximately regular spacing, filled with granular or homogenous electron dense material similar to what Cameron and Conroy (1974) described ultrastructurally. Bestetti and Rossi (1980) noted that it is unlikely that lamellar bodies would in fact represent the ultrastructural equivalent of cytoplasmic inclusions visible by light microscopy. There was no ultrastructural evidence of lamellar bodies in the woodchuck brain in this study.

Various kinds of pseudo-Negri bodies have been found in brains of normal dogs, foxes, and skunks (Tierkel, 1959). In clinically normal cats, two types of inclusion bodies have been found. Homogenous eosinophilic inclusions may occur in pyramidal cells of the hippocampus and thalamus.

Szlachta and Habel (1953) described inclusion bodies found in neurons of the dorsal part of the lateral geniculate body of normal cats. These inclusions were sharply defined, nonhomogenous, acidophilic, round or ovoid, 2 to 4 μm and occurred in the cytoplasm.

The majority of the woodchucks with neuronal inclusions were over middle age; it is hypothesized that the inclusions seen in the cytoplasm of the neurons in the brainstem are indicative of nonspecific ageing changes. Evidence from light and electron microscopic analysis of these lesions indicates that the inclusions are composed of proteinaceous material with no carbohydrates. There was no staining or electron microscopic evidence of a viral etiology.

ACKNOWLEDGMENTS

The authors gratefully acknowledge the assistance of Henry S. Schutta, Department of Neurology, University of Wisconsin Hospital, Madison, Wisconsin, in the electron microscopic studies. Thomas J. Van Winkle made several critical suggestions that improved the manuscript. We acknowledge the superb technical assistance of Jamie Hayden and thank Elizabeth Lacy for her contributions to this study.

LITERATURE CITED

- BESTETTI, G., AND G. L. ROSSI. 1980. The occurrence of cytoplasmic lamellar bodies in normal and pathologic conditions. *Acta Neuropathologica* 49: 75-78.
- CAMERON, A. M., AND J. D. CONROY. 1974. Rabies-like neuronal inclusions associated with a neoplastic reticulosis in a dog. *Veterinary Pathology* 11: 29-37.
- FRASER, H. 1969. Eosinophilic bodies in some neurons in the thalamus of ageing mice. *Journal of Pathology* 98: 201-204.
- JONES, T. C., AND R. D. HUNT (editors). 1983. *Veterinary pathology*, 5th ed. Lea and Febiger, Philadelphia, Pennsylvania, 1792 pp.
- JUBB, K. V. F., P. C. KENNEDY, AND N. PALMER (editors). 1985. *Pathology of domestic animals*, Vol. 1. Academic Press, Inc., New York, New York, 574 pp.
- LEIGHTON, F. A., AND E. S. WILLIAMS. 1983. Intracytoplasmic neuronal inclusions in the hippocampus of non-rabid moose (*Alces alces* (L.)). *Journal of Wildlife Diseases* 19: 285-288.
- LUNA, L. G. (editor). 1968. *Manual of histologic staining methods of the Armed Forces Institute of Pathology*, 3rd ed. American Registry of Pathology, McGraw Hill Book Co., New York, New York, 258 pp.
- MENDEL, J. R., AND W. R. MARKESBERY. 1971. Neuronal intracytoplasmic hyaline inclusions. *Journal of Neuropathology and Experimental Neurology* 30: 233-239.
- NEGRI, A. 1903. Beitrag zum Studium der Aetiologie der Tollwuth. *Zeitschrift für Hygiene Infektionskrankheiten* 43: 507-528.
- NOWAK, R. M., AND J. L. PARADISO (editors). 1983. *Walker's mammals of the world*, 4th ed., Vol. I. The Johns Hopkins University Press, Baltimore, Maryland, 568 pp.
- SNYDER, R. L. 1976. *Biology of population growth*. Croom-Helm, London, England, 227 pp.
- . 1985. The laboratory woodchuck. *Lab Animal* 14: 20-32.
- , AND J. J. CHRISTIAN. 1960. Reproductive cycle and litter size of woodchuck. *Ecology* 41: 785-790.
- SUMMERS, J., M. SMOLEC, AND R. L. SNYDER. 1978. A virus similar to human hepatitis B virus associated with hepatitis and hepatoma in woodchucks. *Proceedings of the National Academy of Sciences USA* 75: 4533-4537.
- SZLACHTA, H. L., AND R. E. HABEL. 1953. Inclusions resembling Negri bodies in the brains of nonrabid cats. *Cornell Veterinary* 43: 207-212.
- TAKEI, Y., AND S. S. MIRRA. 1971. Intracytoplasmic hyaline inclusion bodies in the nerve cells of the hypoglossal nucleus in human autopsy material. *Acta Neuropathologica* 17: 14-23.
- TIERKEL, E. S. 1959. Rabies. *Advances in Veterinary Science* 5: 183-226.

Received for publication 17 May 1989.